

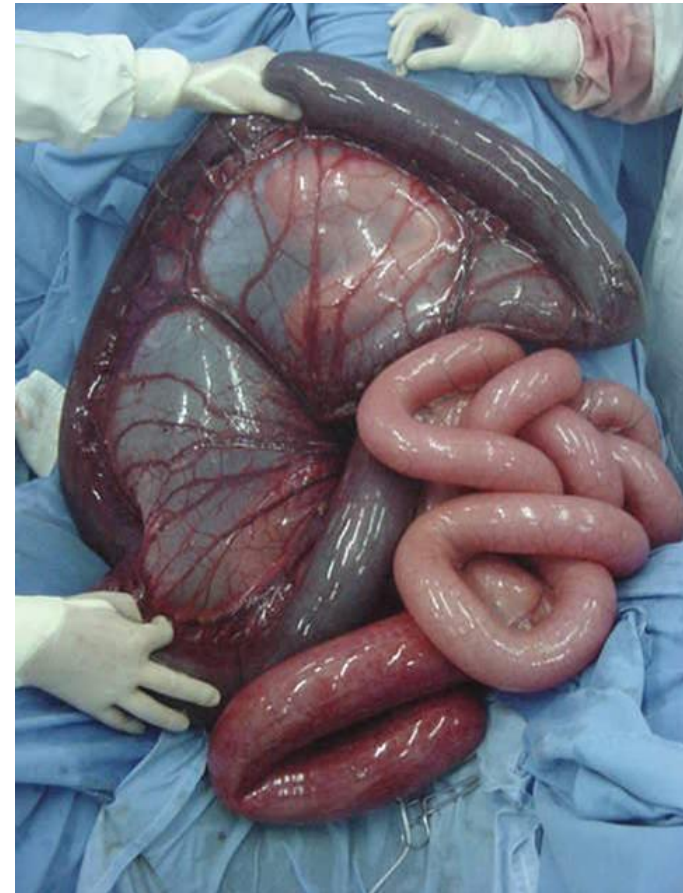
TÉCNICA CIRÚRGICA CELIOTOMIA E DIGESTÓRIO DE GRANDES ANIMAIS

LUIS CLAUDIO LOPES CORREIA DA SILVA

VCI 421

Técnica cirúrgica do abdômen e ap. digestório de equinos

- **Celiotomia/Laparotomia (acesso/explorat.)**
- **Enterotomia**
- **Enterectomia**
- **Desvios (*bypass*)**

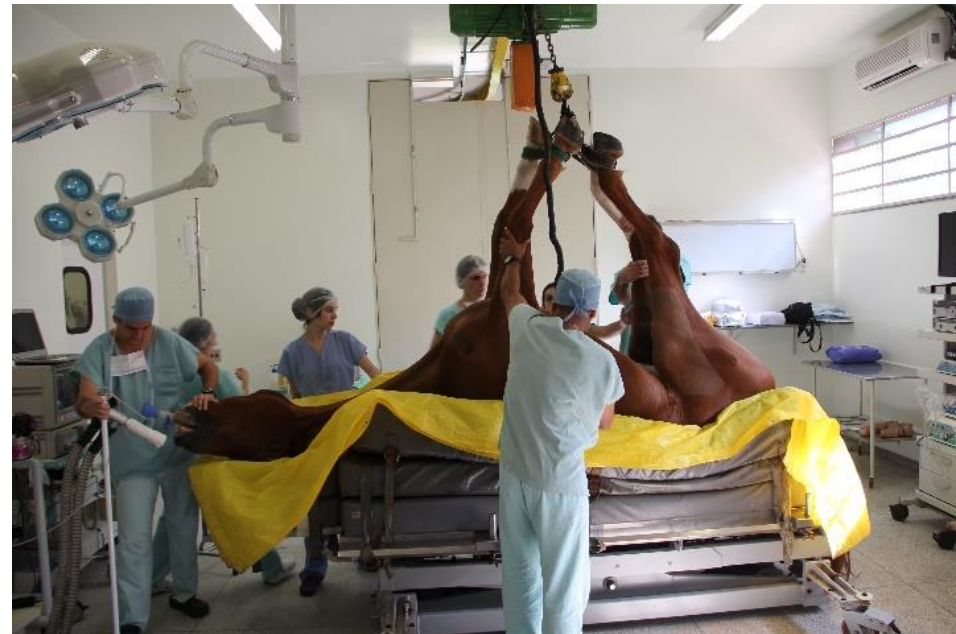


Acesso à Cavidade Abdominal

“Laparotomia (*laparon = flanko + tome = corte + ia*) significa, na acepção exata do termo, "secção do flanko"; tem, entretanto, o significado de "abertura cirúrgica da cavidade abdominal" no conceito da maioria dos cirurgiões. Celiotomia (*celio = abdome + tome = corte + ia*) seria outro termo, pouco usado nos dias de hoje, e significa precisamente incisão da parede abdominal em qualquer região. Desta forma, podemos considerar sinônimos os termos laparotomia e celiotomia”.

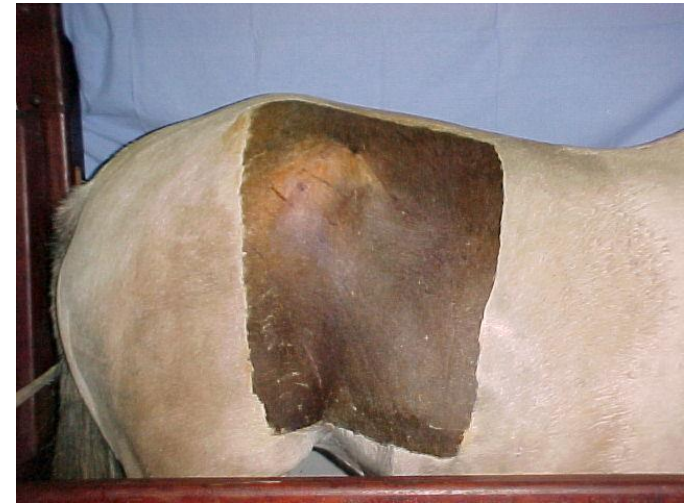CELIOTOMIA

- **Indicações:**
 - origem digestório ou ã
 - deslocamentos, obstruções e isquemias intestinais
- **Posicionamento do animal:**
 - em posição quadrupedal (estação)
 - em decúbito

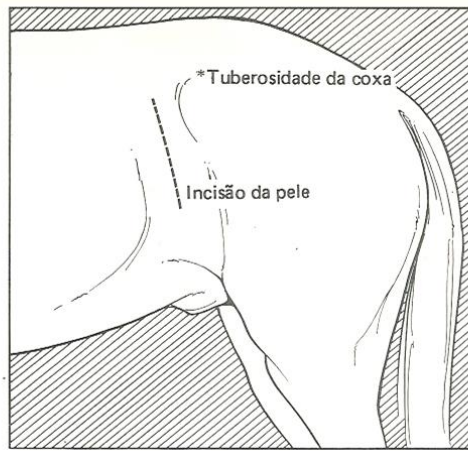


Celiotomia pelo flanco (laparotomia)

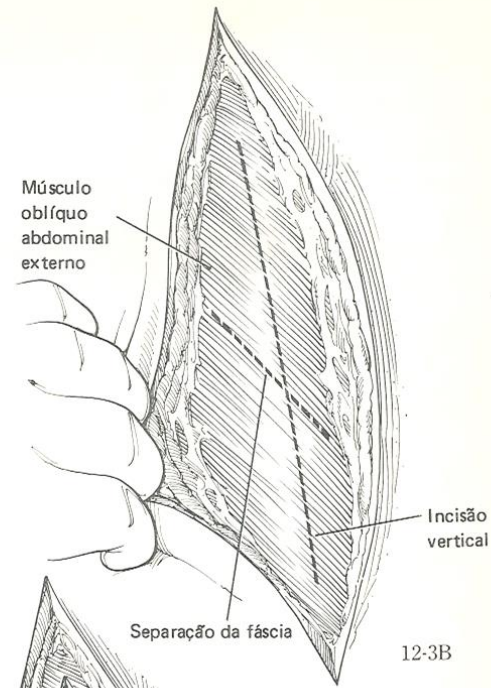
- **Indicações** - acesso a:
 - Cólon menor
 - Intestino delgado
 - Espaço nefroesplênico
 - Útero e ovário



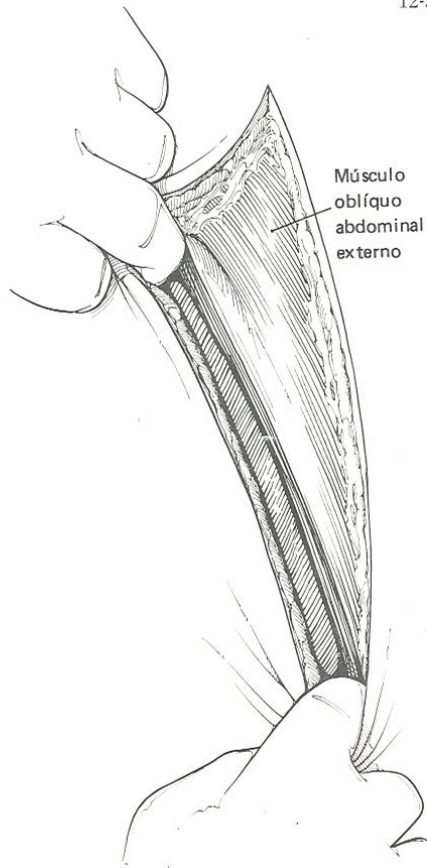Obs: sempre CASOS SELETOS, de
DIAGNÓSTICO CONFIRMADO, devido às
limitações de exploração, manipulação e
exposição de vísceras.



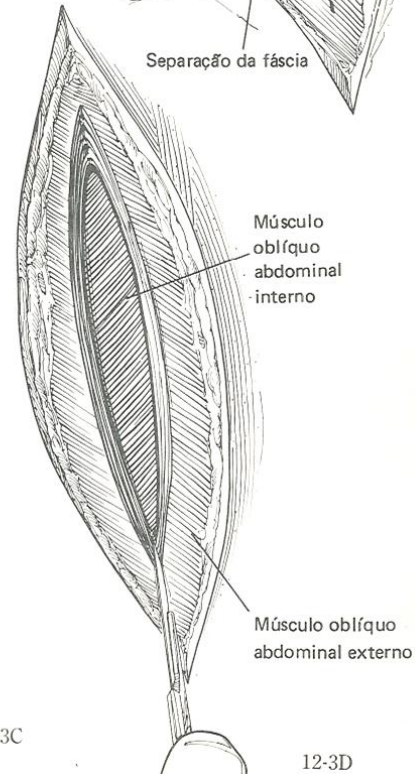
12-3A



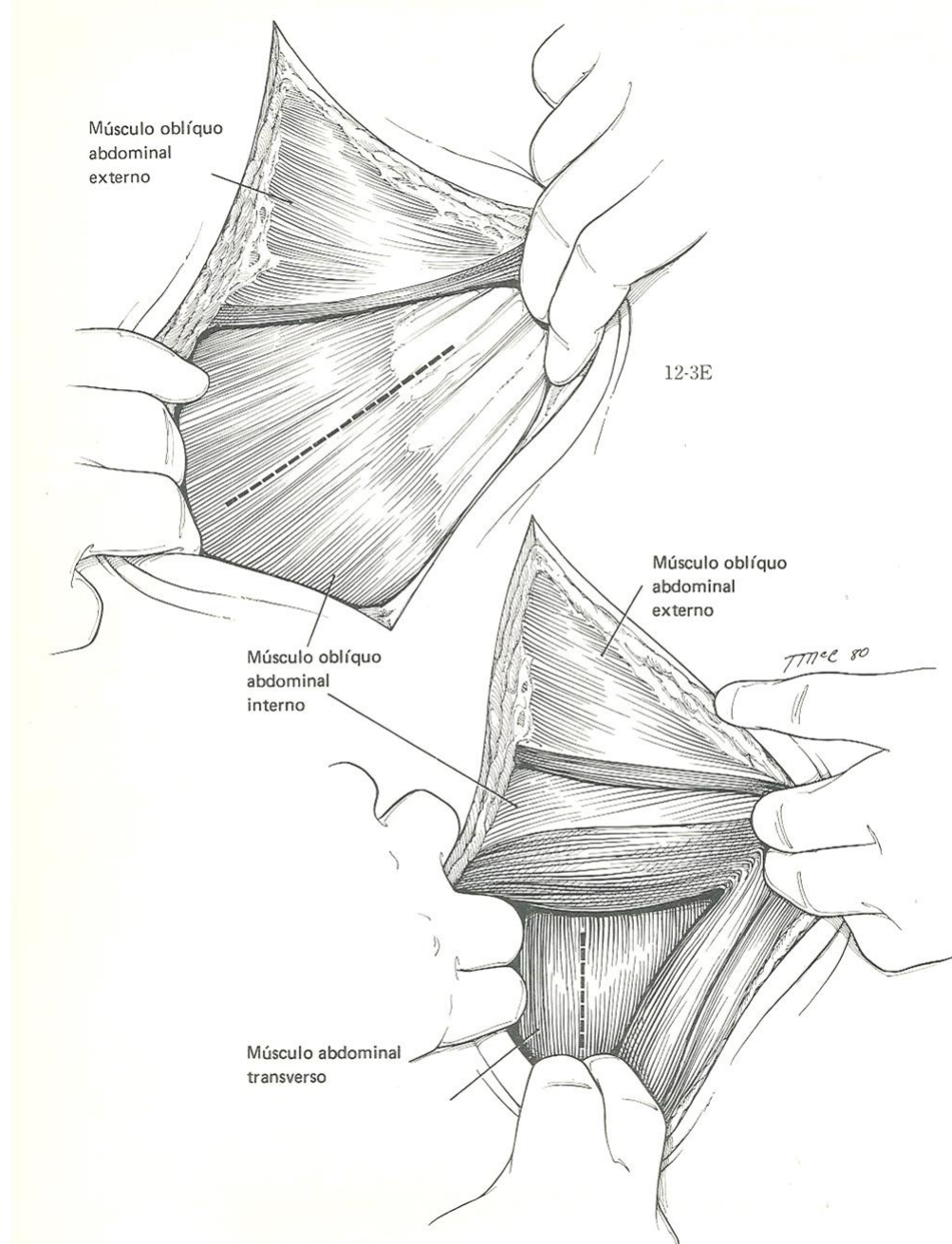
12-3B

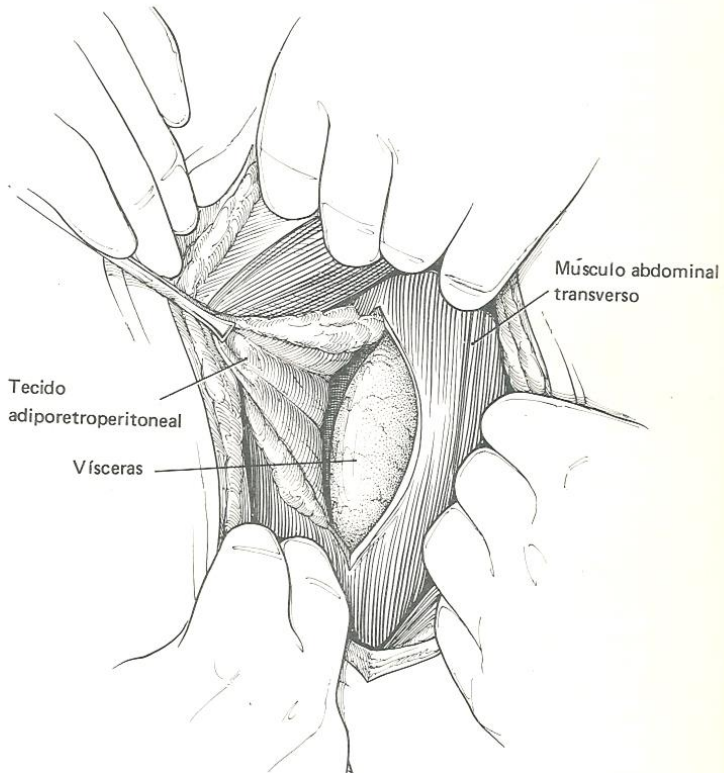
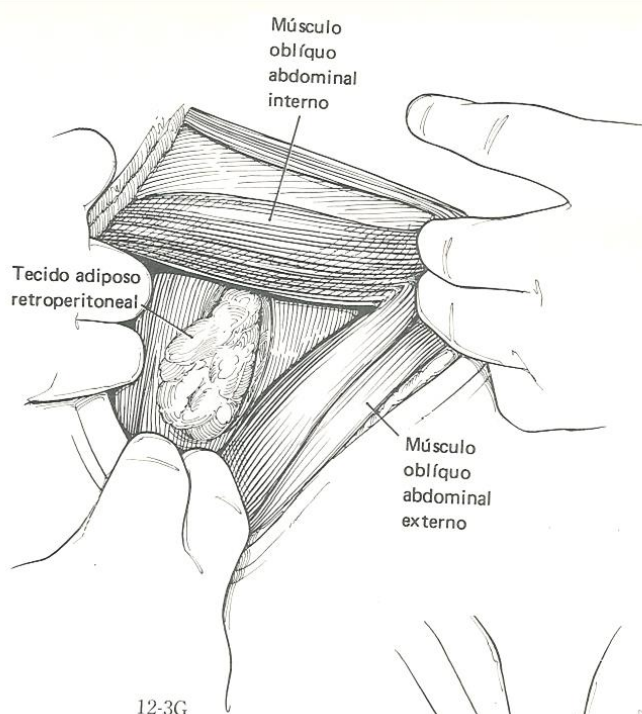


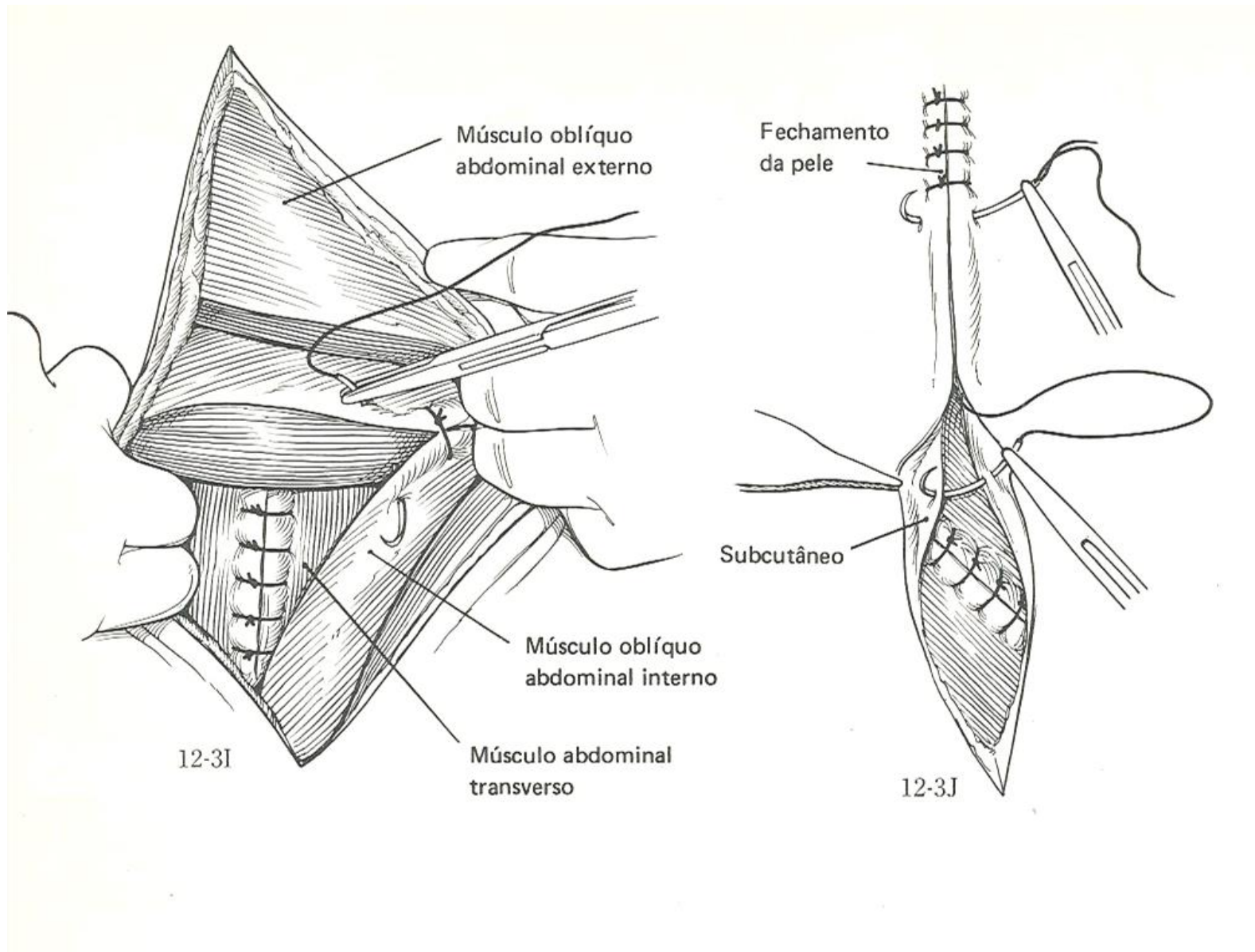
12-3C



12-3D

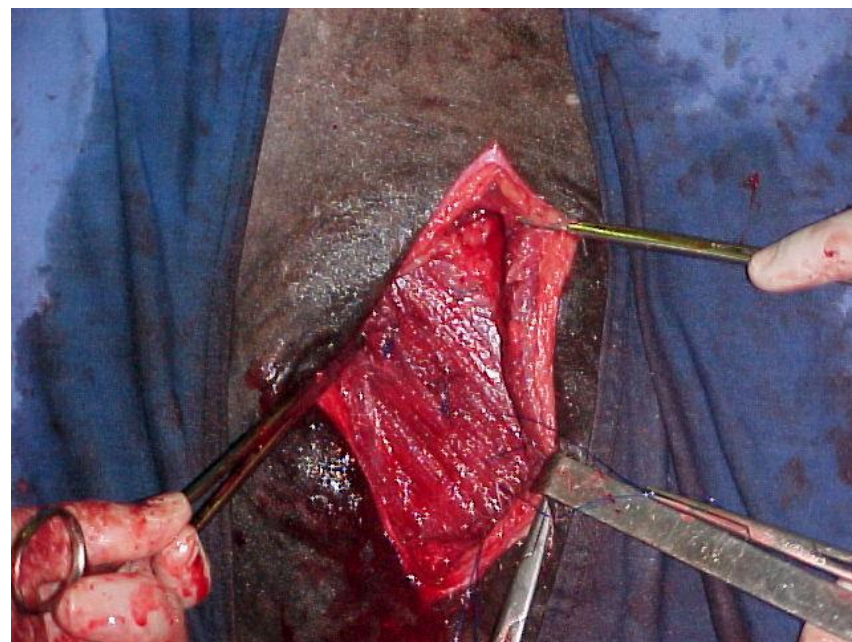
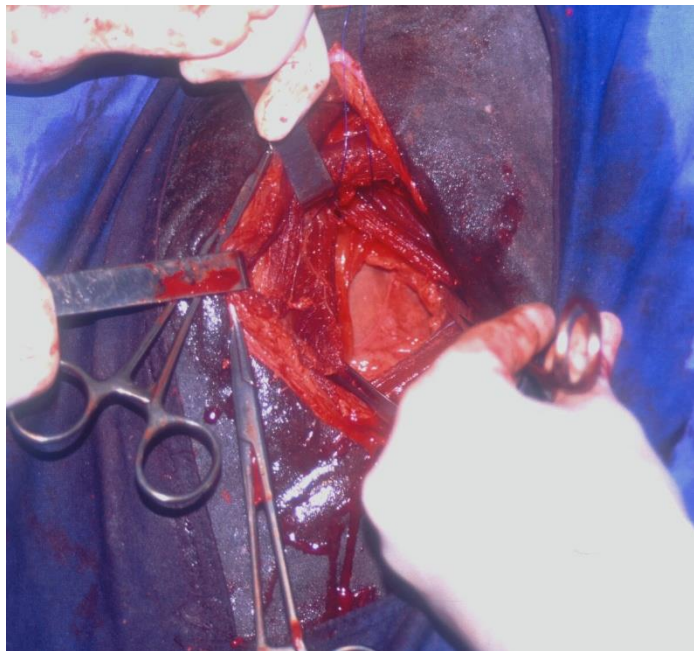




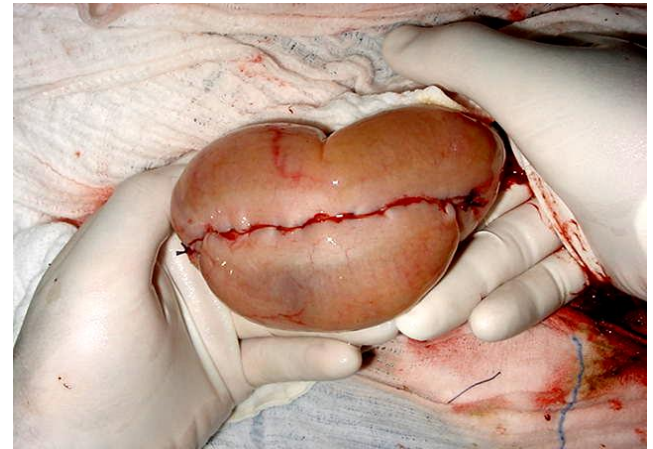
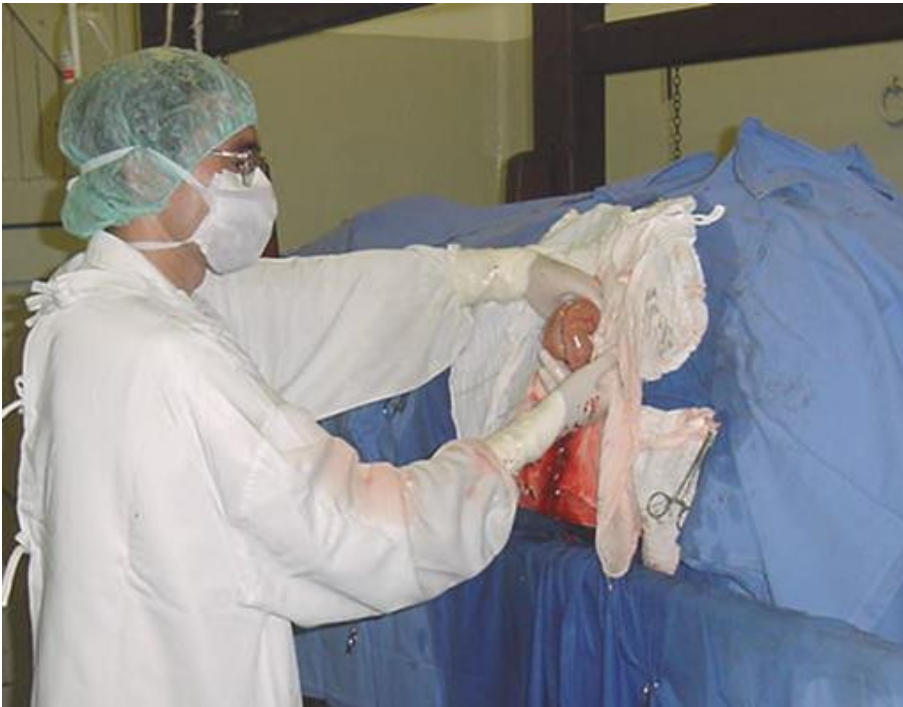
Turner & McIlwraith, Técnica Cirúrgica em Animais de Grande Porte

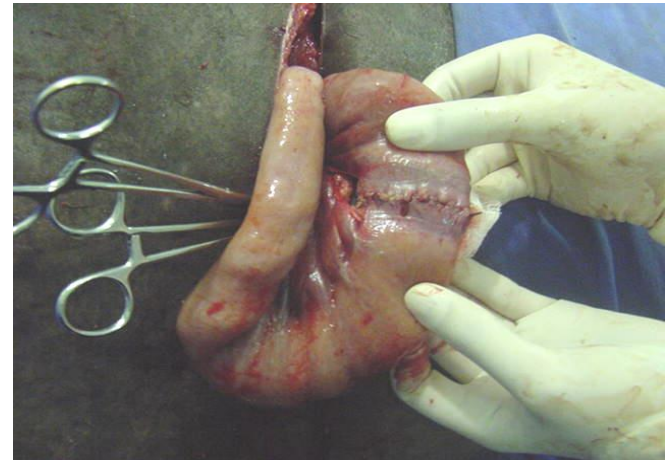
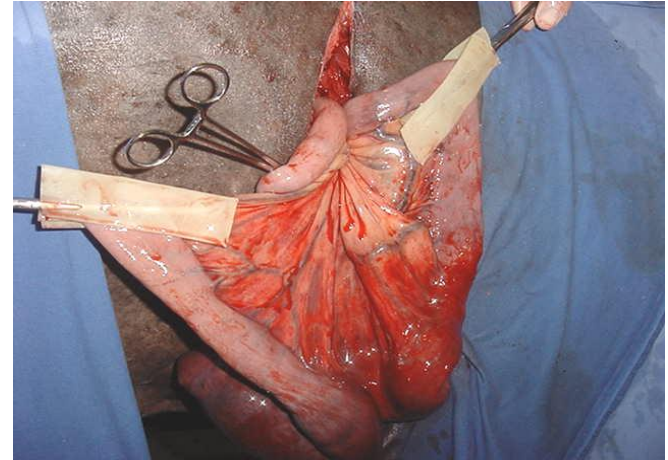
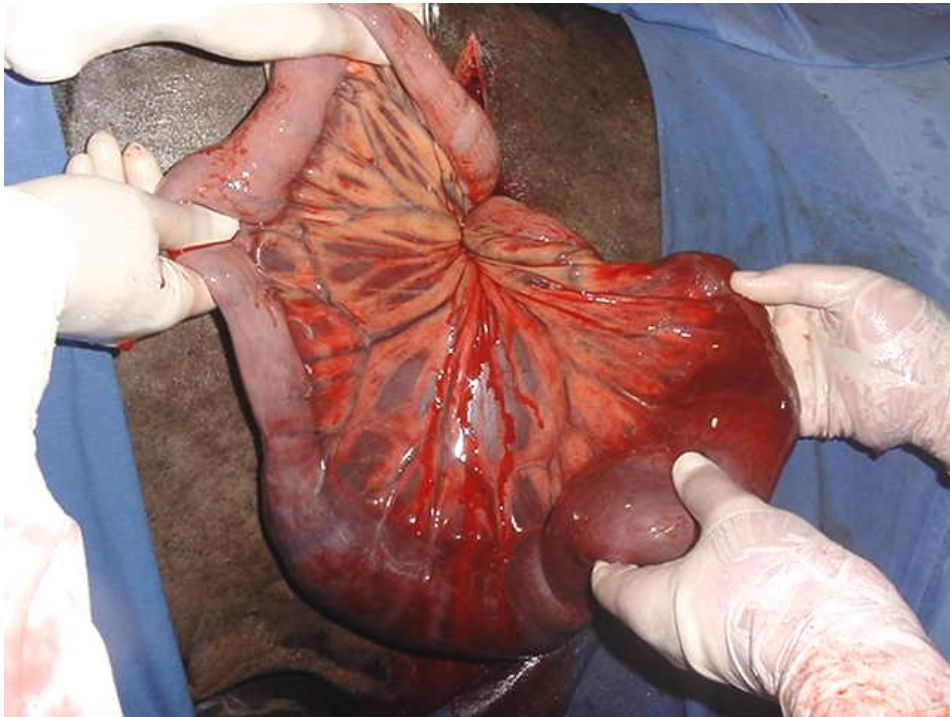
Laparotomia - técnica



Obstrução em cólon menor

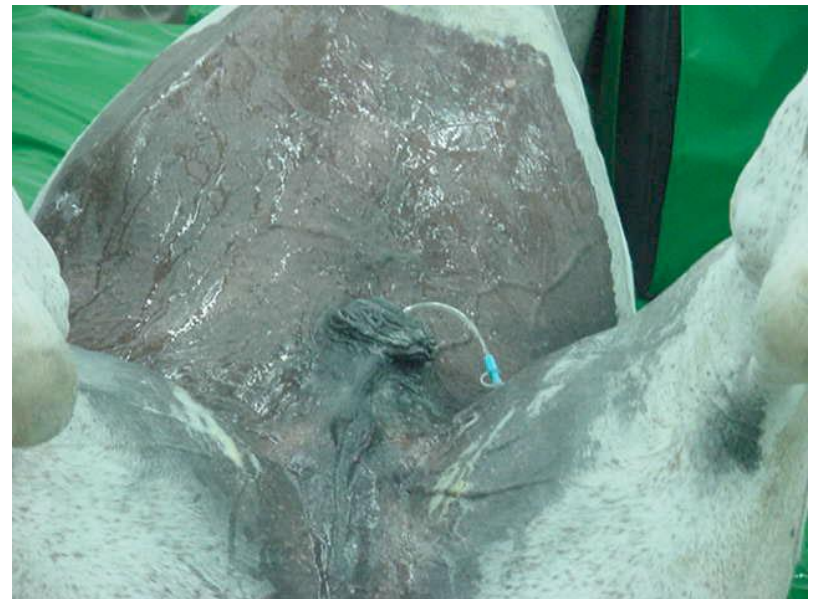


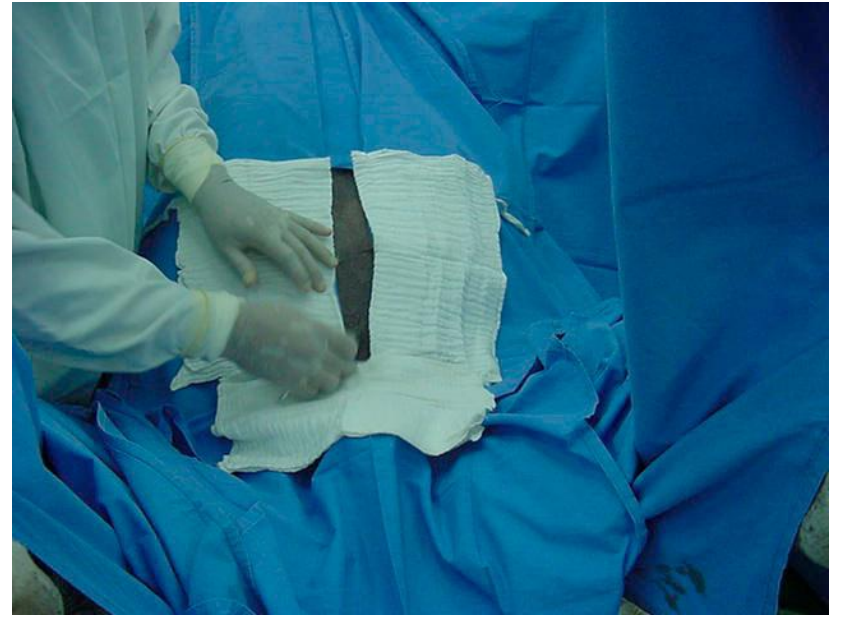
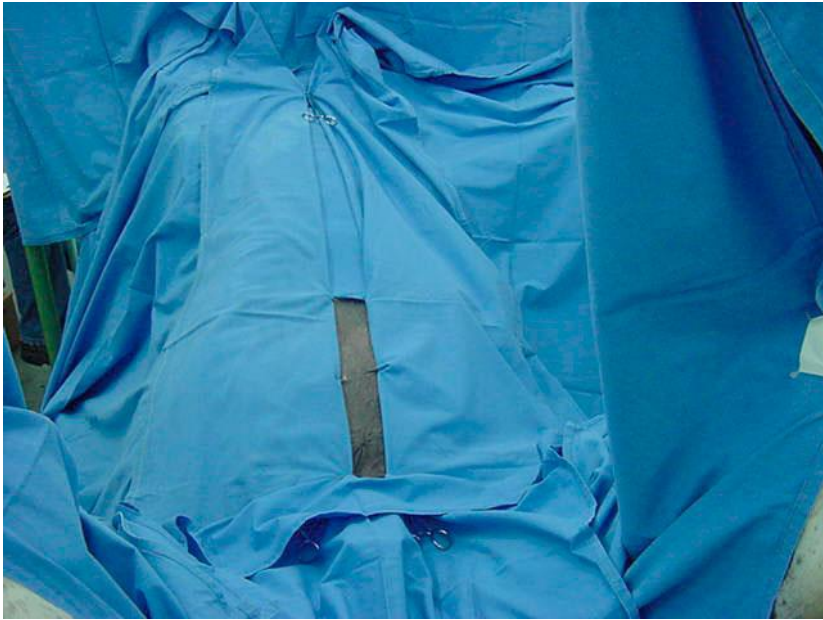
Hérnia IE delgado - enterectomia



CELIOTOMIA - decúbito dorsal

- Indicações: acesso a todos segmentos do TGI
- Limitações: estômago, duodeno, íleo, base do ceco, cólon transverso e reto.





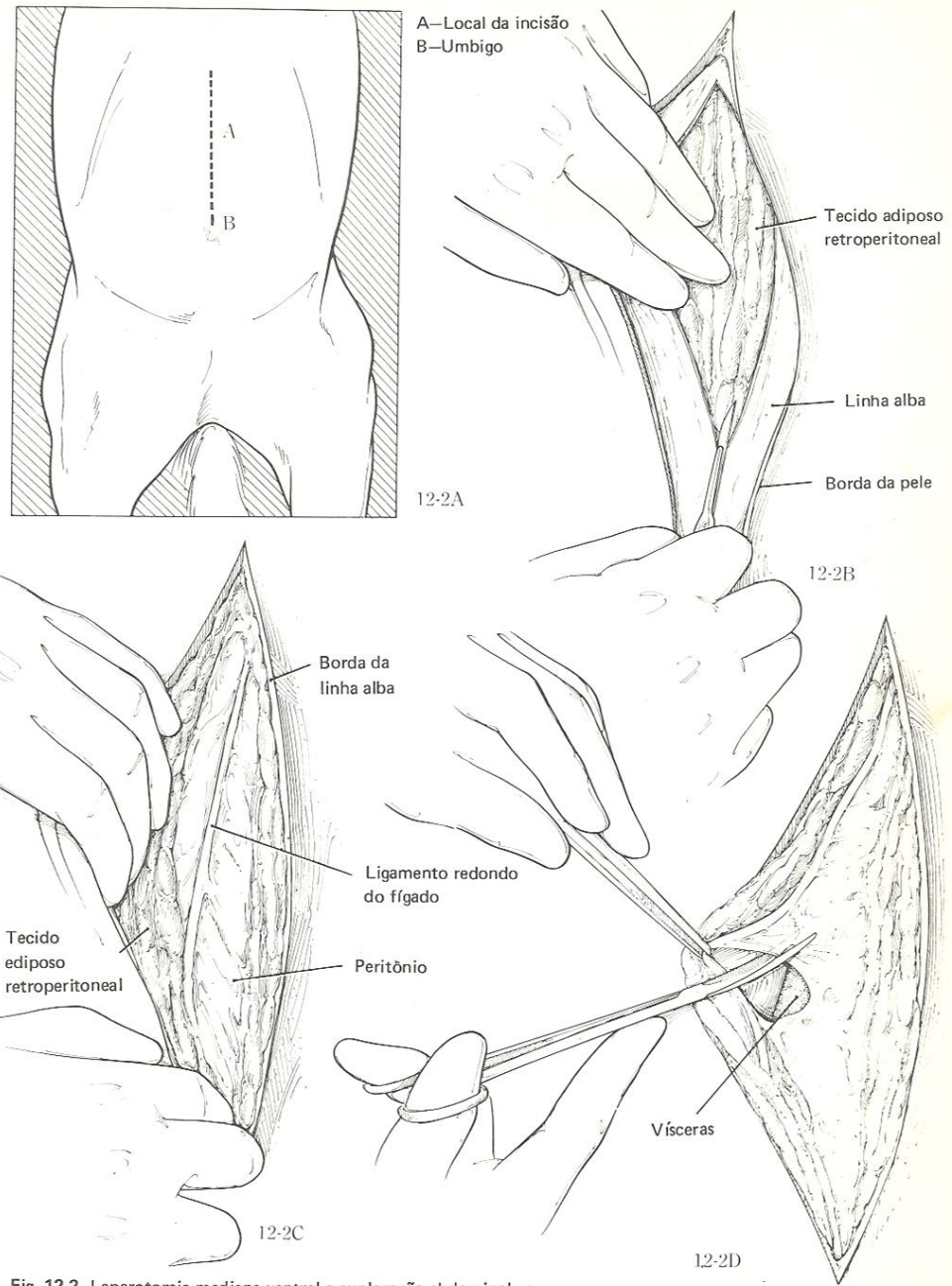
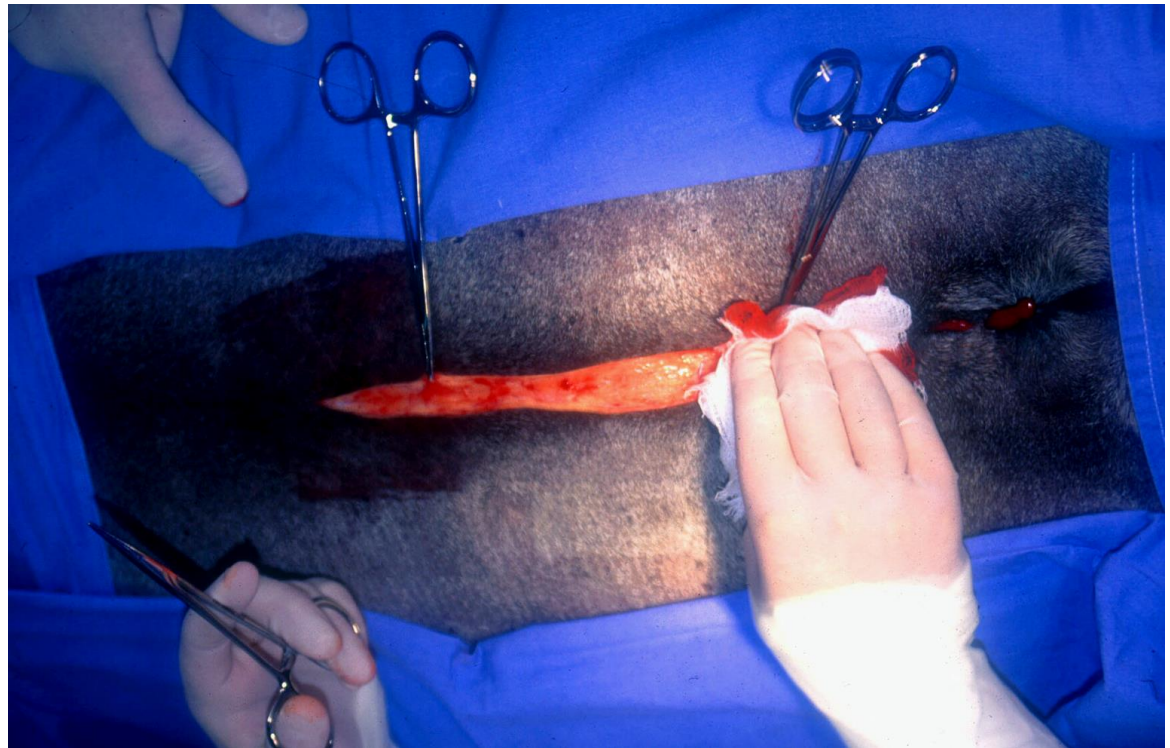
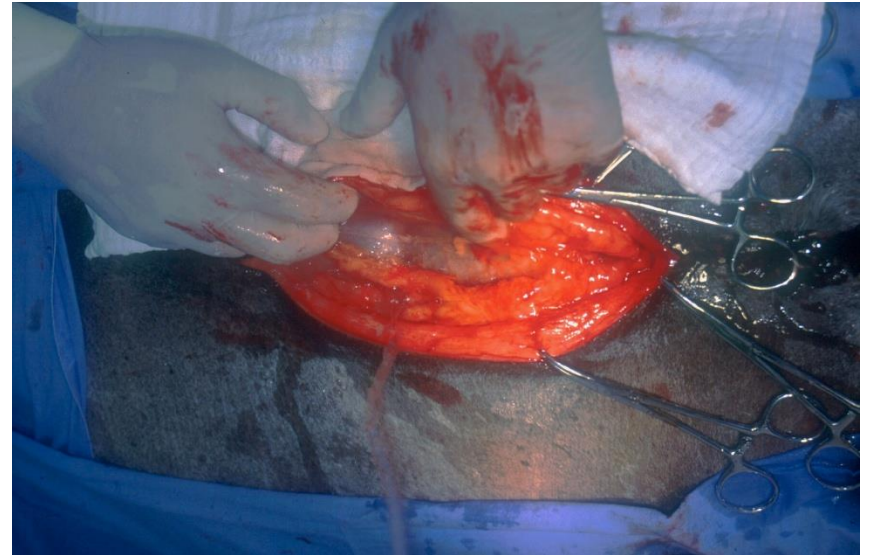
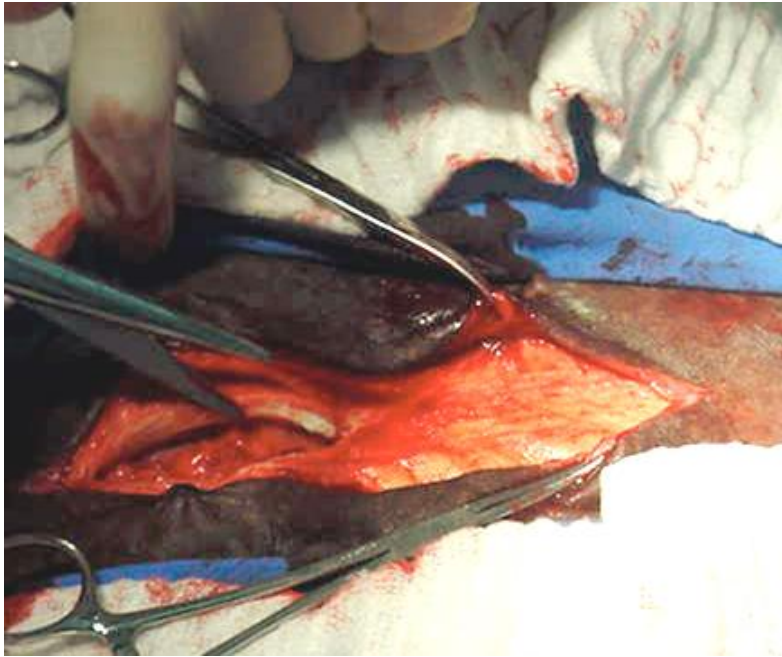


Fig. 12-2. Laparotomia mediana ventral e exploração abdominal.

- Planos anatômicos:
 - incisão de pele (20cm ou mais);
 - Pré-retro-umbilical

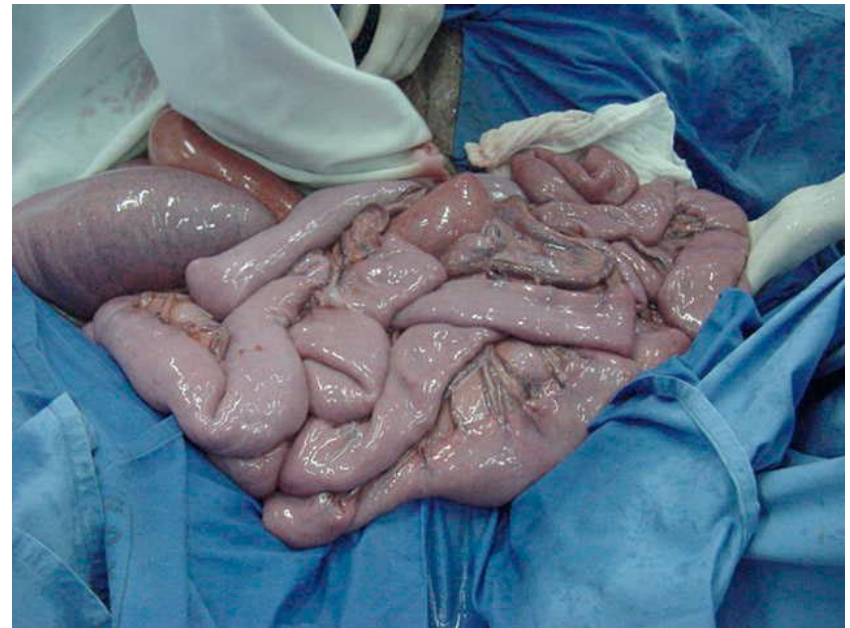

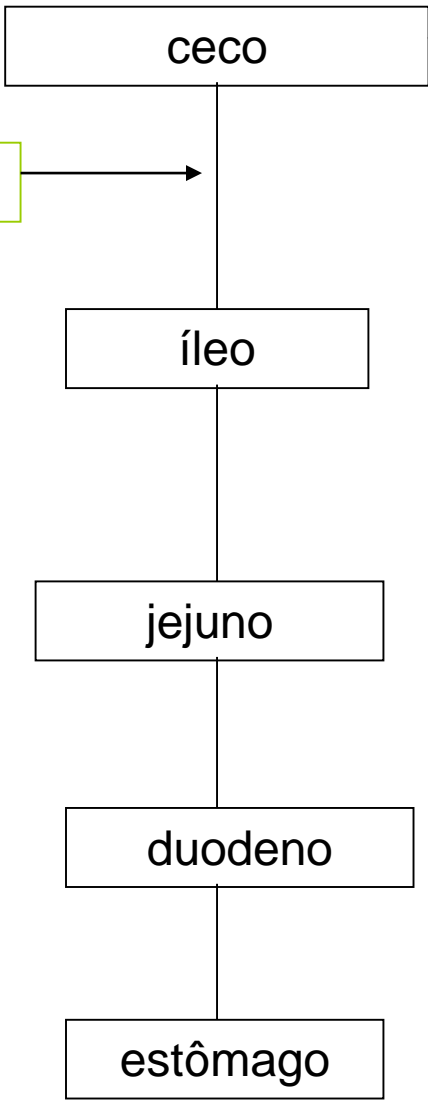
- Planos anatômicos:
 - incisão da musculatura / linha alba;
 - abertura do peritônio;



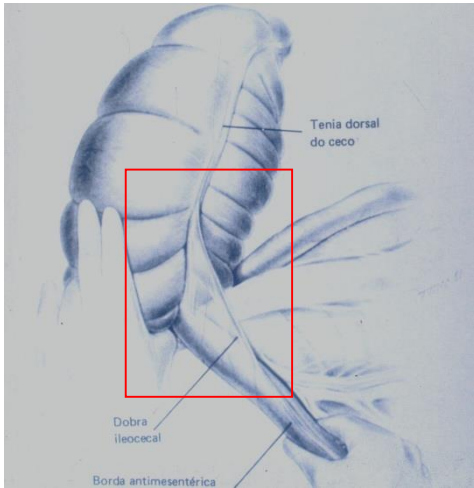
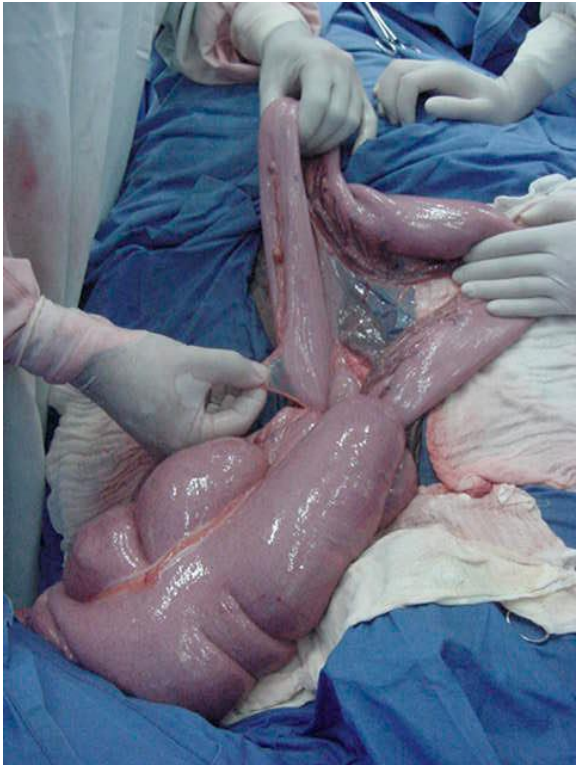
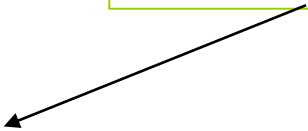
Laparotomia: exploração

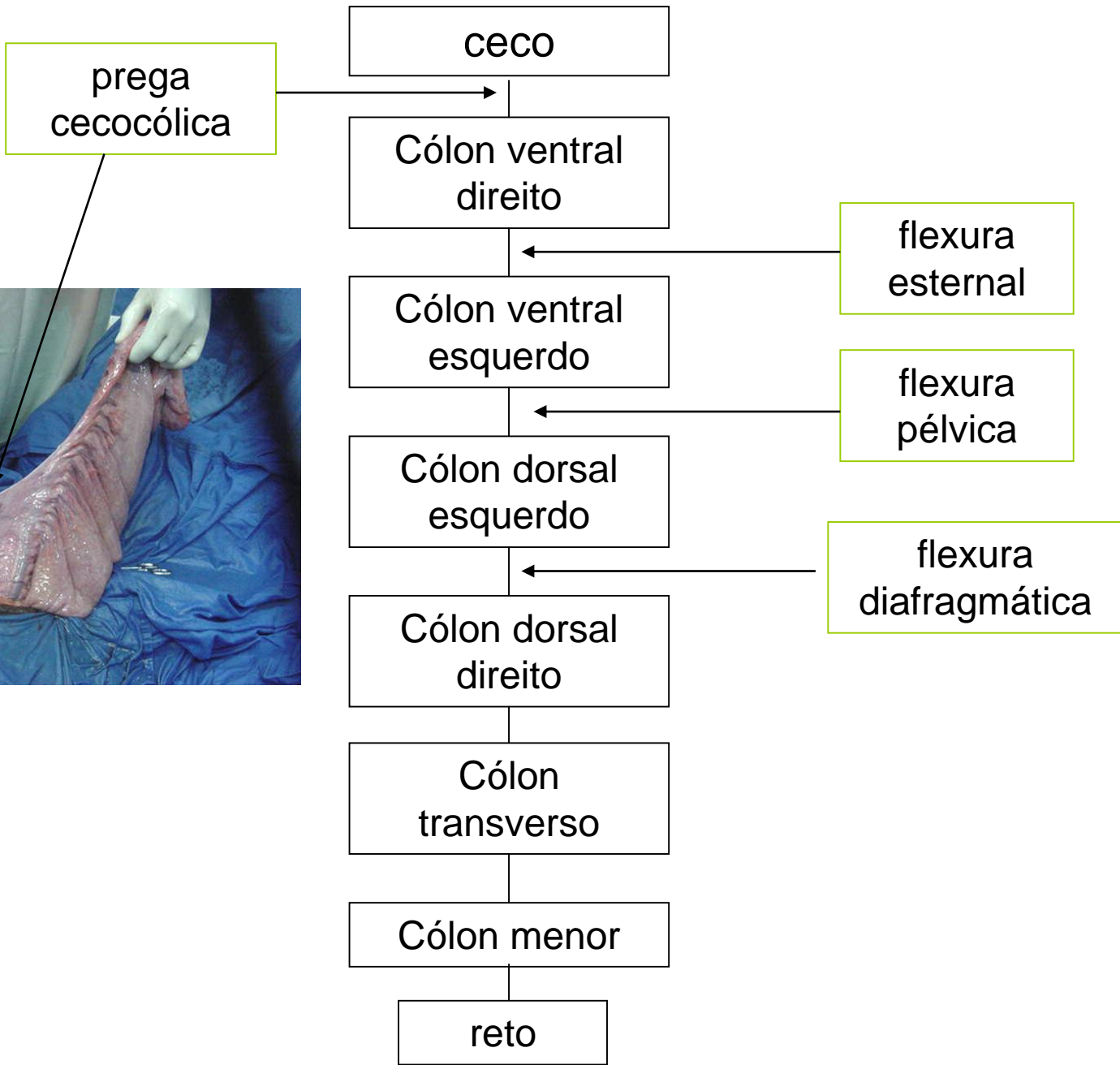
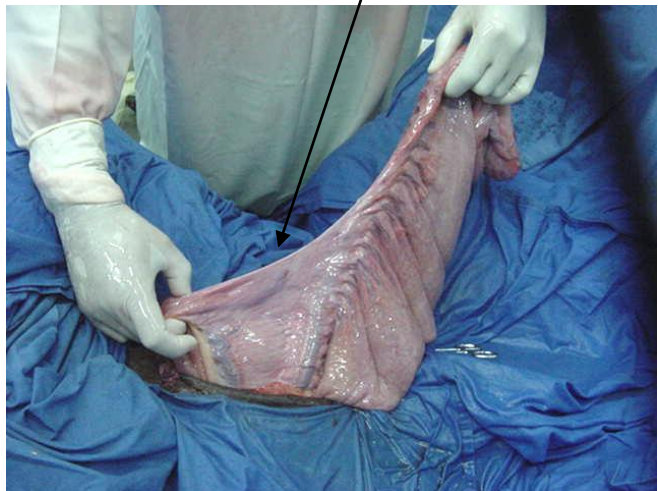- Exteriorização:
 - ceco
 - intestino delgado
 - cólon maior
 - cólon menor



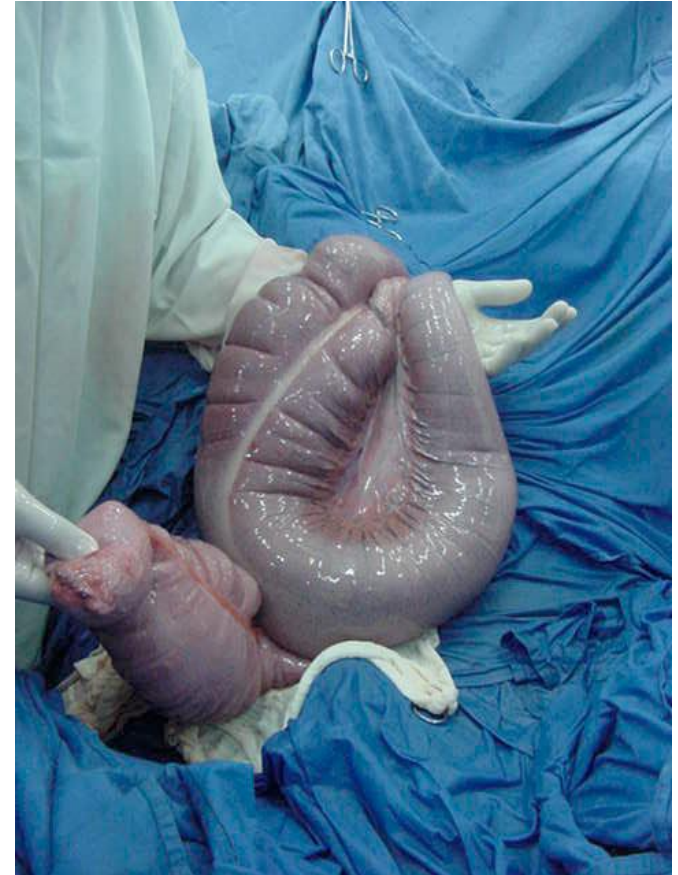
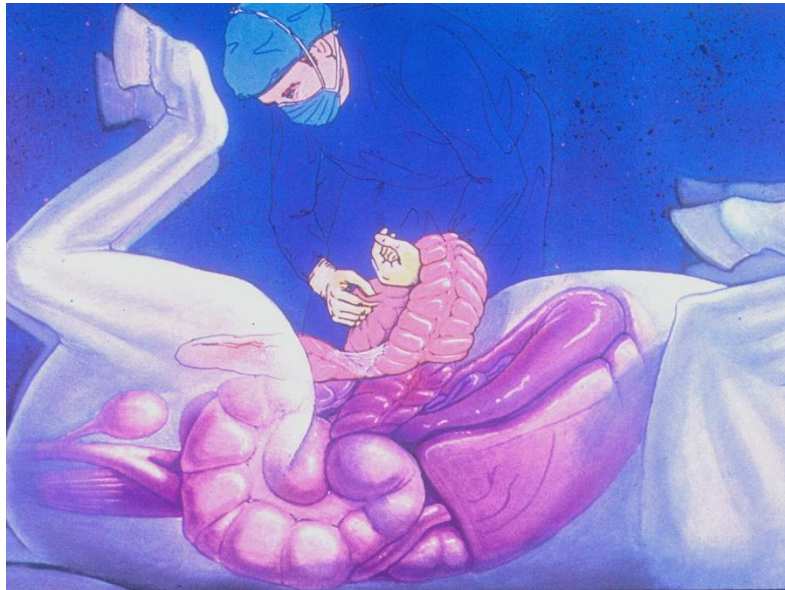
prega íleocecal



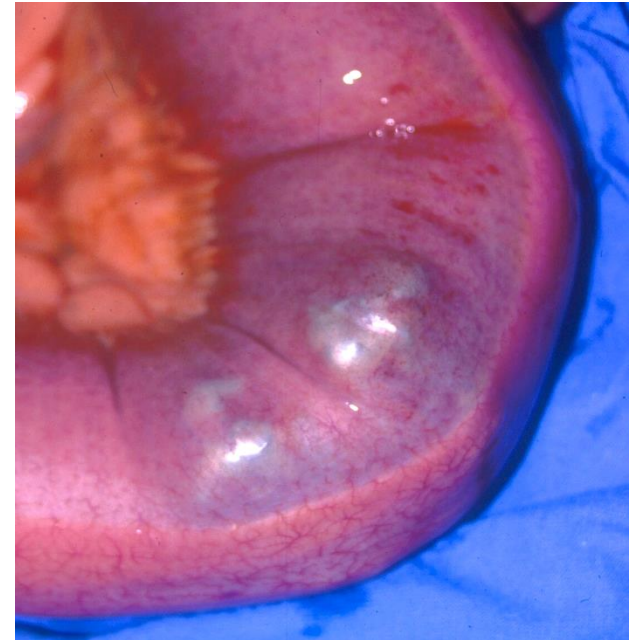
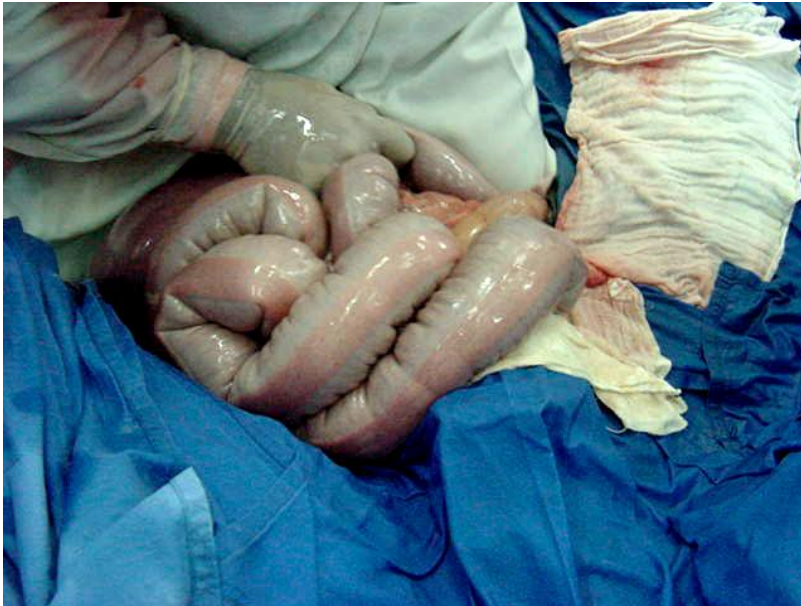
Celiotomia: exposição do cólon



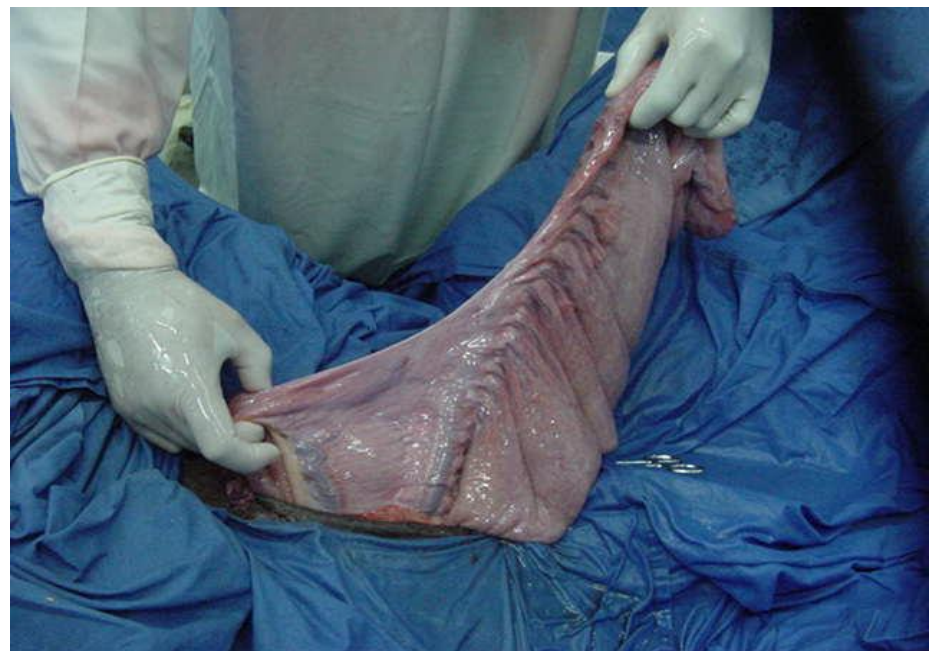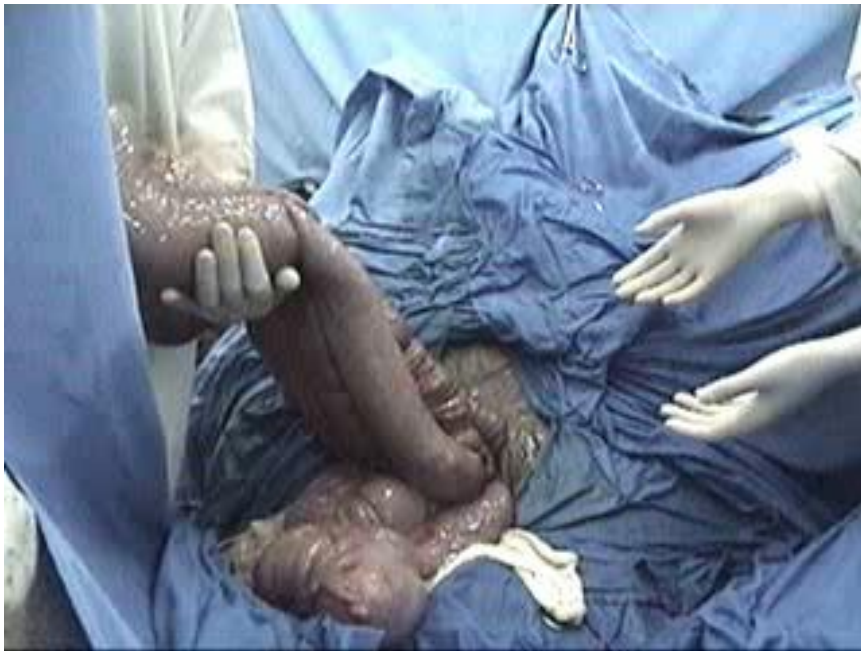Celiotomia: técnica

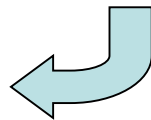
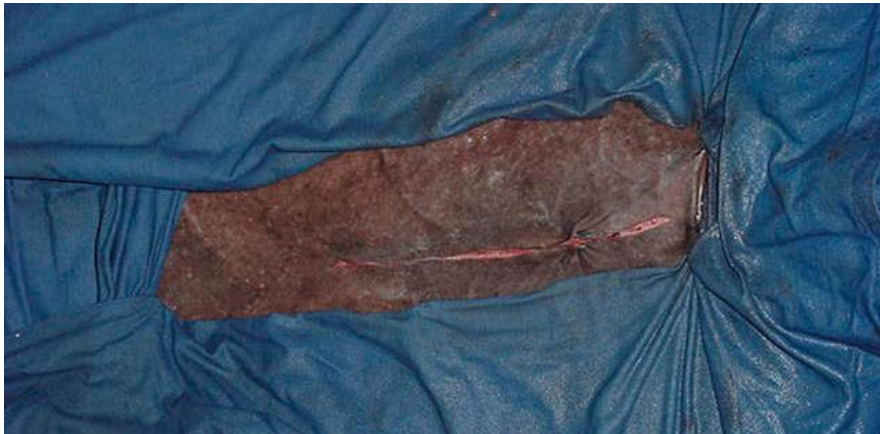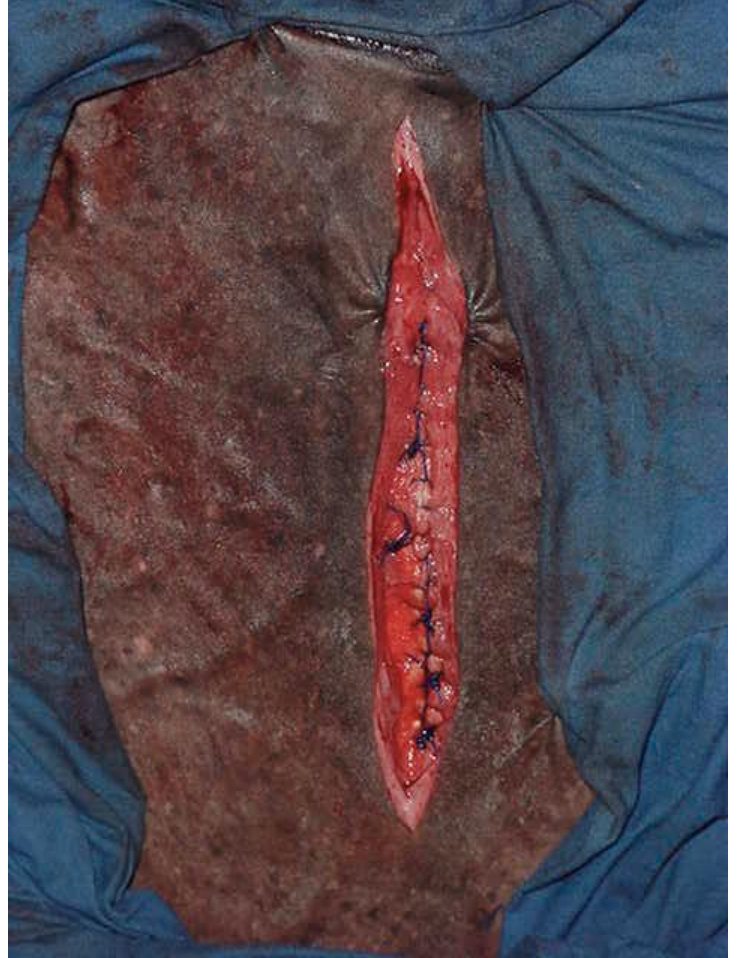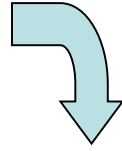
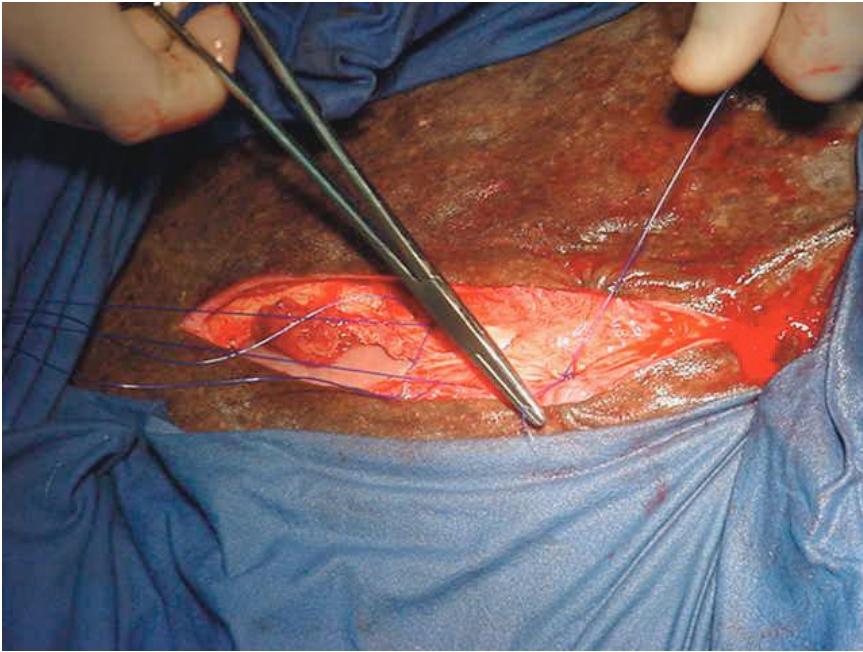
- Exteriorização:
 - cólon menor.

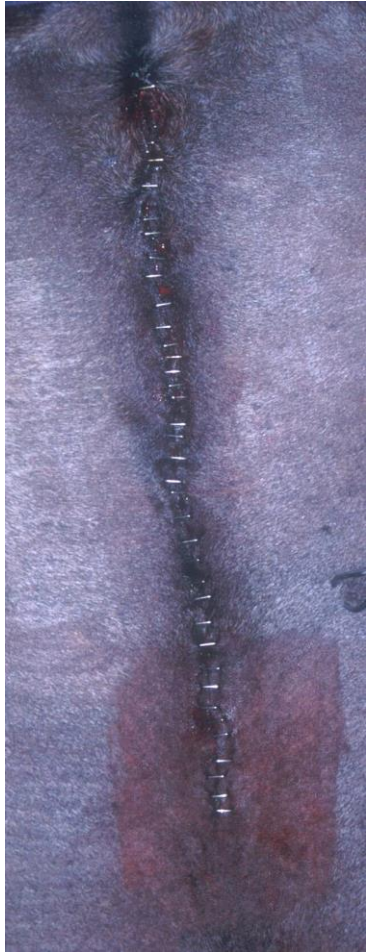
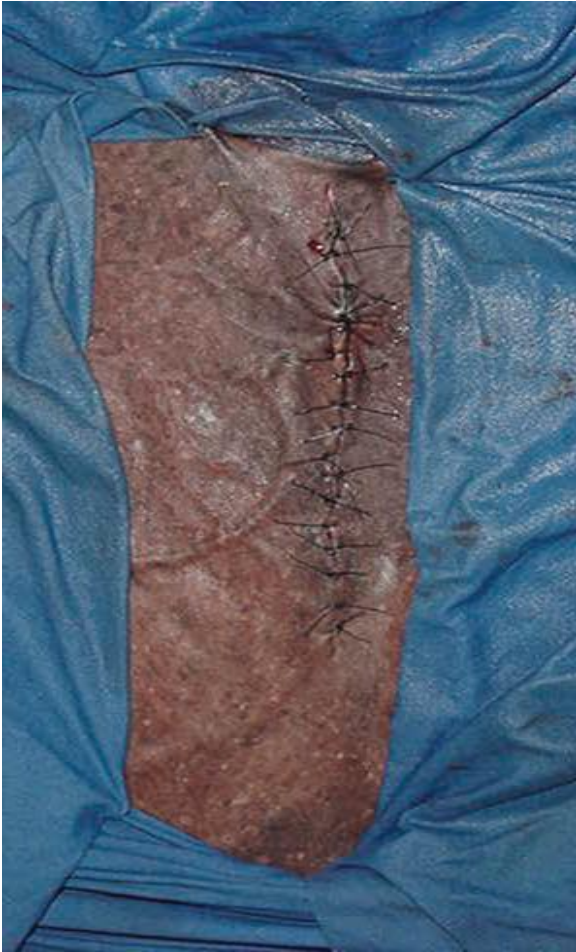
Celiotomia: técnica

- Reposição das alças intestinais na cavidade





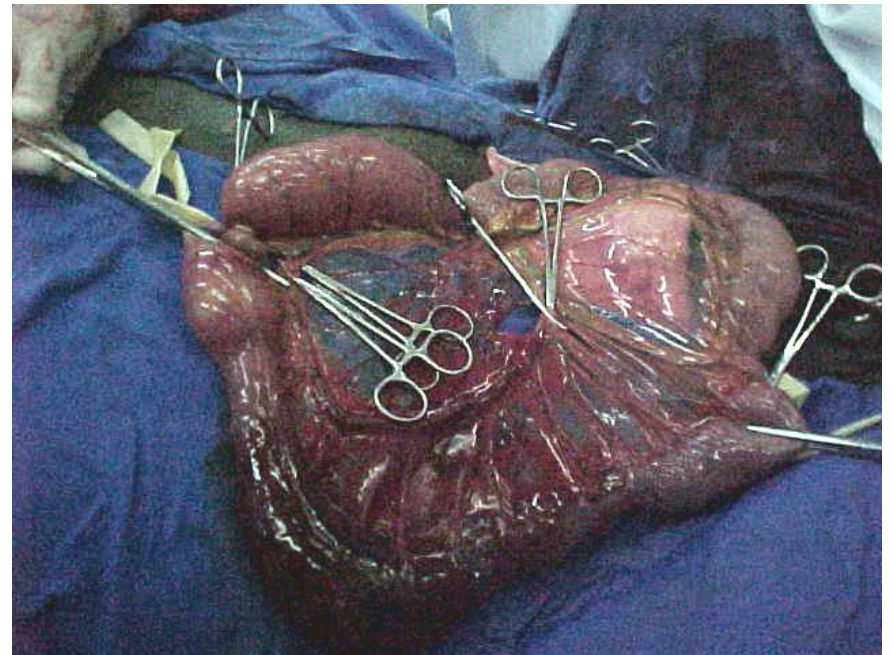
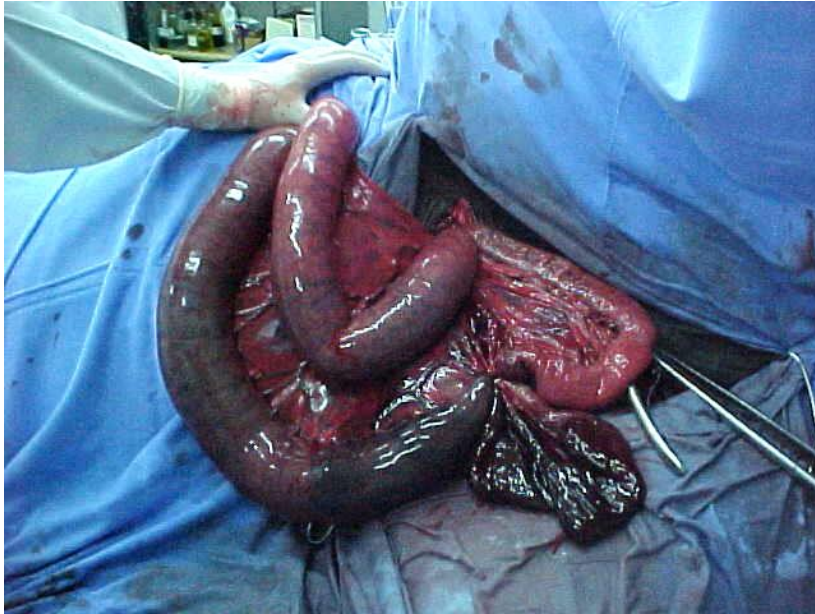


Celiotomia

- **CUIDADOS IMPORTANTES**
 - Manter as alças intestinais sempre úmidas e limpas
 - Ter duas equipes cirúrgicas – laparotomia / enterotomia, enterect.
 - Lavagem intensiva das alças antes de colocá-las na cavidade
 - Posicionamento correto das alças na cavidade

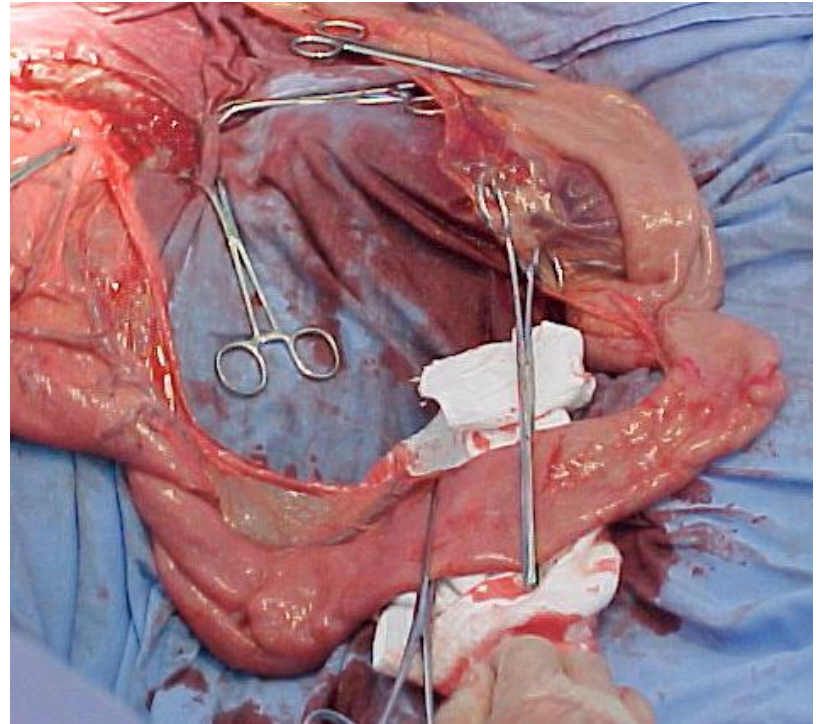
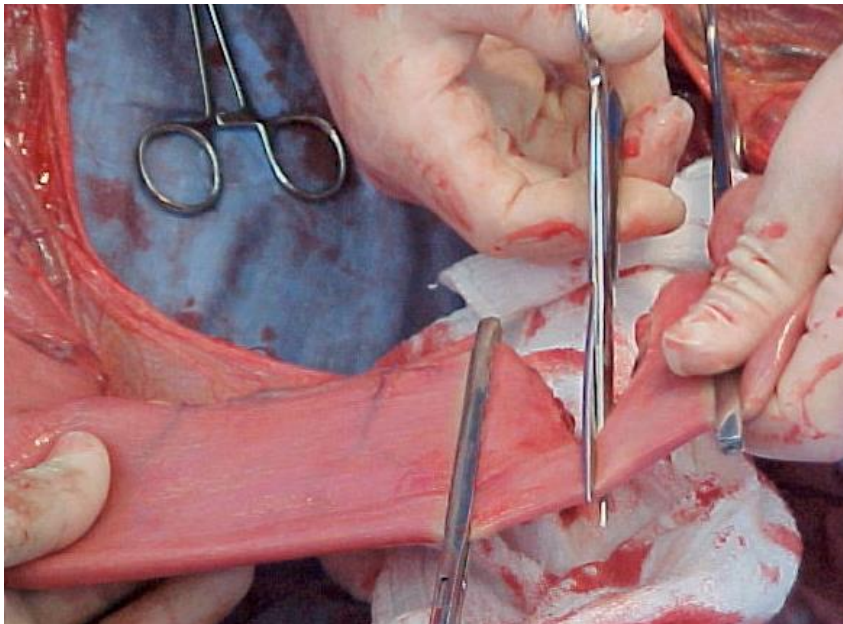
***Técnica cirúrgica aplicada
ao intestino delgado***

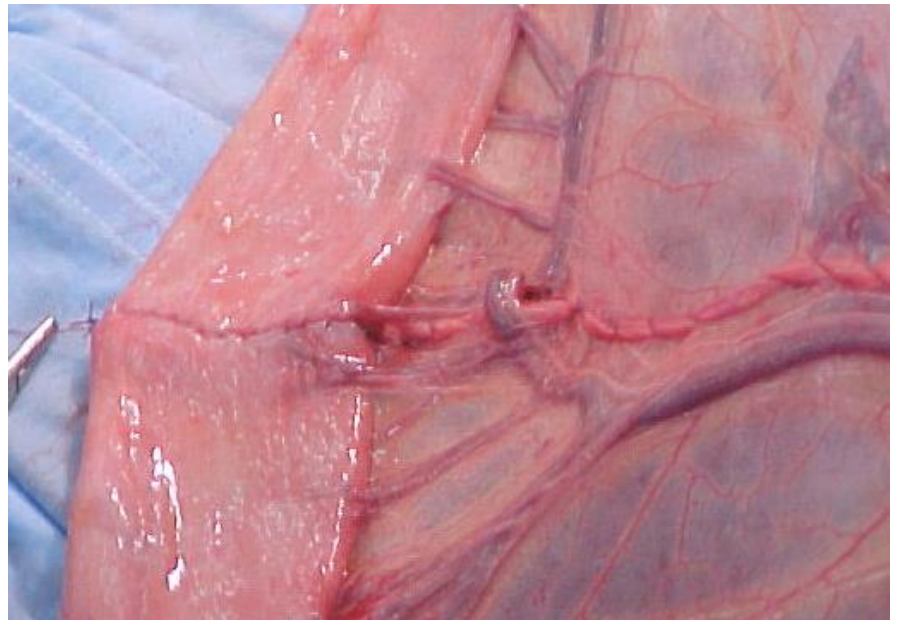
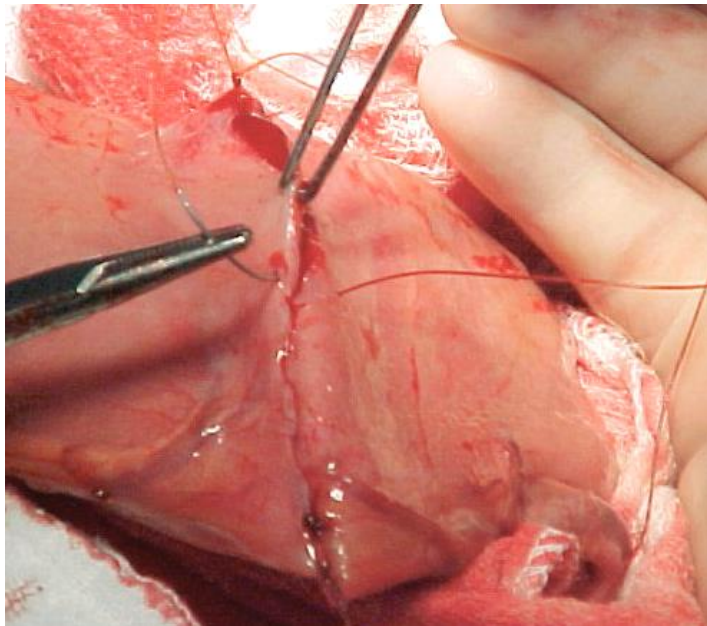
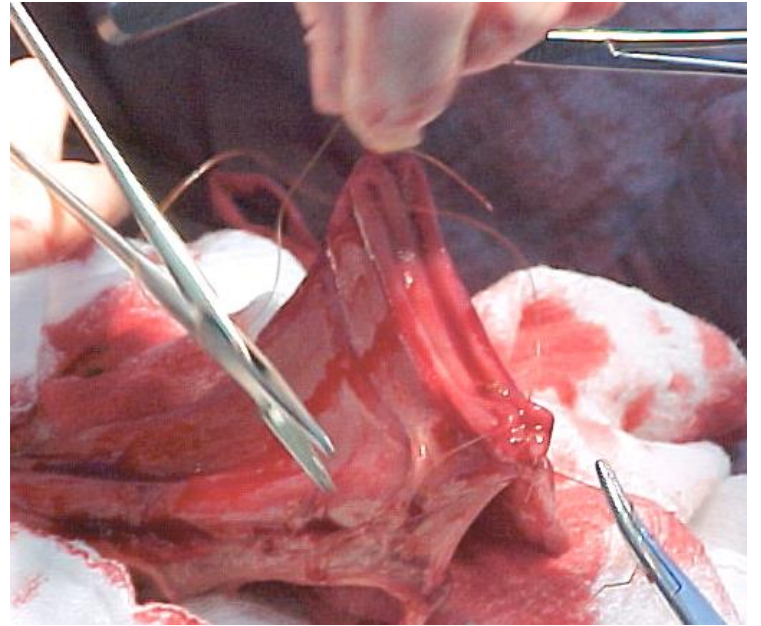
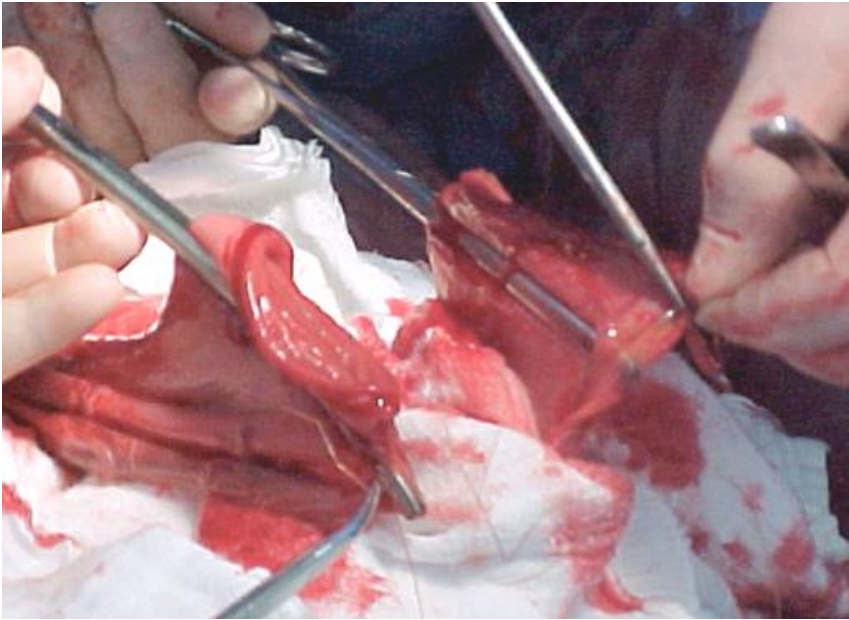
Enterectomy

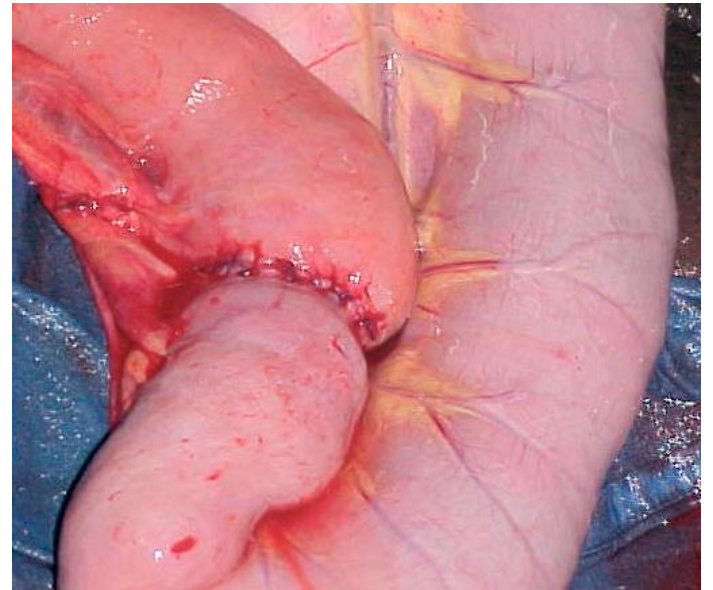
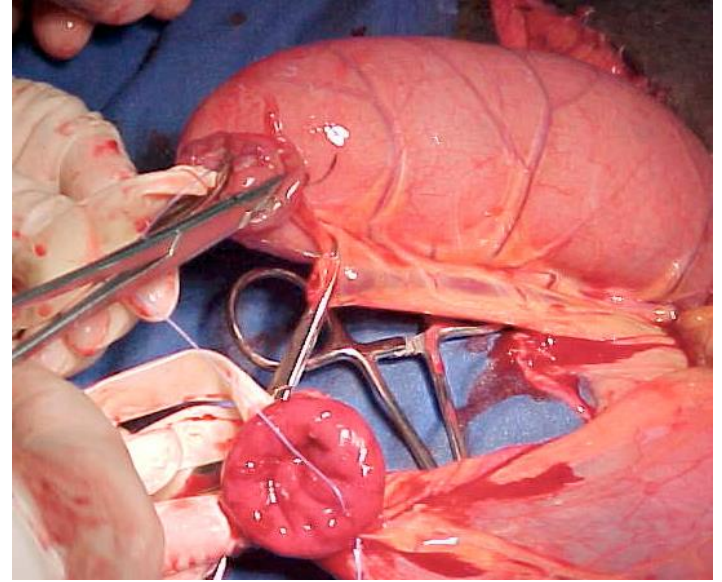
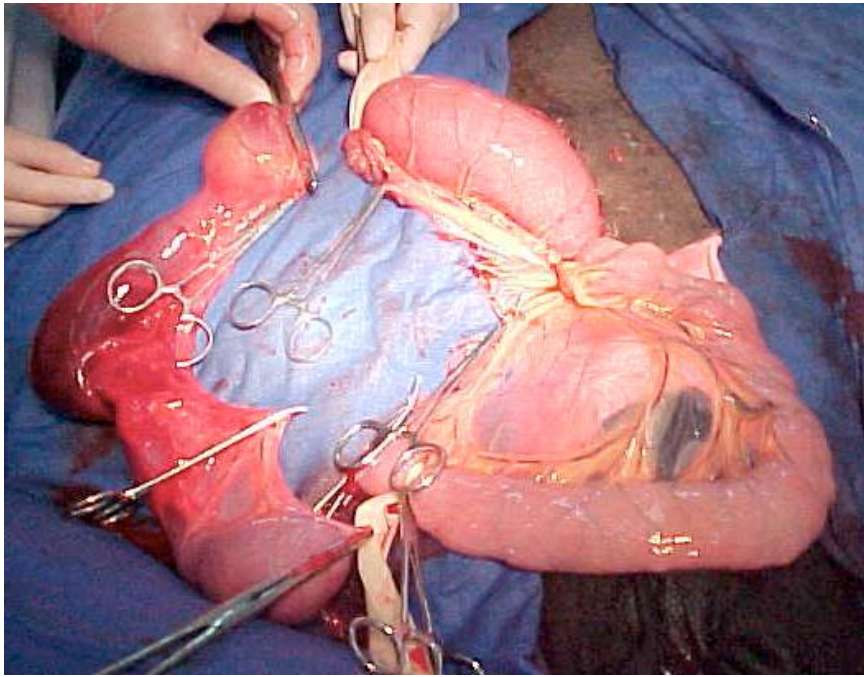


Enteroanastomose término-terminal

- sutura em dois planos:
 - 1º mucosa e submucosa
 - 2º seromuscular
 - fio absorvível
 - Contínua X interrompida



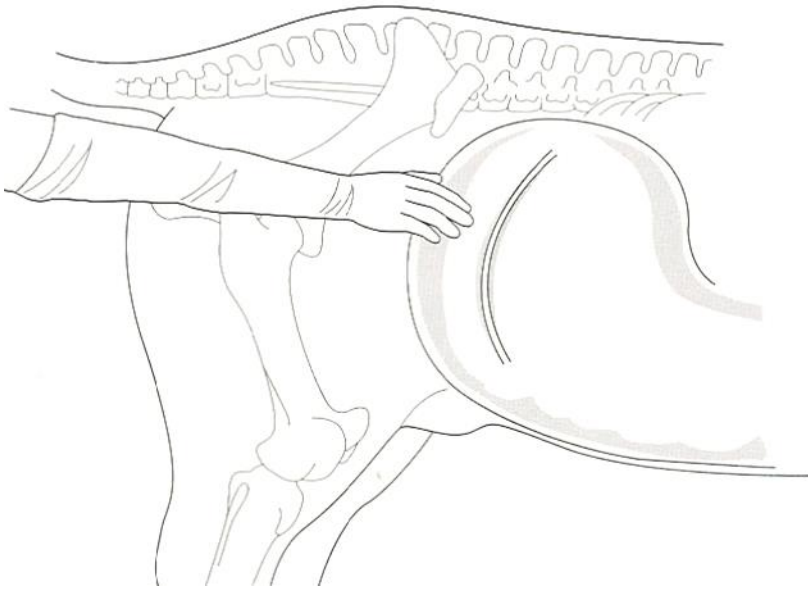




***Técnica cirúrgica
aplicada ao intestino
grosso***

Tiflocentese (durante celiotomia)

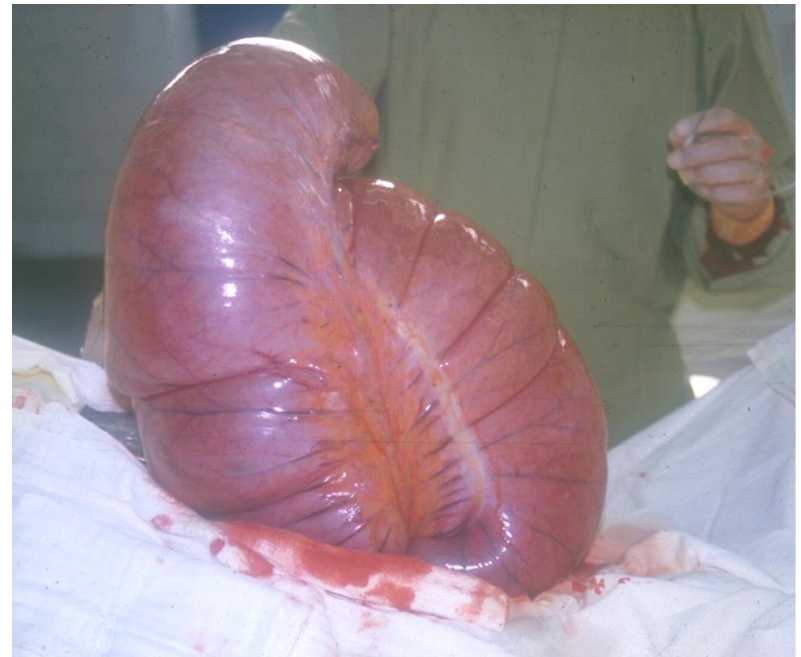
- Indicações:



Material:

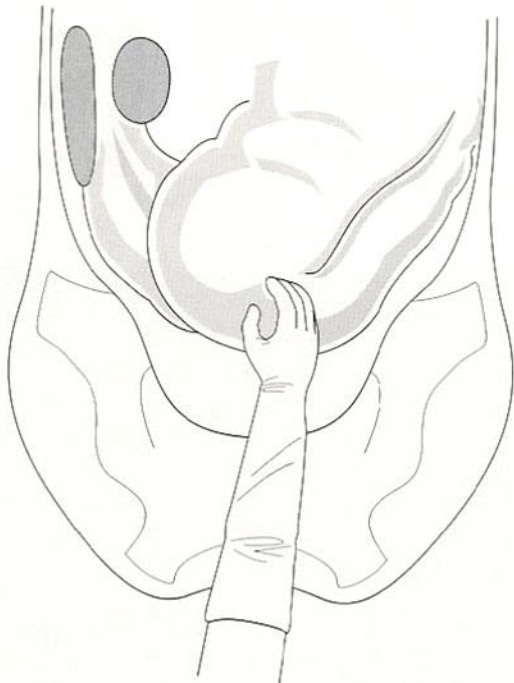
- Agulha 40x16
- Equipo
- Aspirador cir.

Timpanismo de ceco

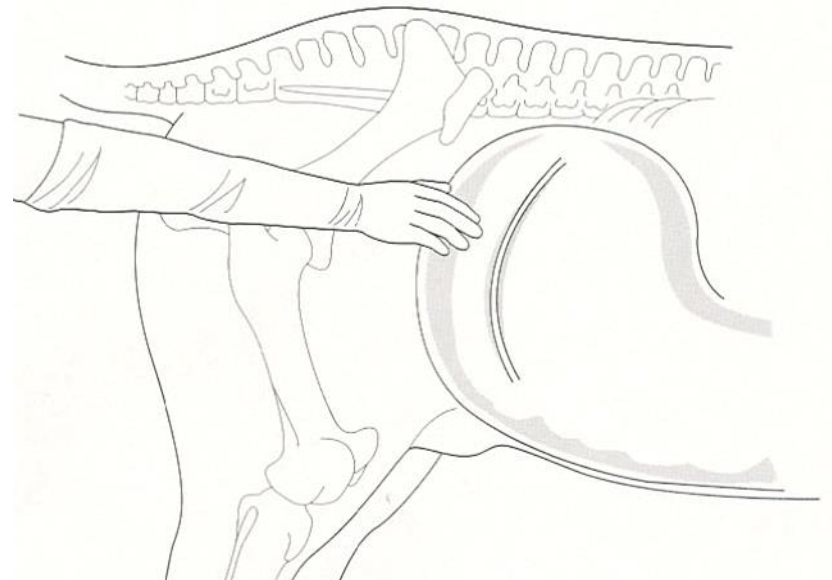


Tiflotomia

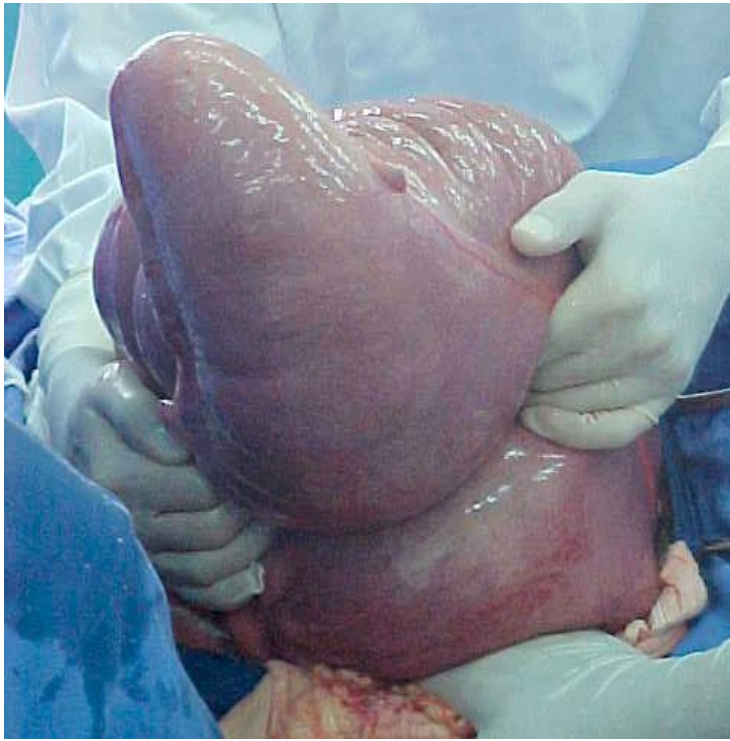
-Indicações:



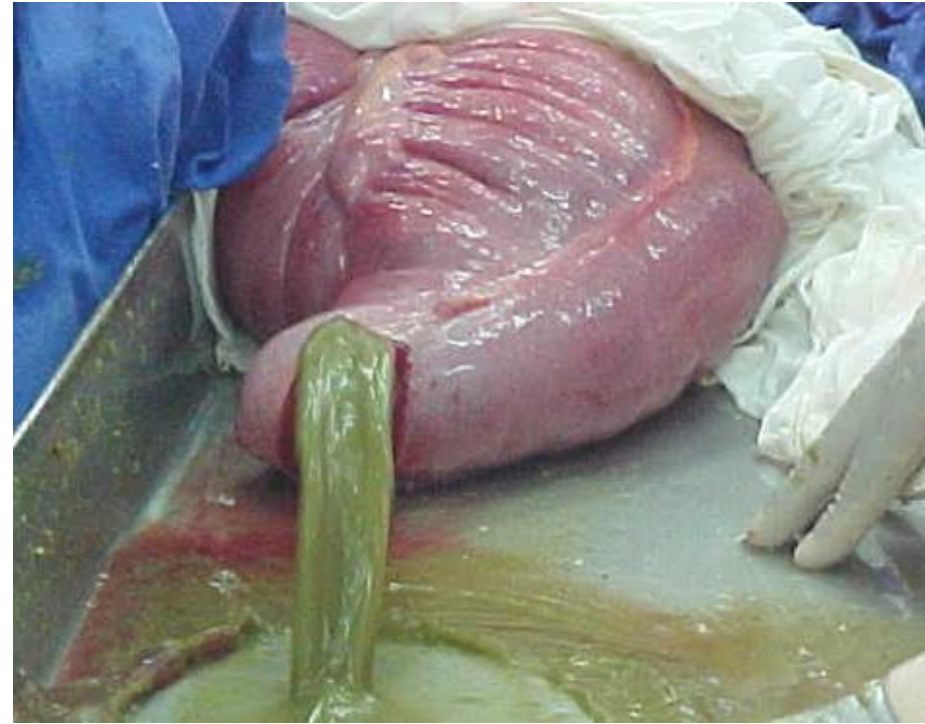a.



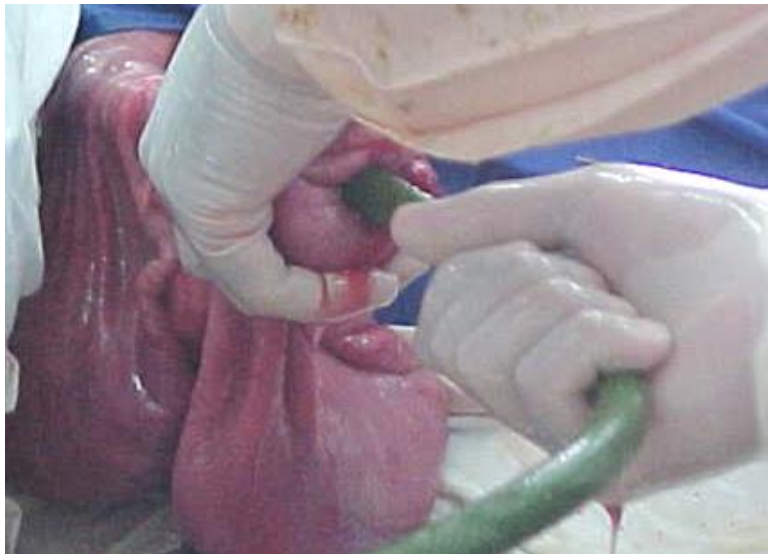Sobrecarga / Compactação e CE em ceco



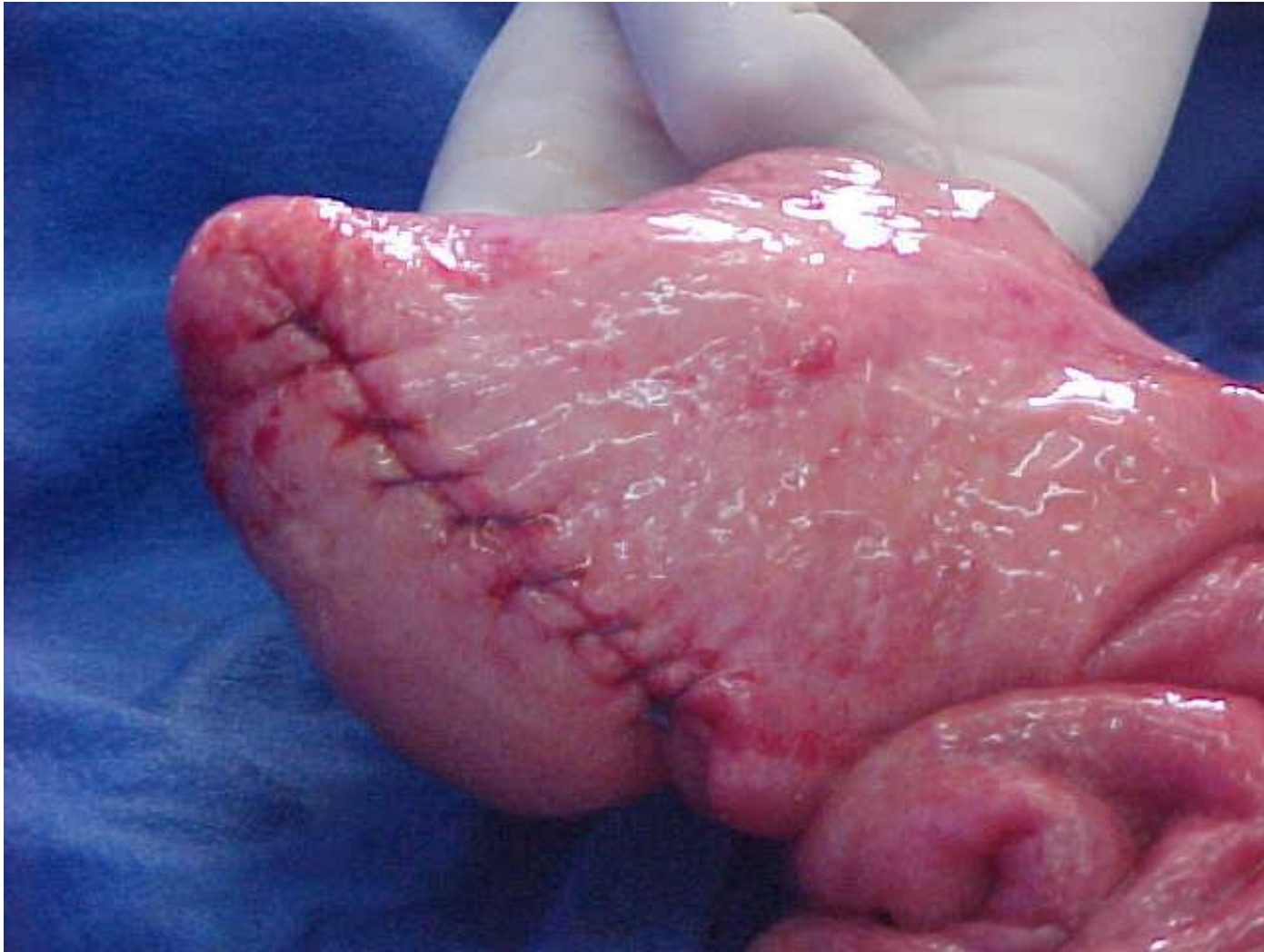exposição



enterotomia



lavagem

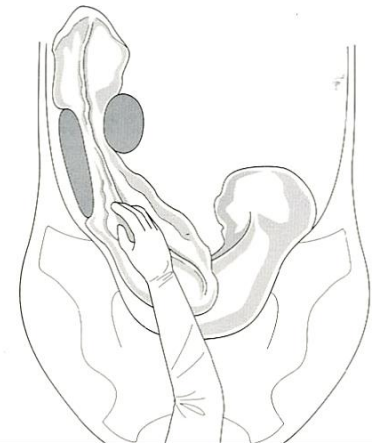
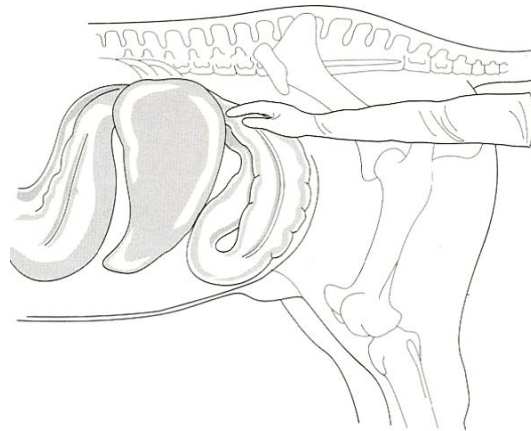
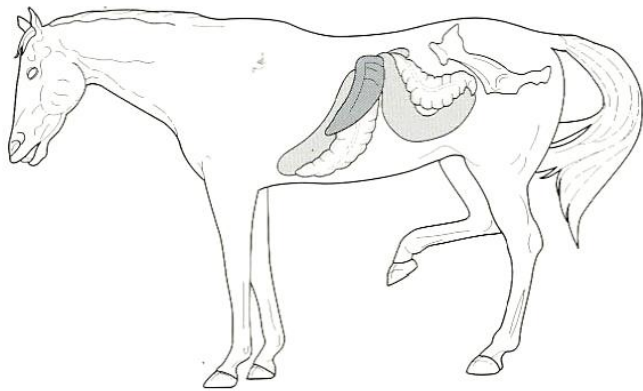
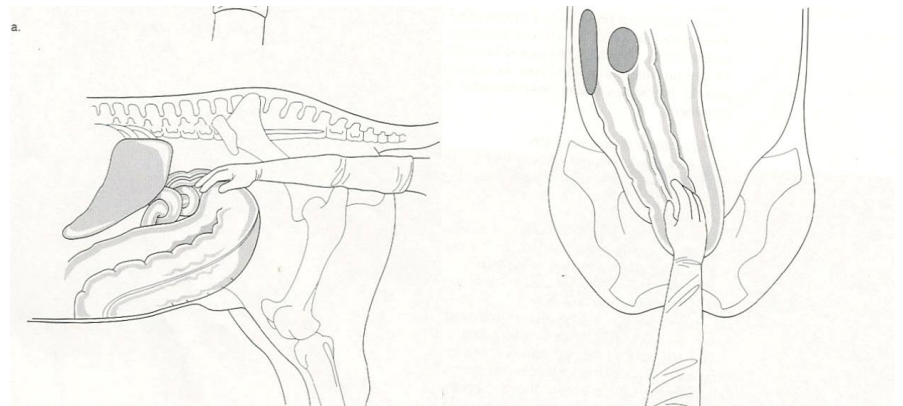


*Sutura - em 2 planos: cerzidura e Lembert
cerzidura e Cushing
Fio – absorvível 0 ou 00*

Enterotomia cólon maior

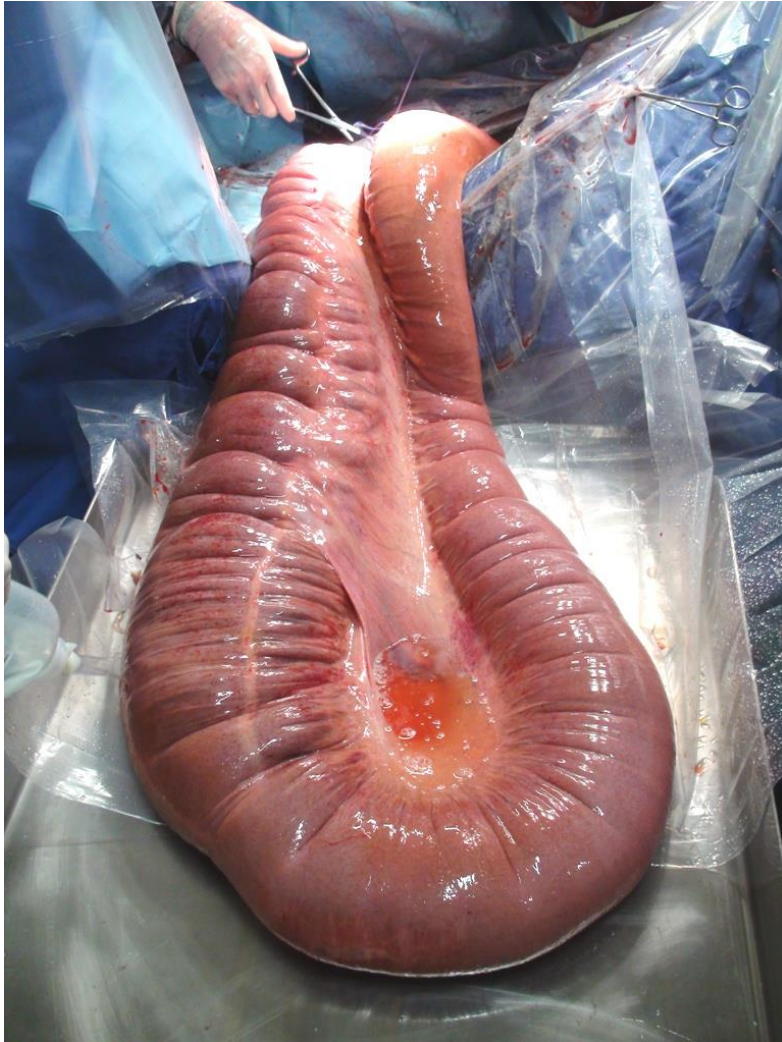
Indicações:

- *Compactação de cólon*
- *Enterolitíase*
- *Corpos estranhos*
- *Sobrecarga por deslocamento*

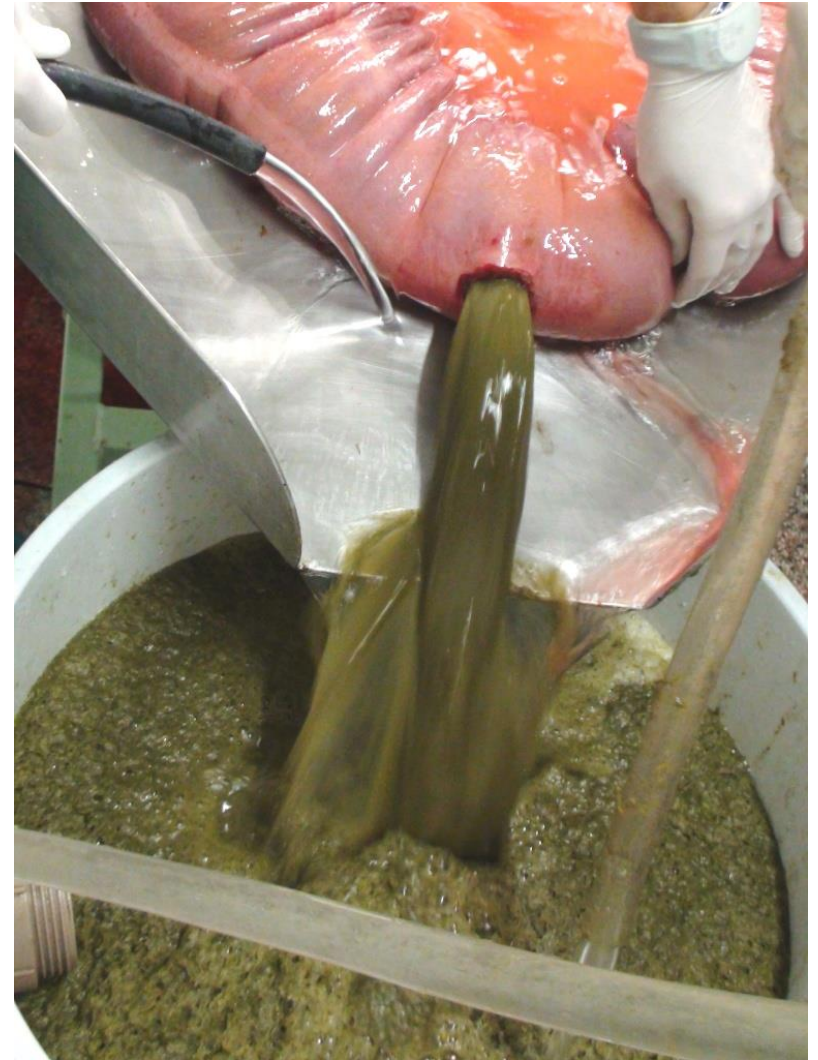
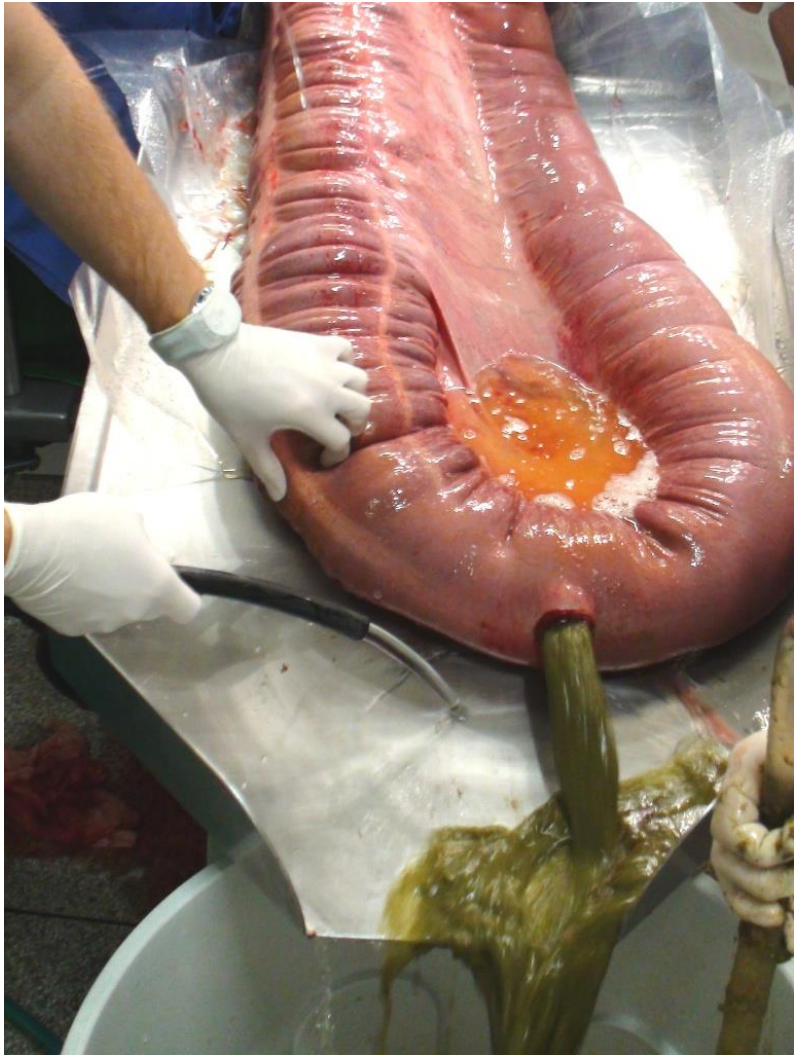
-Encarceramento nefroesplênico


Exposição do cólon



Enterotomia do cólon



Drenagem e sutura de cólon



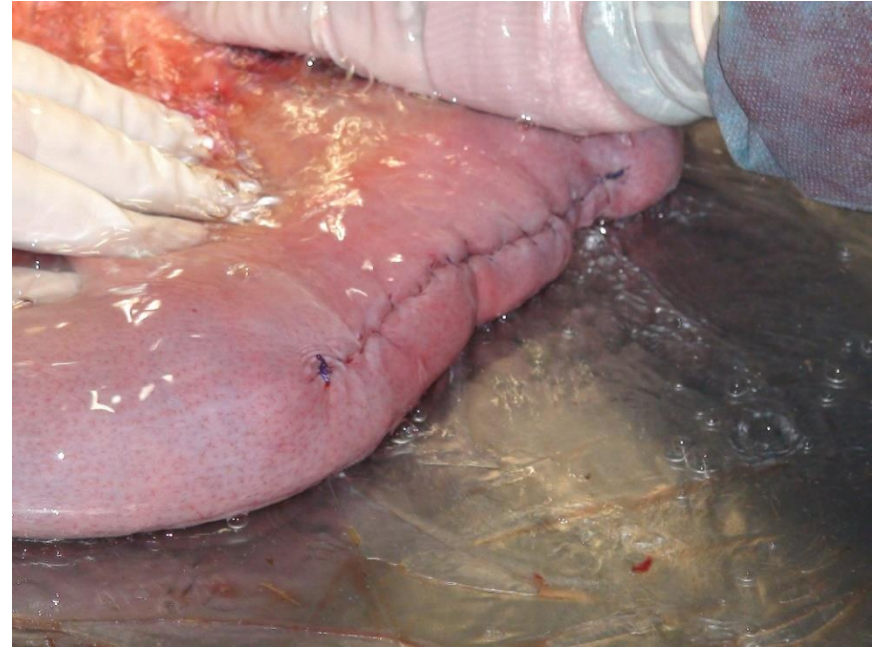
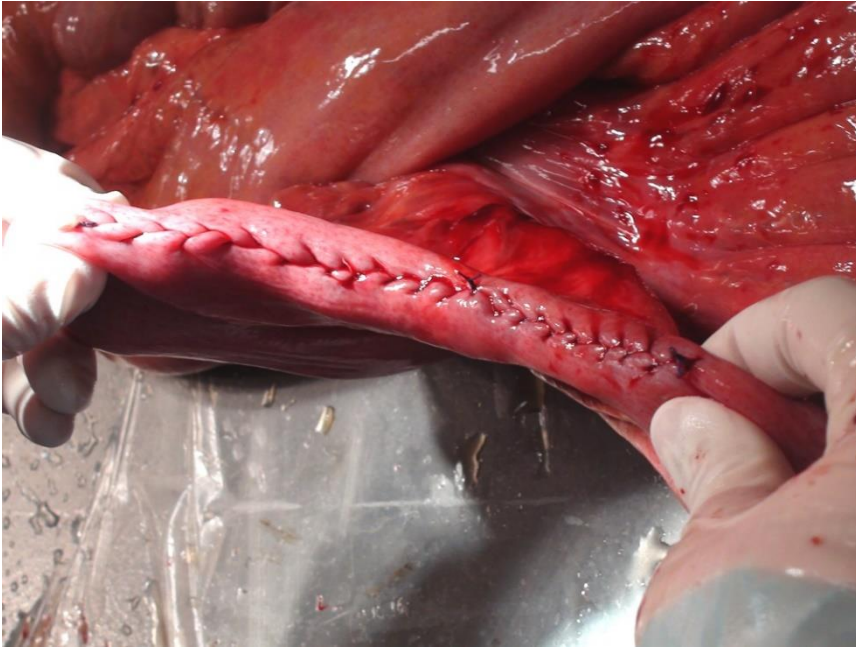
*Drenagem – campo contaminado
e não contaminado*

*Sutura: 2 planos – 2 invaginantes
- 1 simples +
1 invaginante*

Lavagem externa – 2 tempos

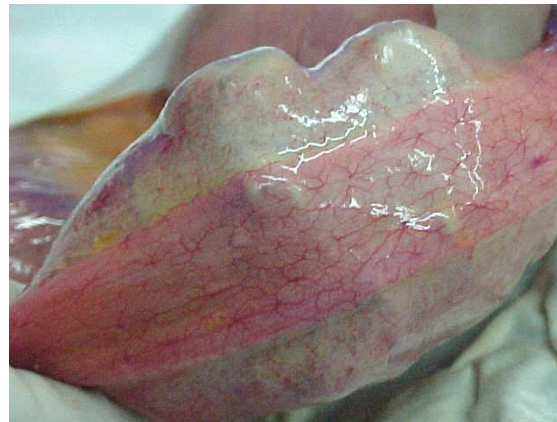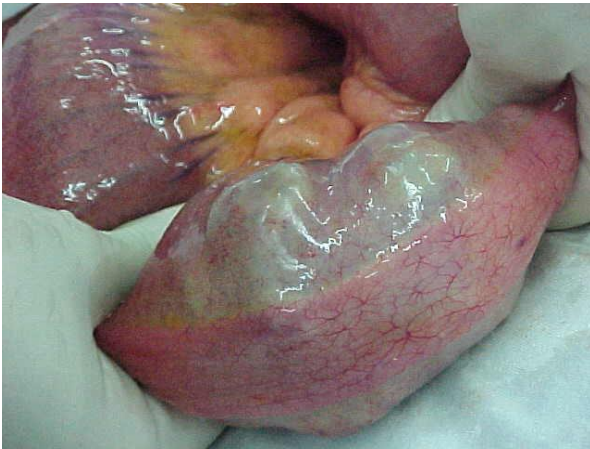
Reposição

Enterorrafia c6lon

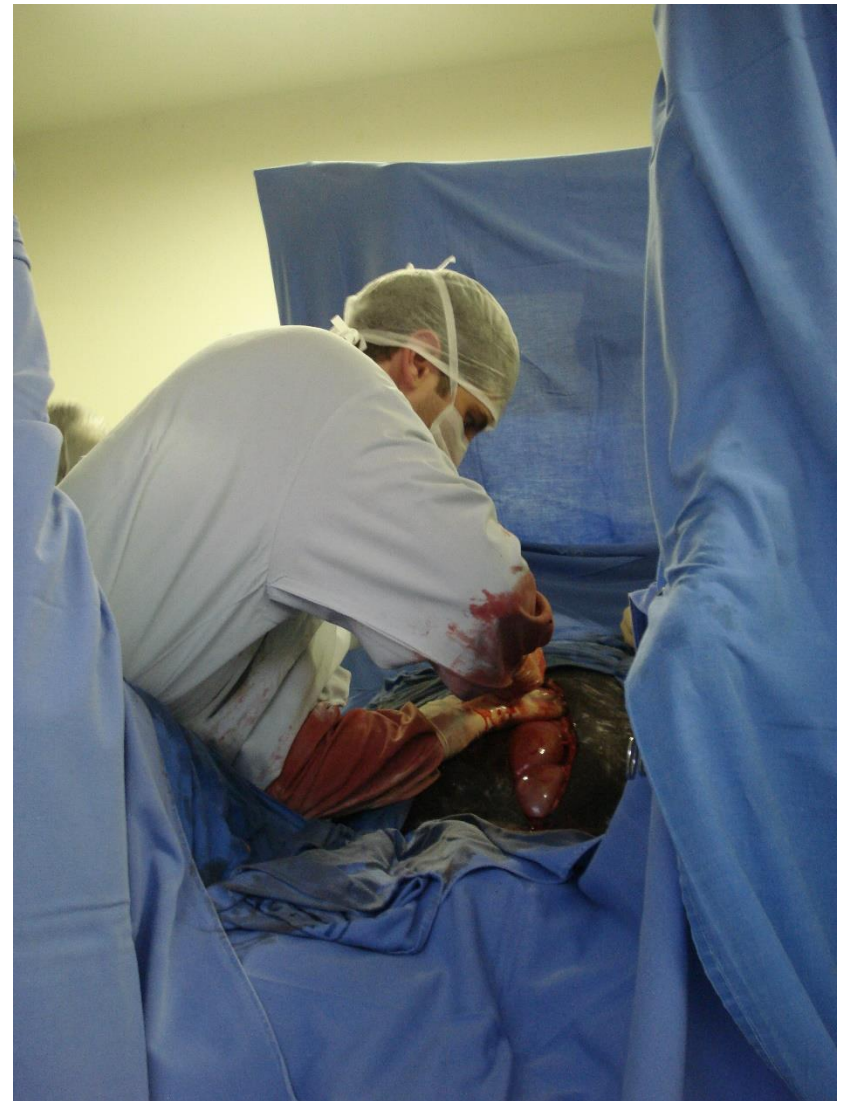
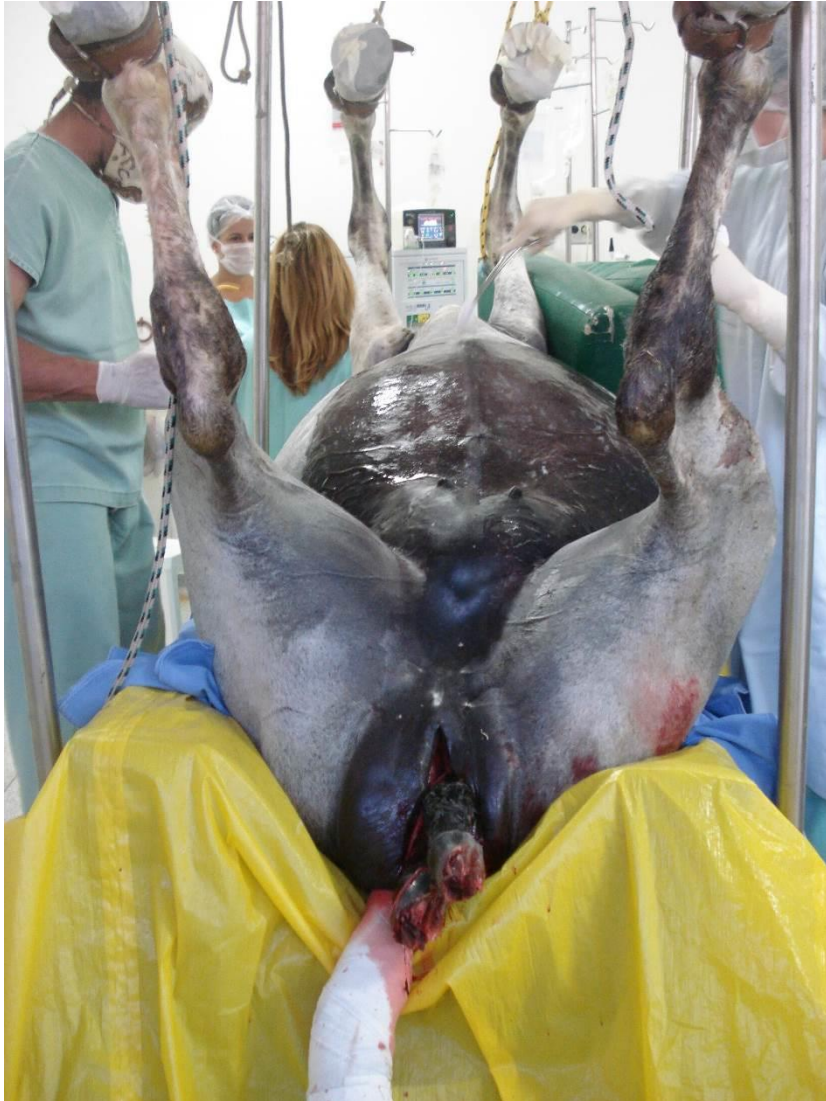
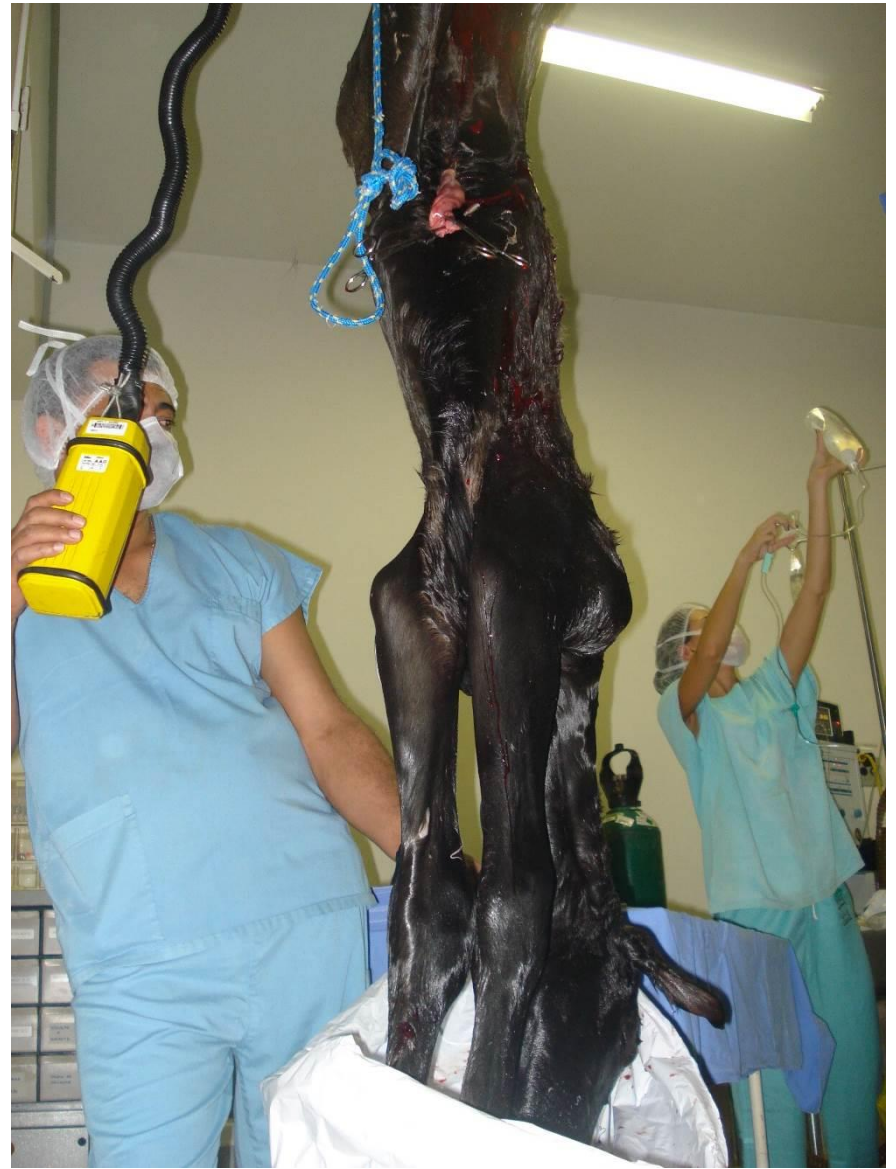
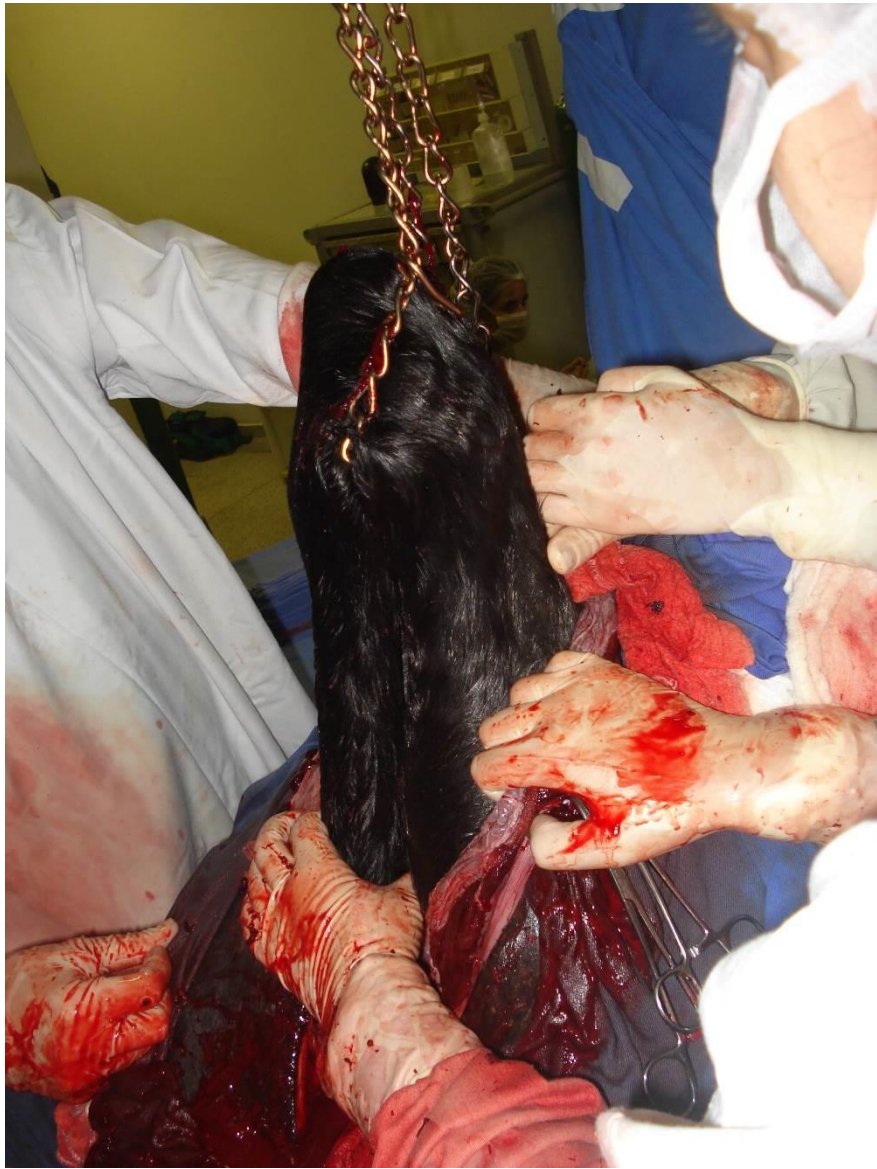Enterotomia de cólon menor

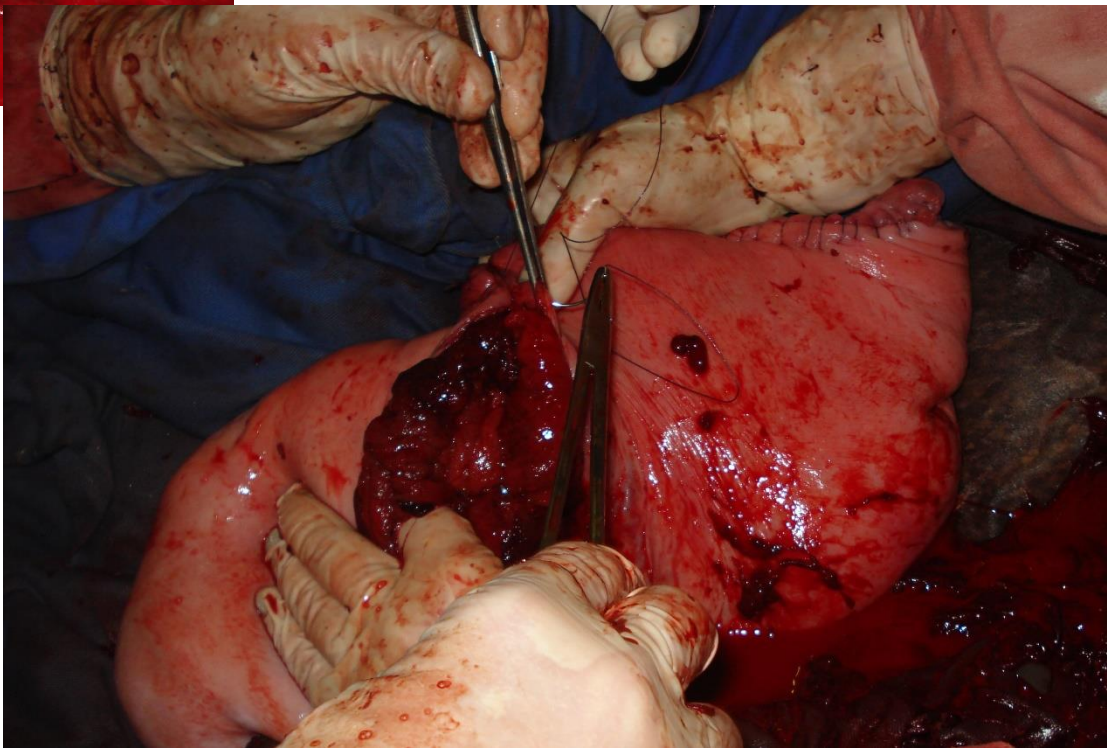
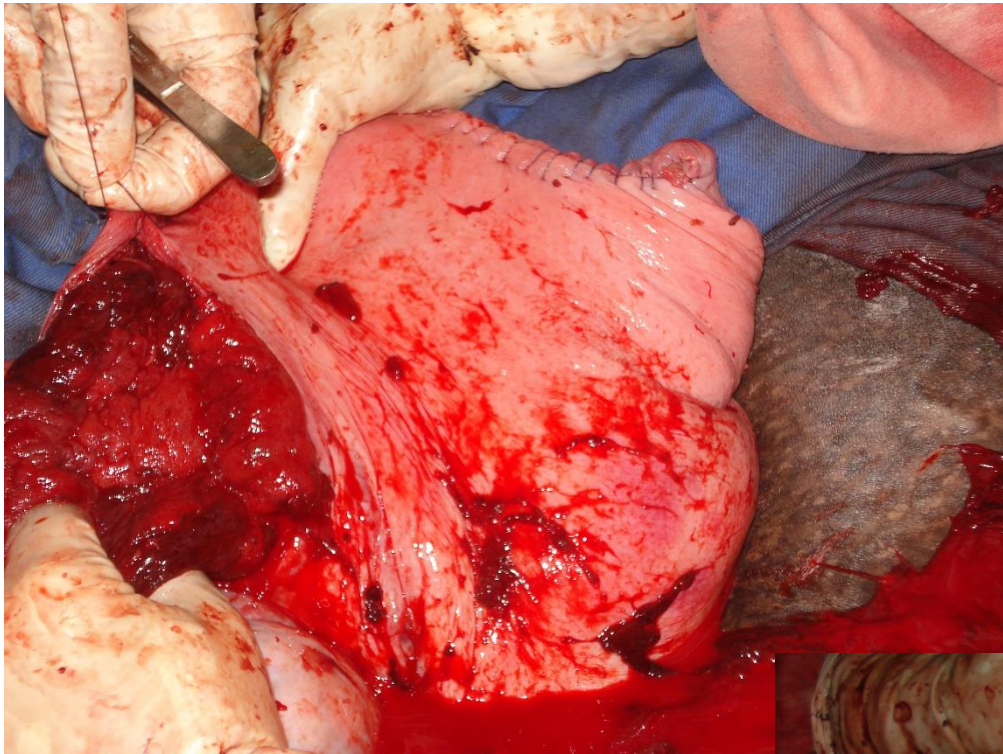
Indicações: - *compactação de cólon menor*
- *corpos estranhos*
- *enterolitíase*

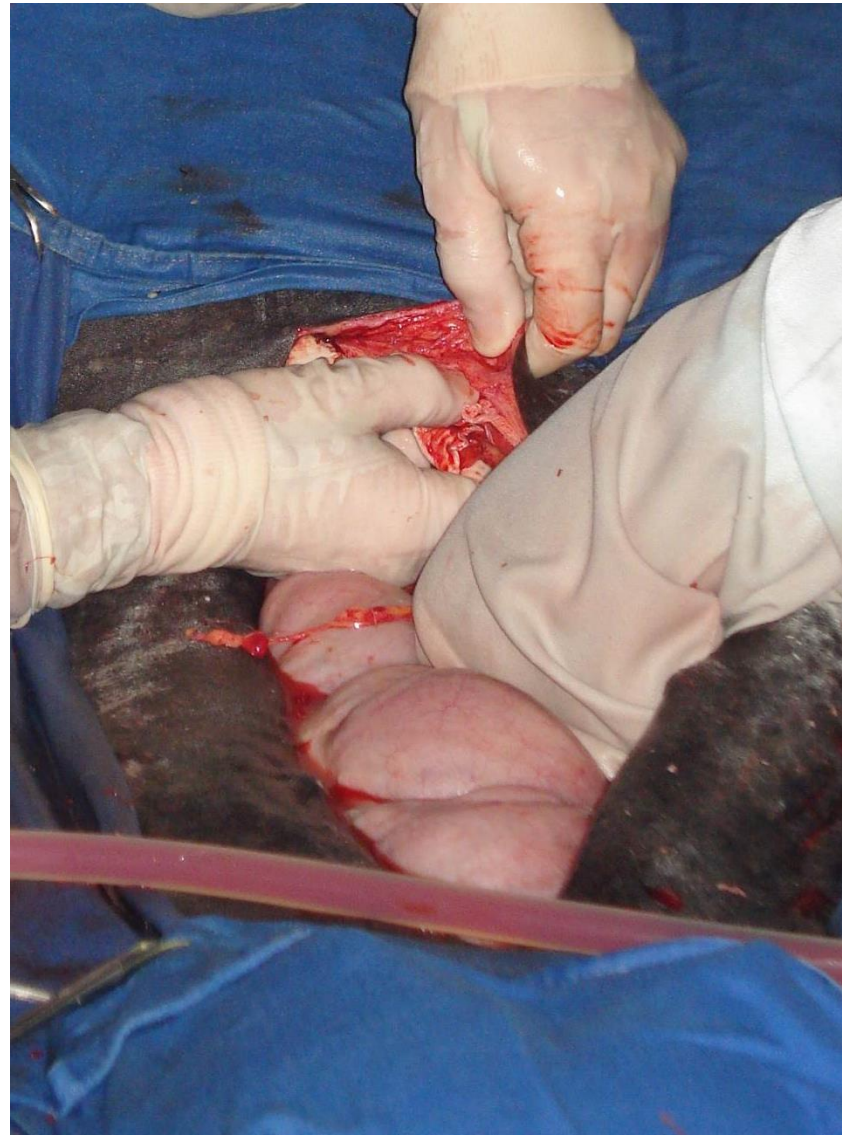
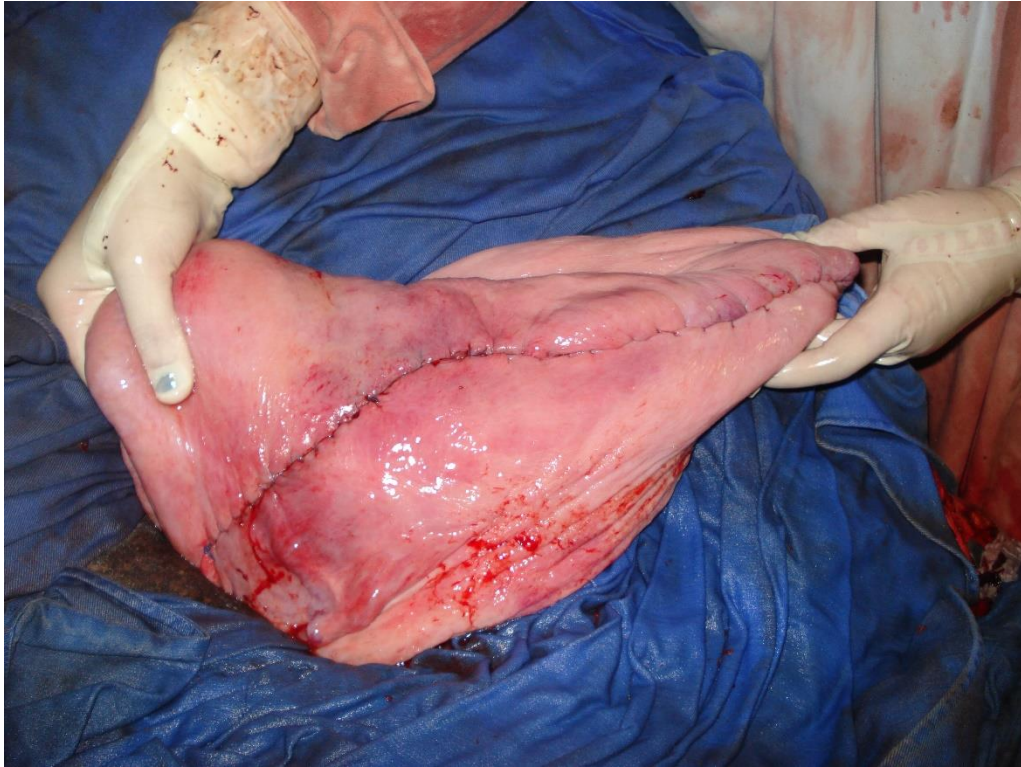
Distocia / Cesariana









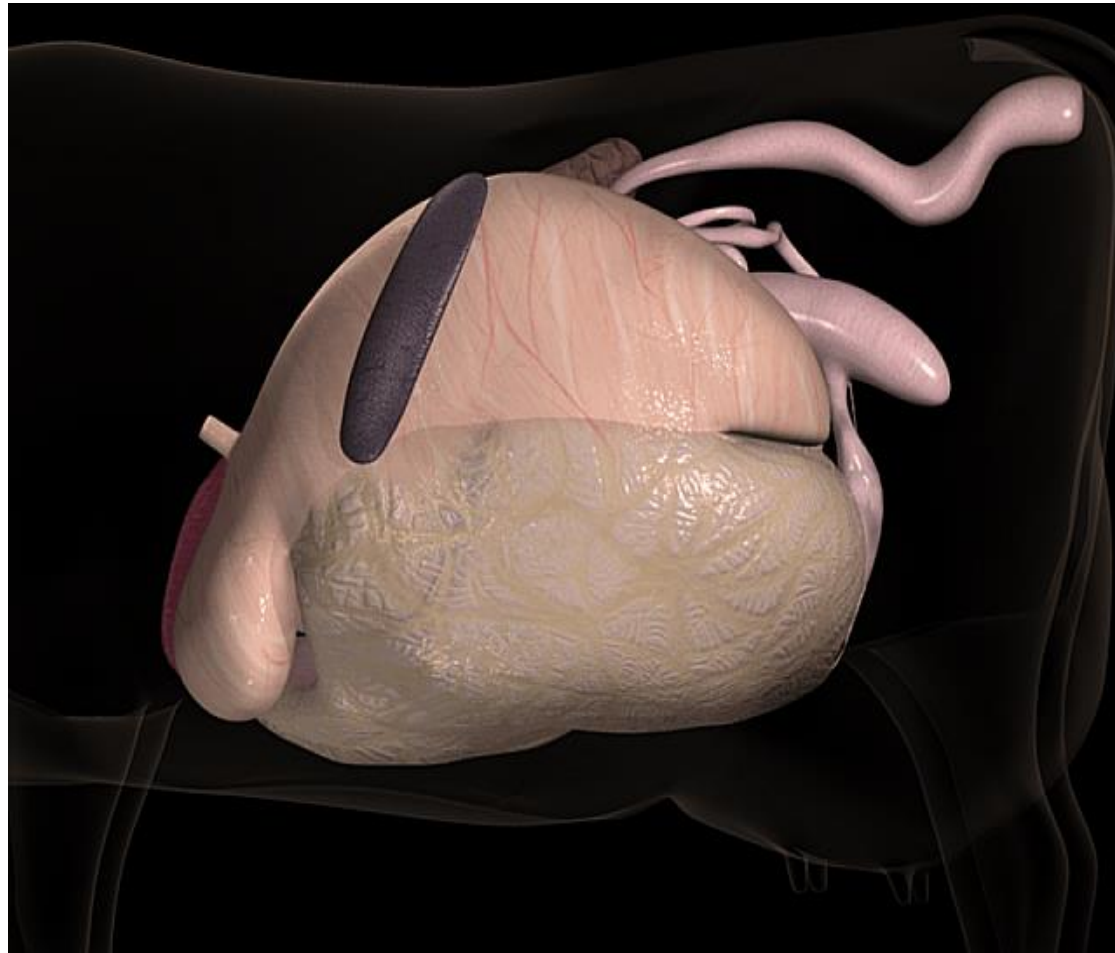
Técnica cirúrgica aplicada ao sistema digestório em bovinos

- Ruminotomia
- Abomasopexia/omentopexia

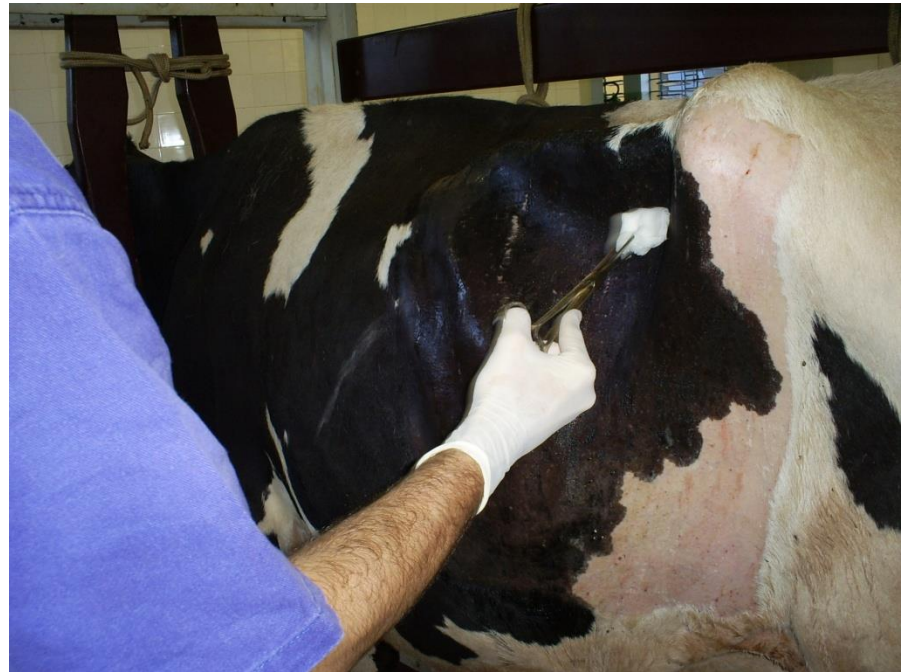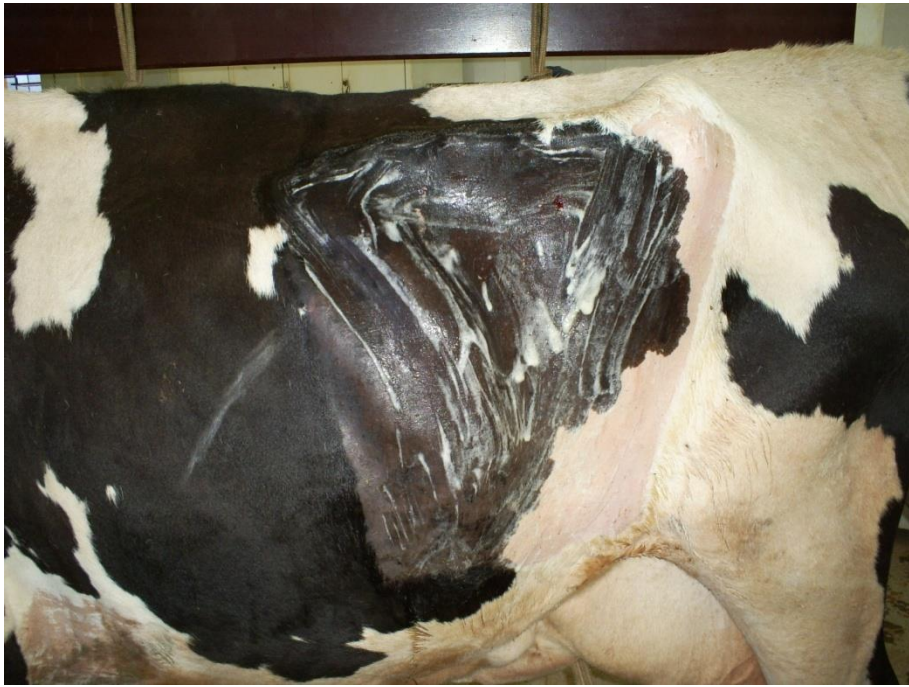Ruminotomia

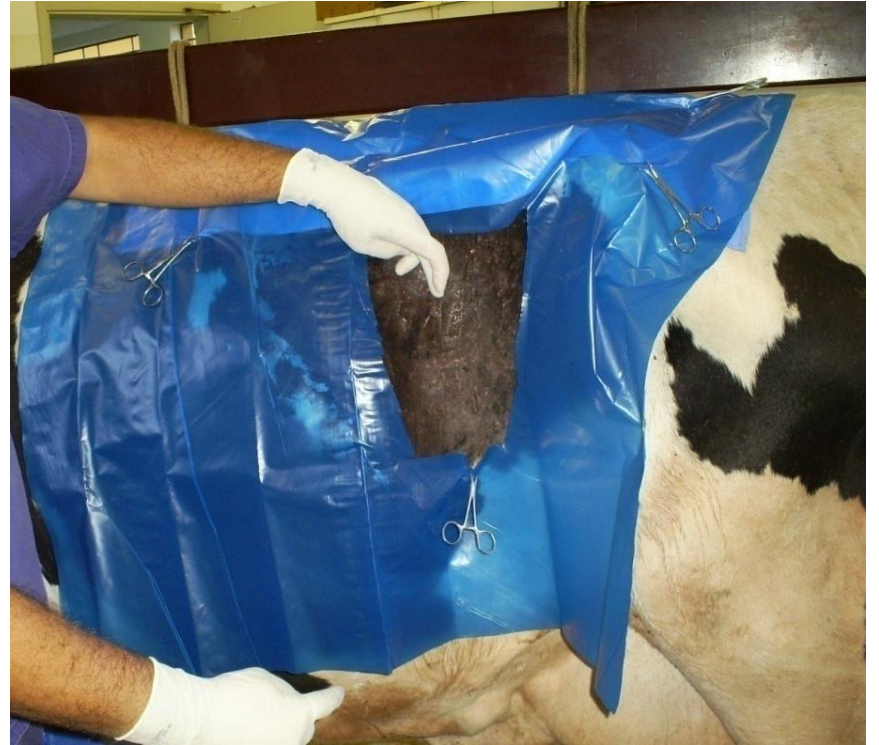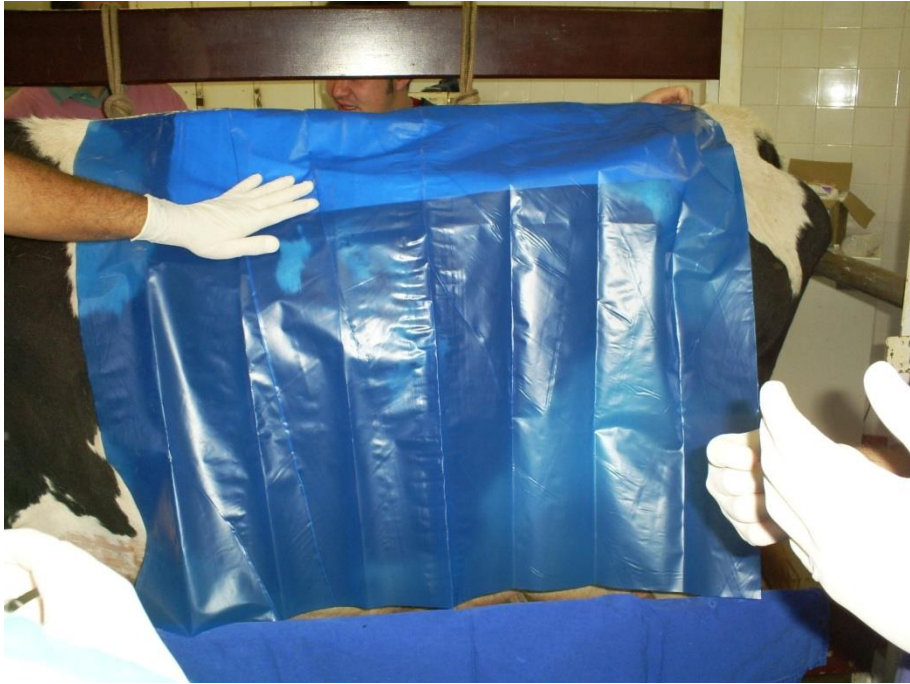- **Indicações:**
 - perfuração do retículo por C.E. metálico pontiagudo;
 - sobrecarga ruminal;
 - obstrução do forame retículo-omasal (plástico).

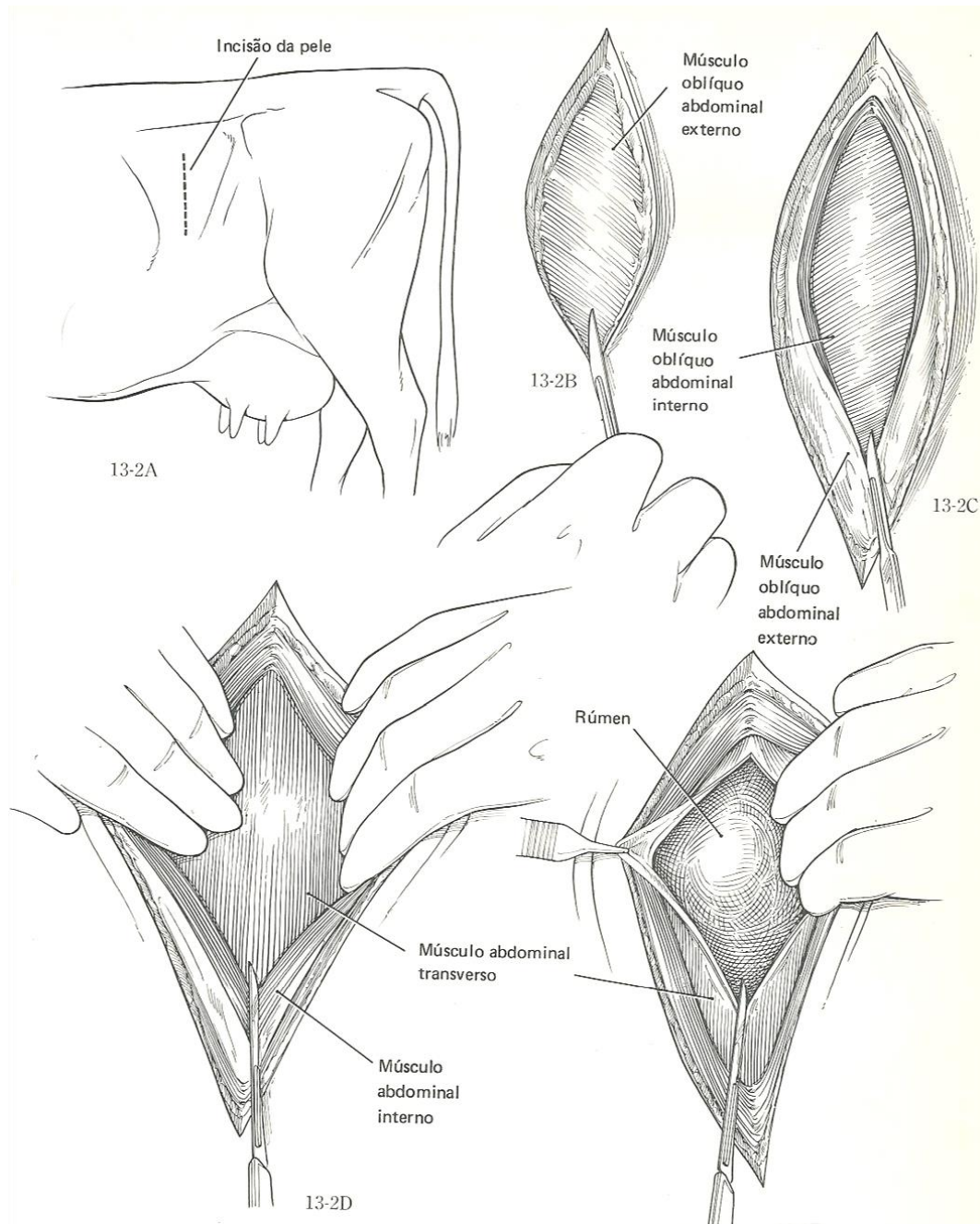
Anatomia cavidade abdominal ruminantes – esquerdo





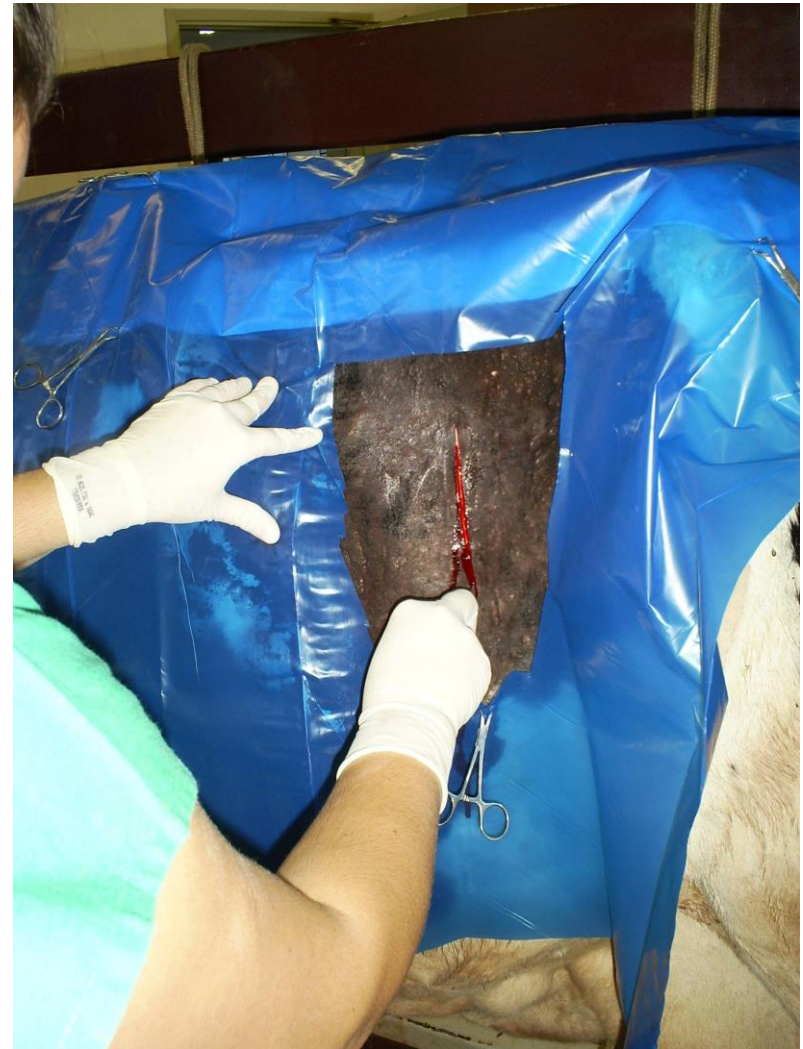





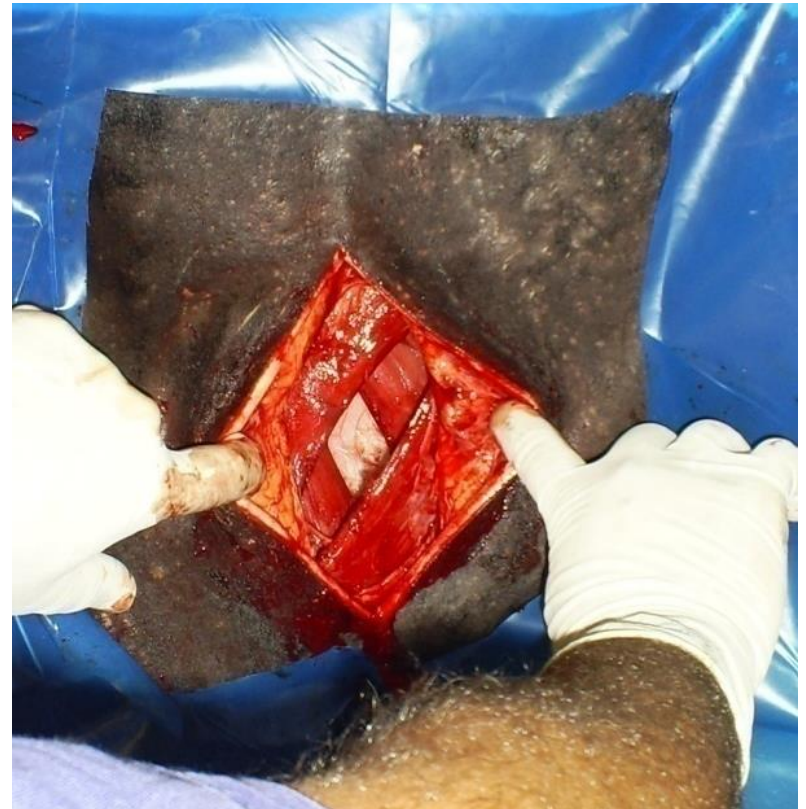Ruminotomia

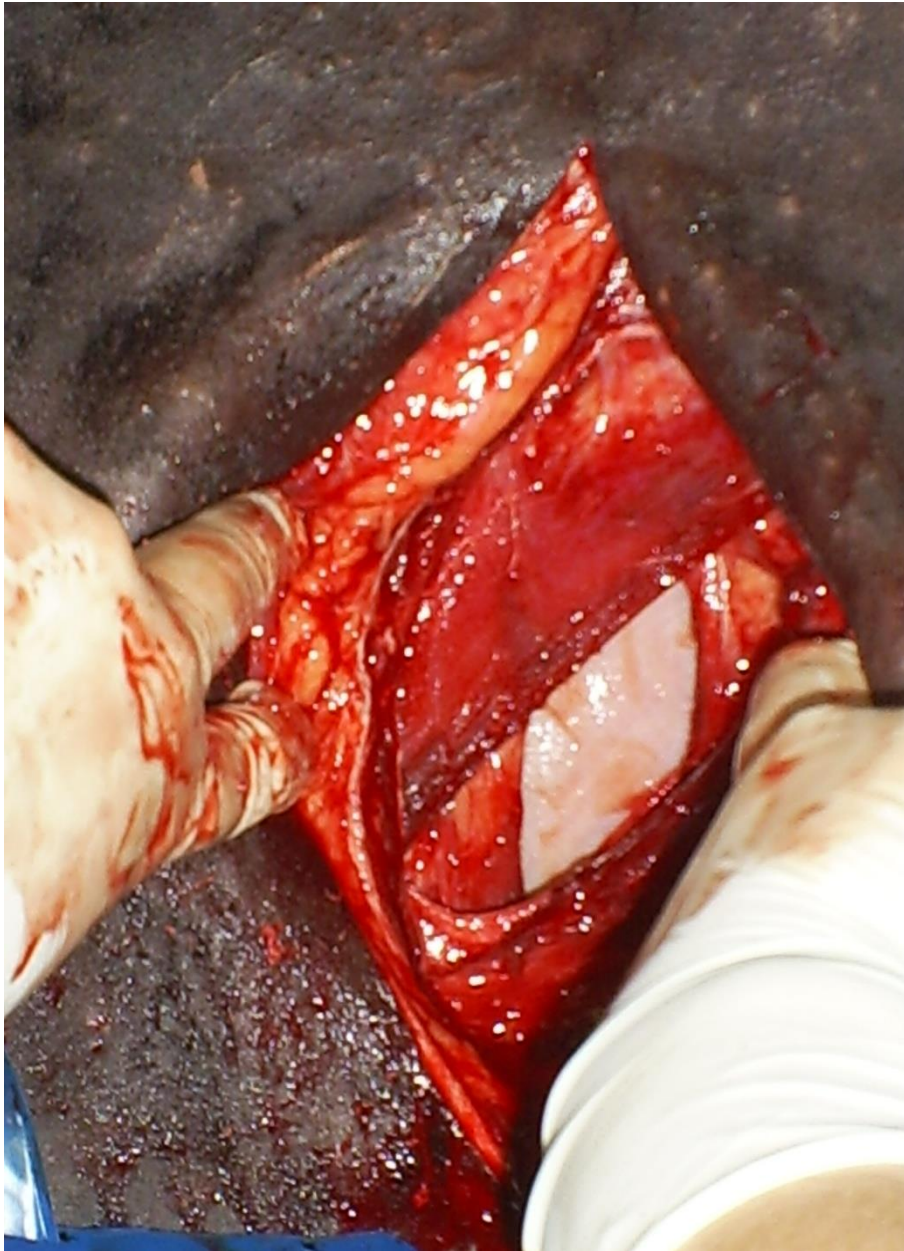
- **Técnica cirúrgica:**
 - laparotomia flanco esquerdo
 - incisão de pele na fossa paralombar (20 cm)



Ruminotomia

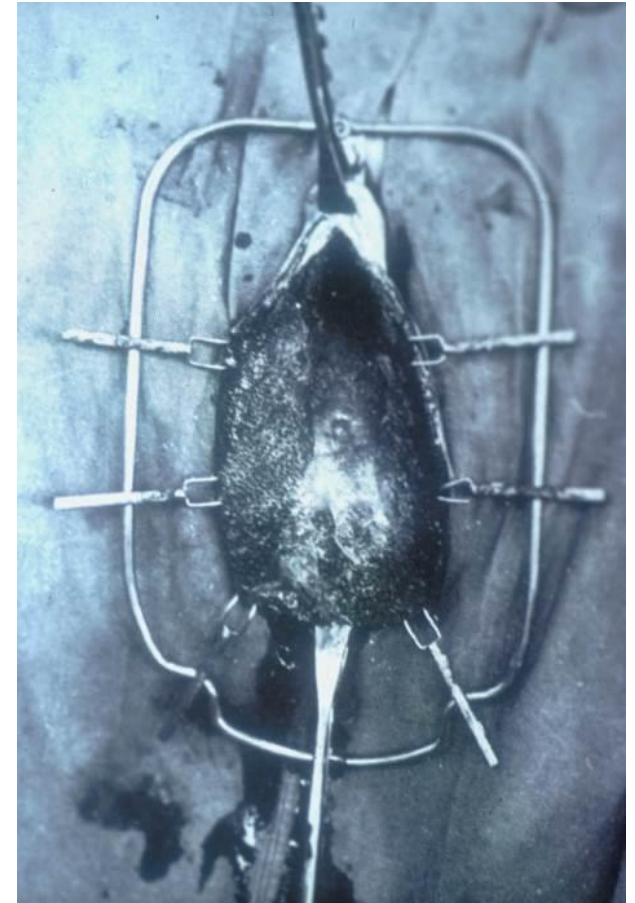- **Técnica cirúrgica:**
 - Incisão ou divulsão dos três planos musculares
 - incisão do peritônio





Ruminotomia

- Técnica cirúrgica:
 - ancoragem do rúmen;
 - isolamento:
 - Bastidor (afastador de Weingart) ou sutura no peritônio ou pele.



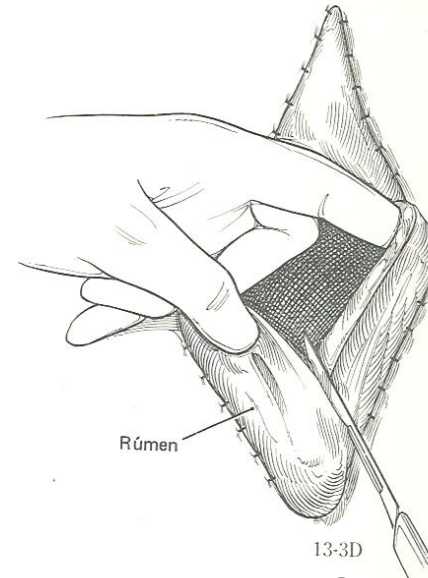
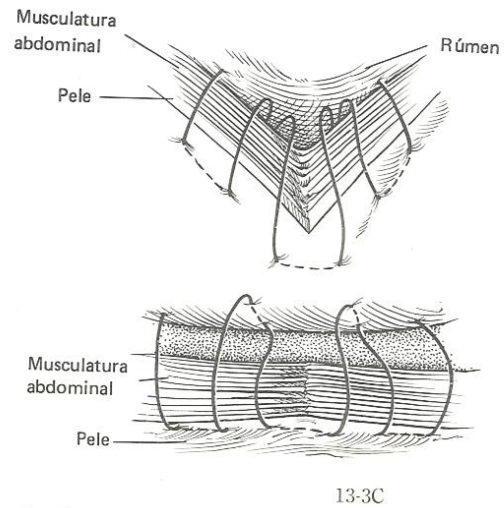
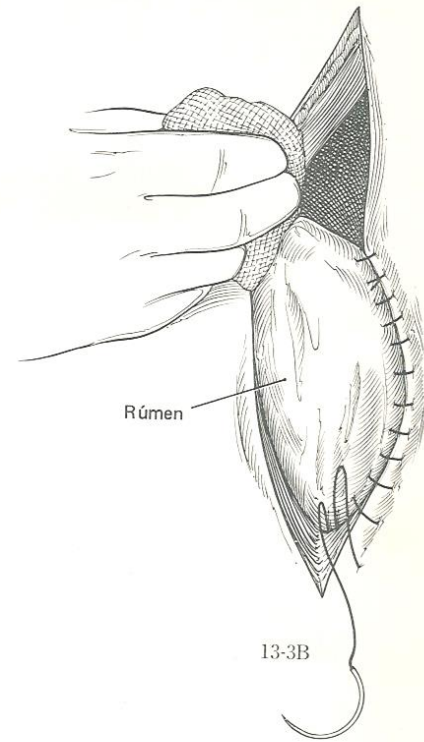
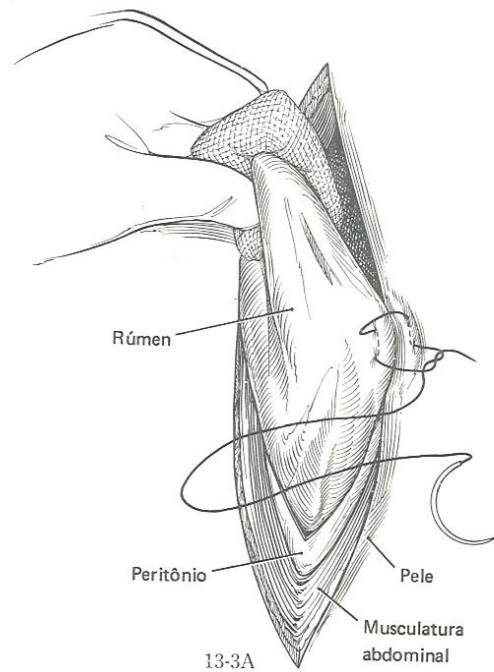
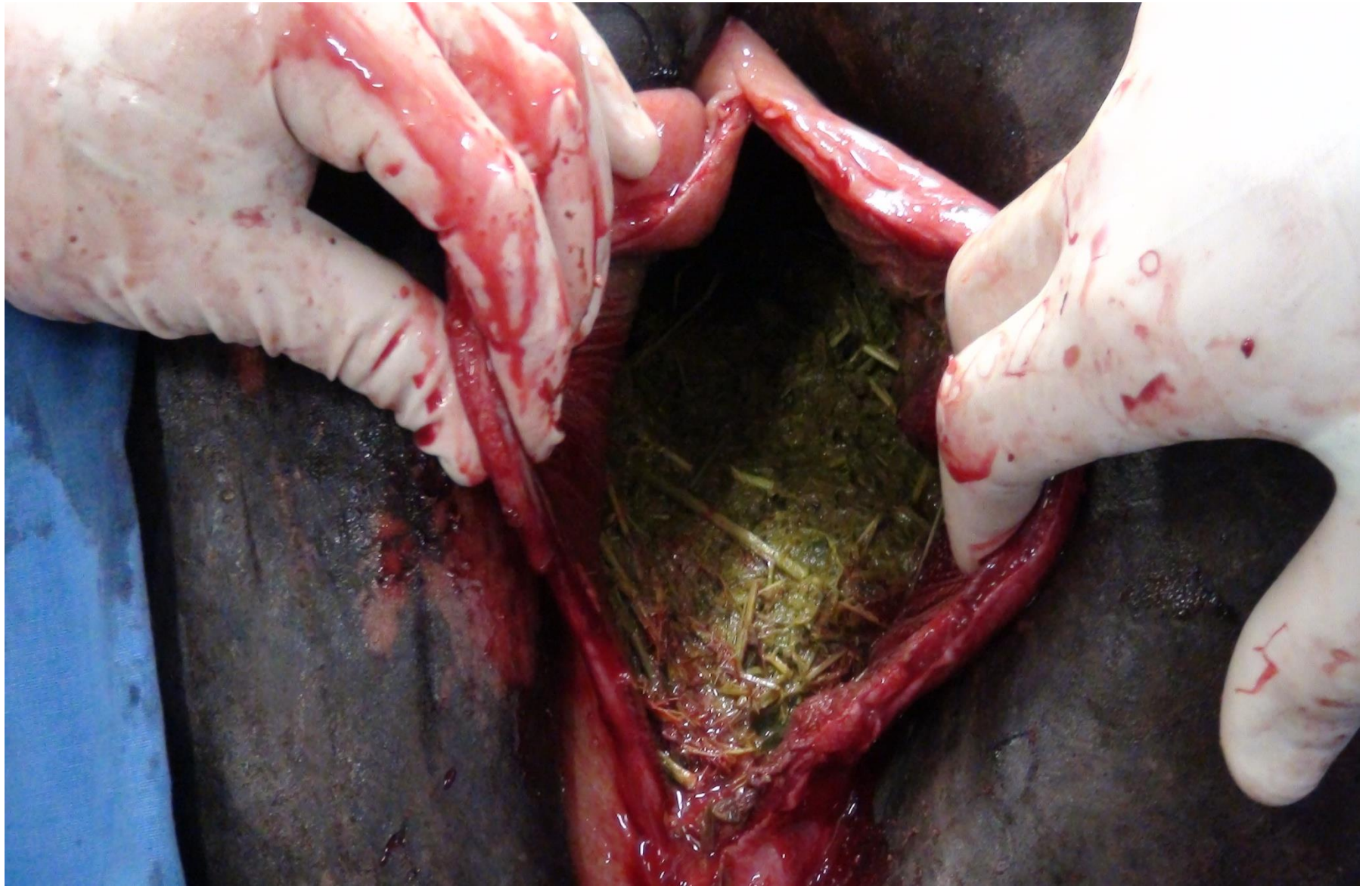
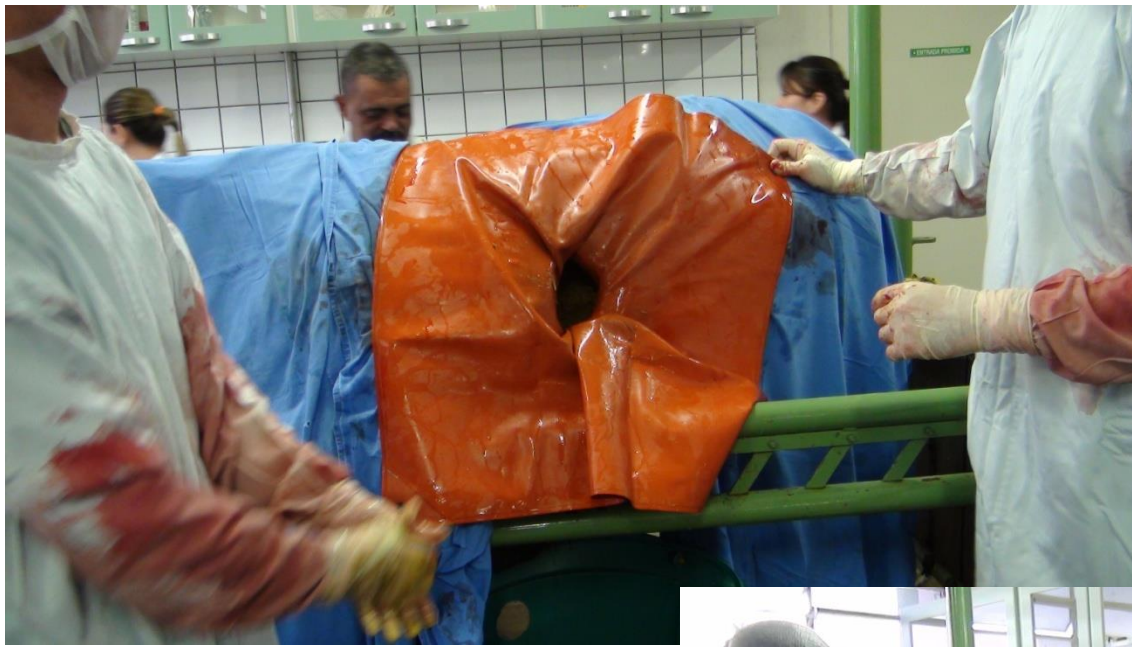
Fig. 13-3. Rumenotomia.

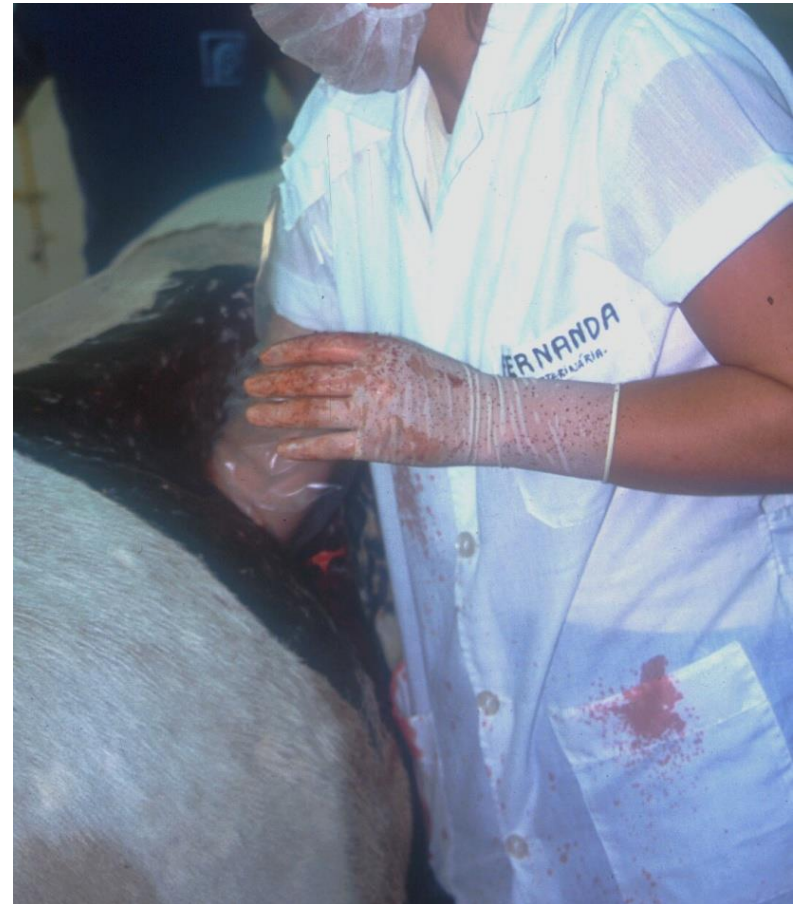13-3D



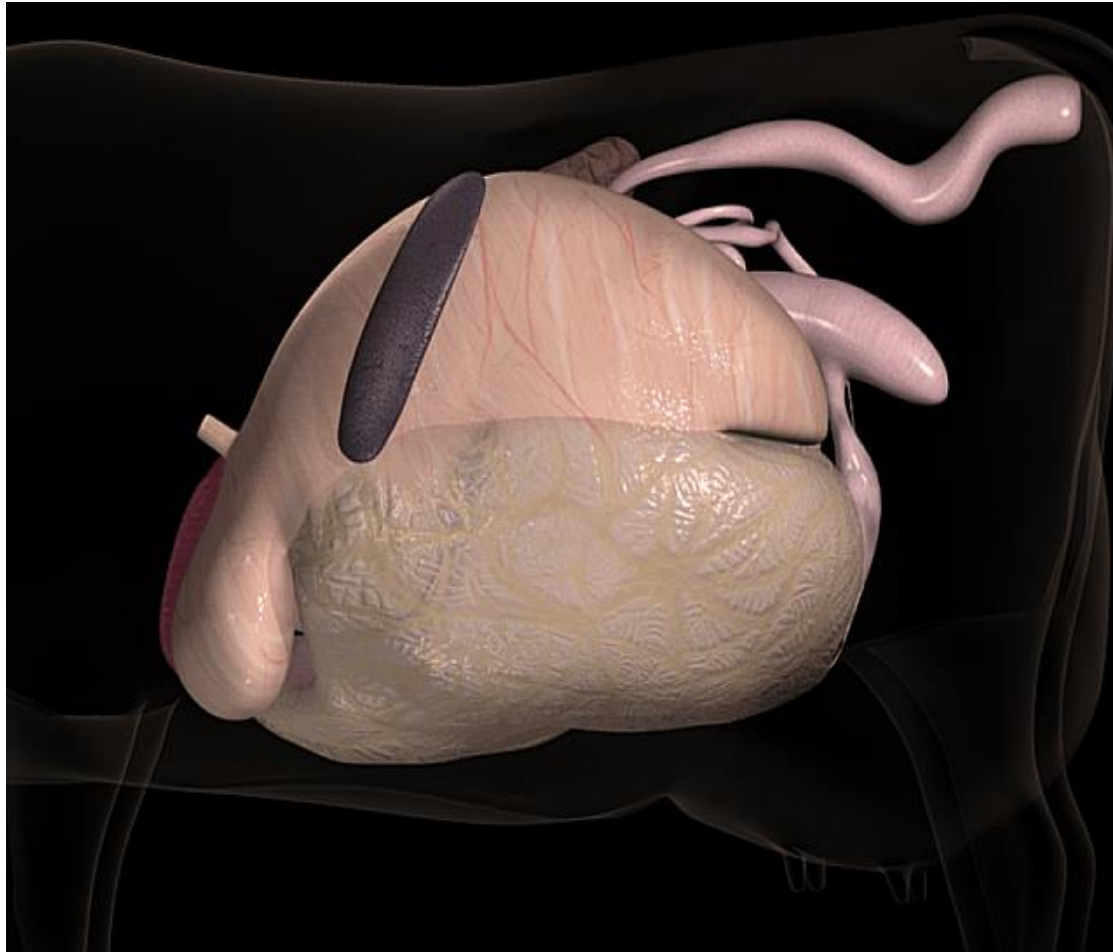

Ruminotomia

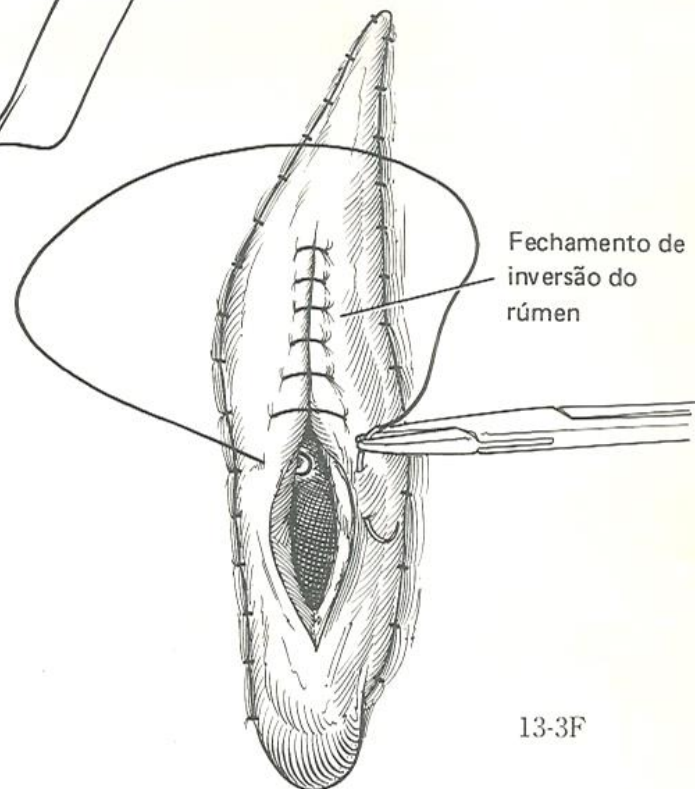
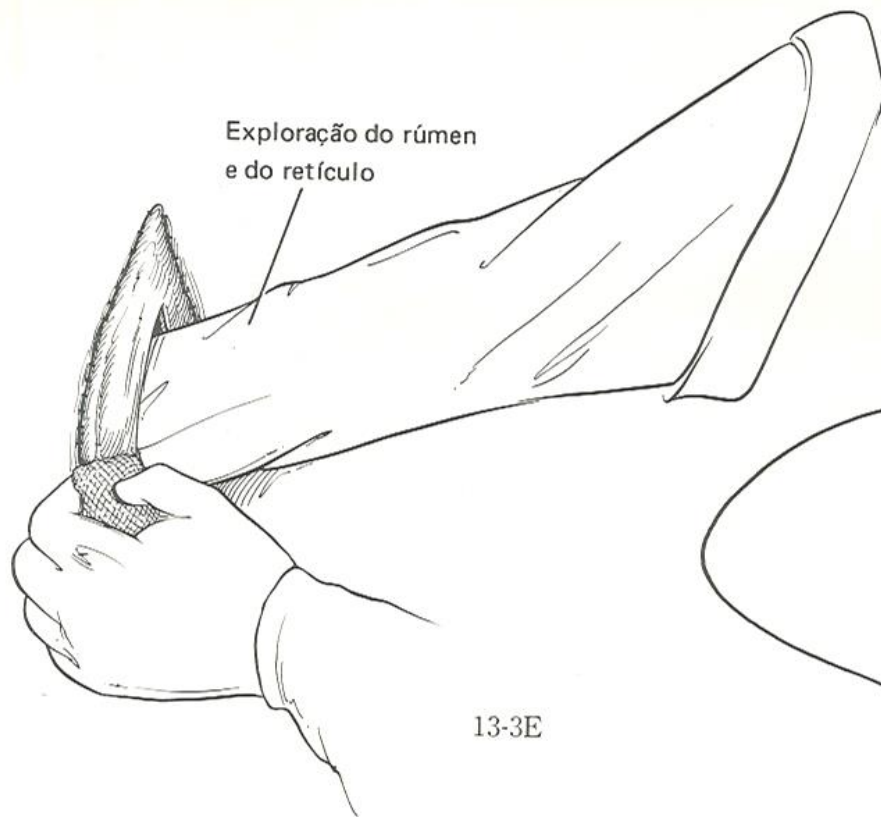
- Técnica cirúrgica:
 - exploração do rumem e retículo
 - estruturas palpáveis



Anatomia cavidade abdominal ruminantes – esquerdo





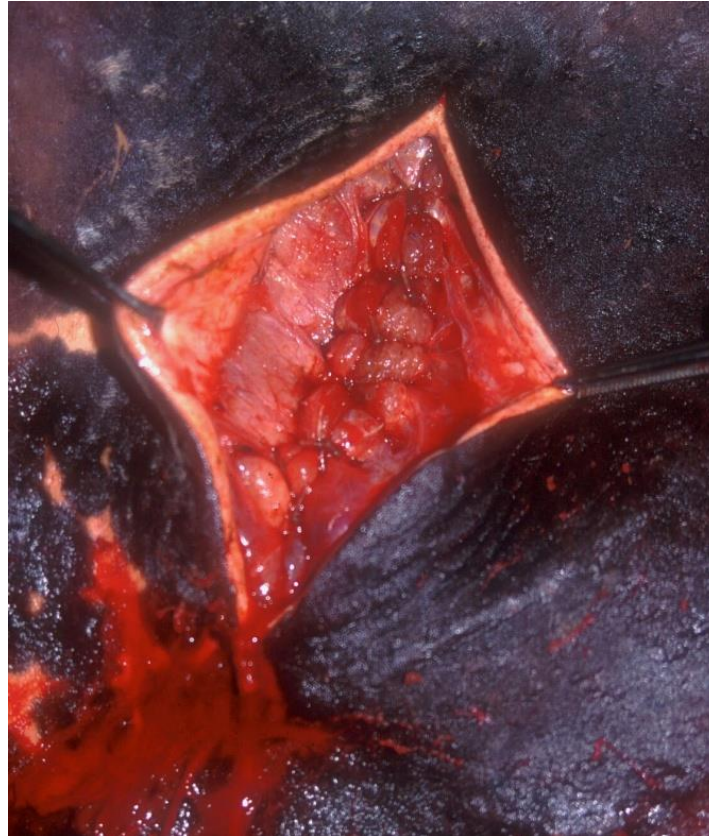

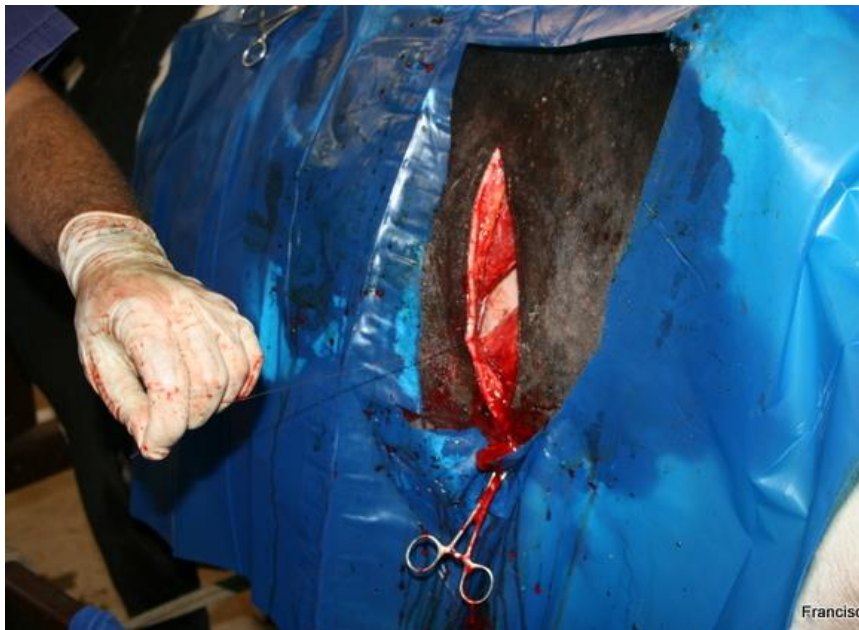Ruminotomia

- Ruminorrafia:
 - sutura em dois planos
apositional + invaginante
 - limpeza com sol. de PVP
 - desfaz sutura de ancoragem (?)

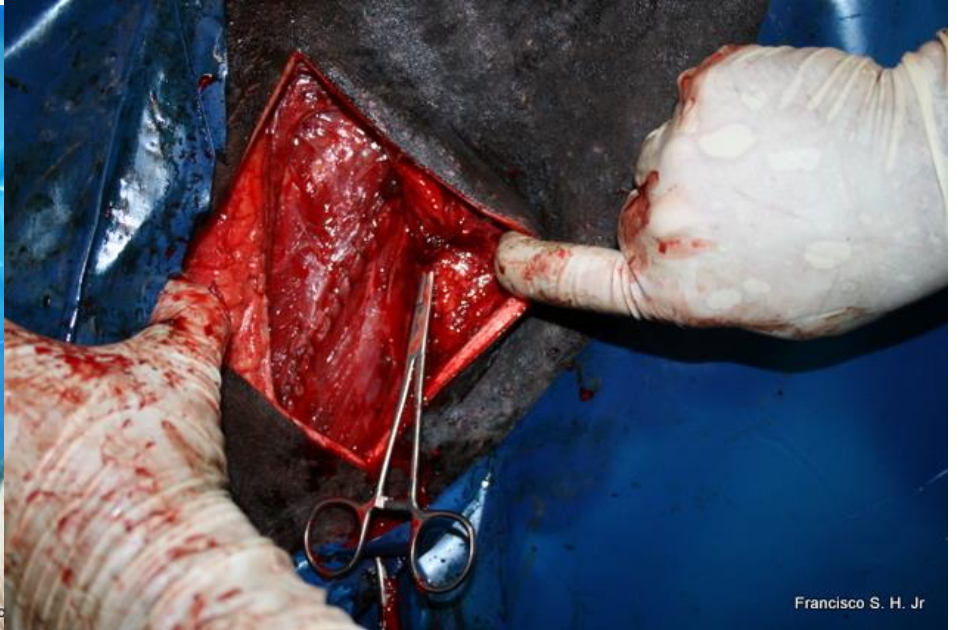Ruminotomia

- sutura dos planos musculares do flanco

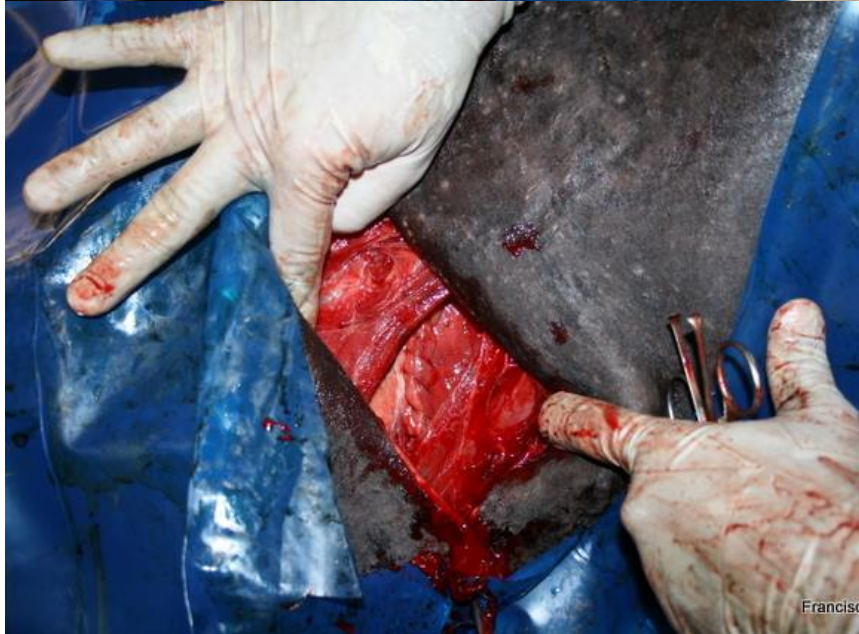




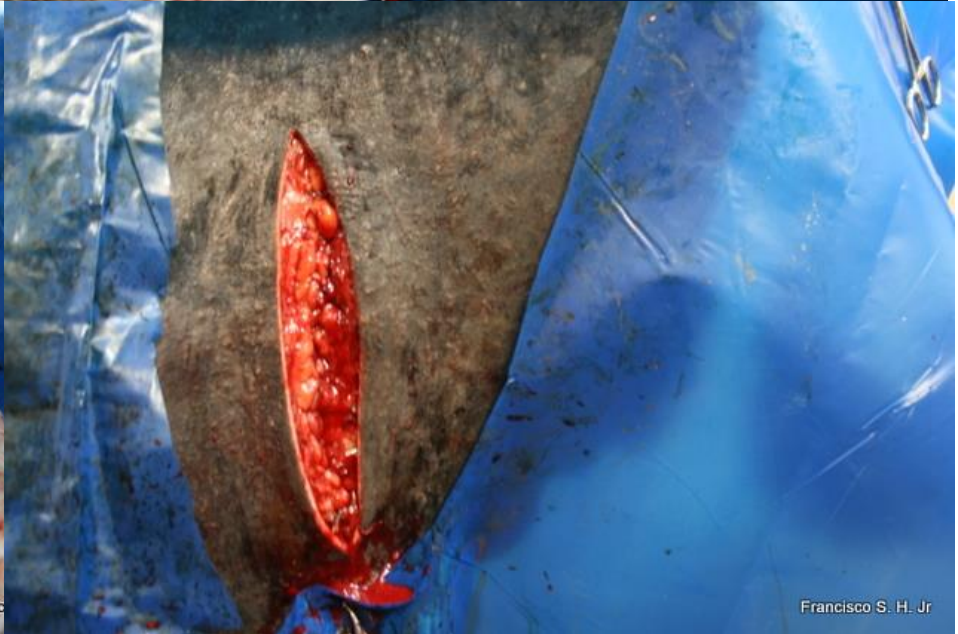
Francisco



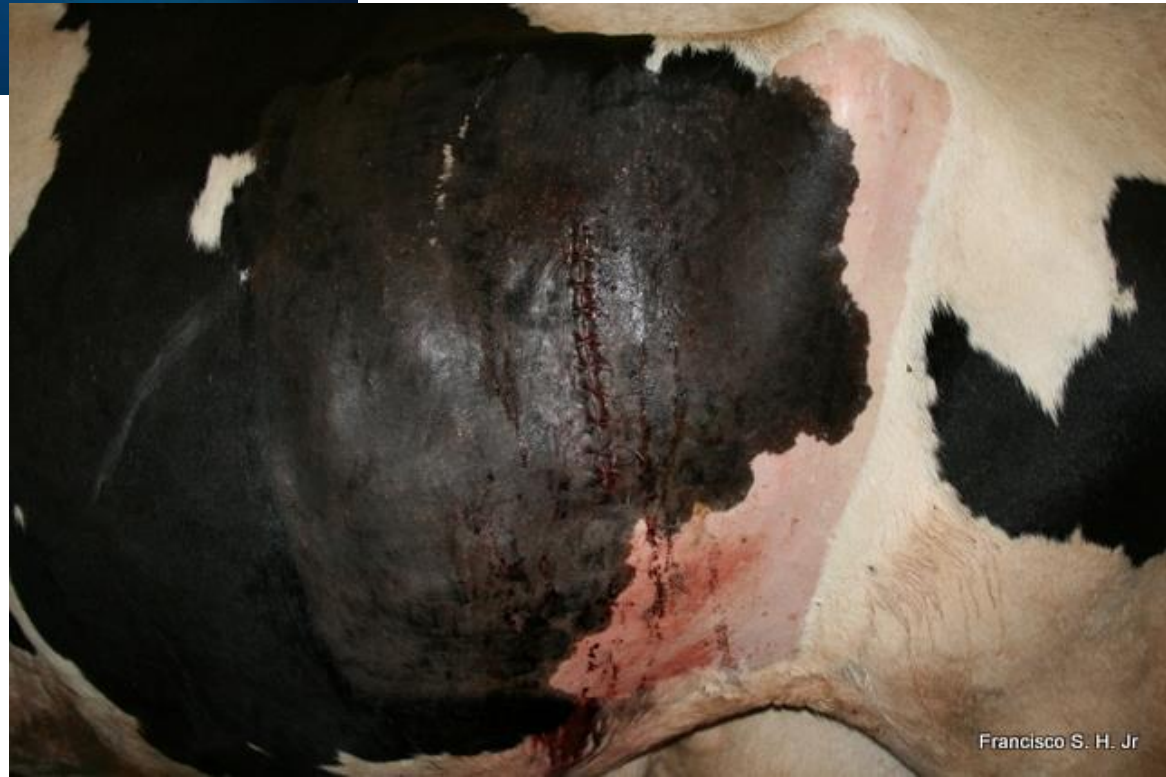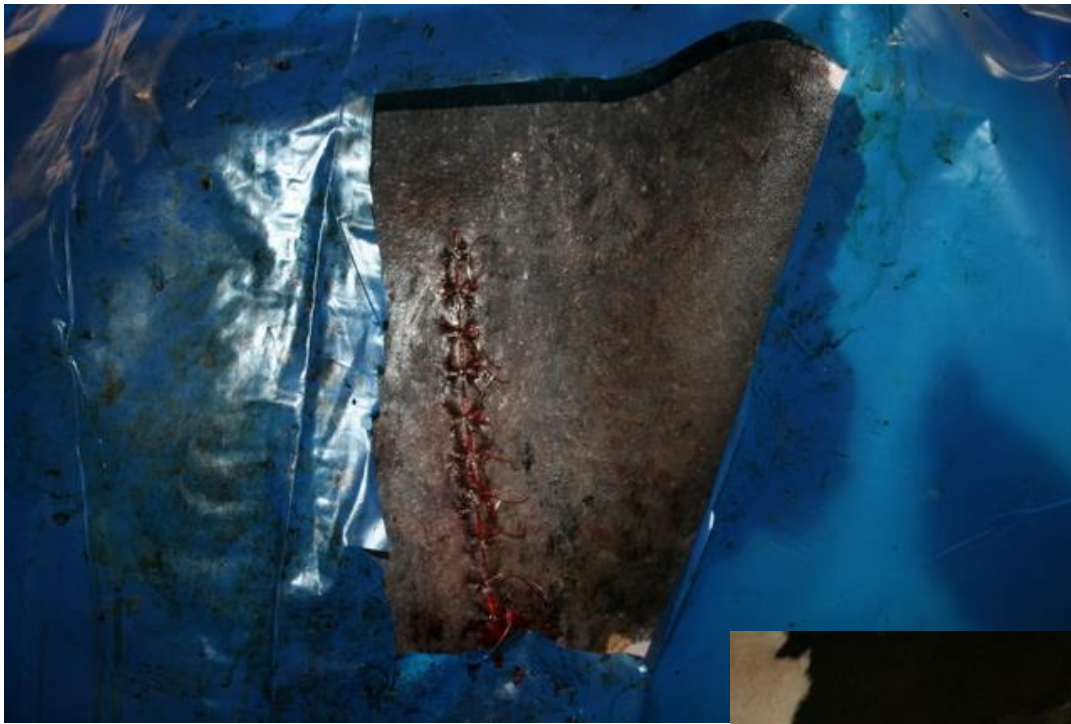Francisco S. H. Jr



Francisco

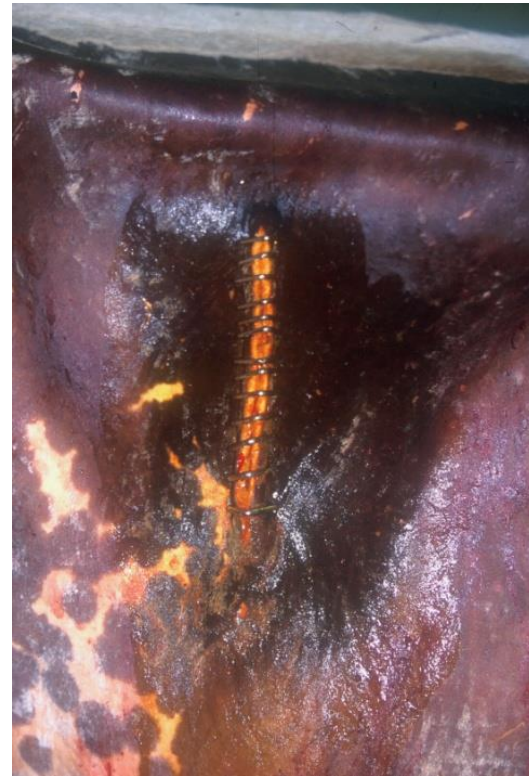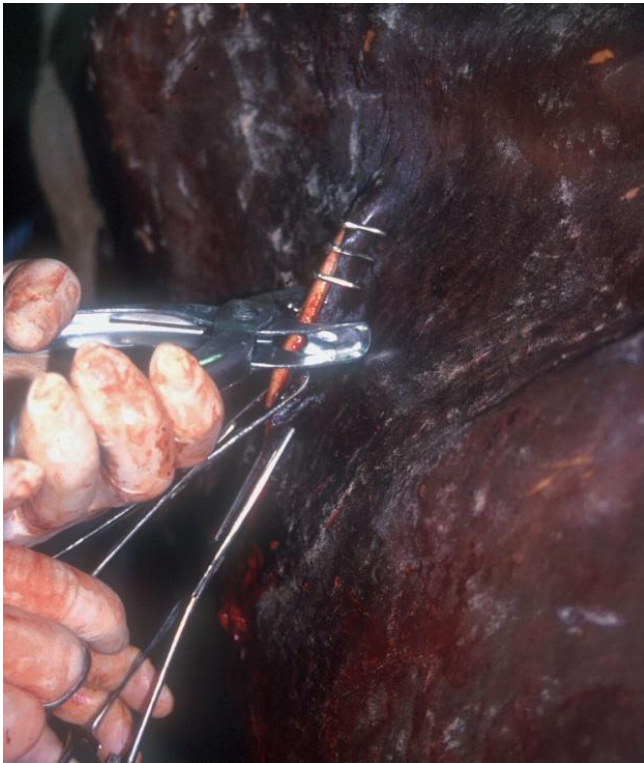


Francisco S. H. Jr



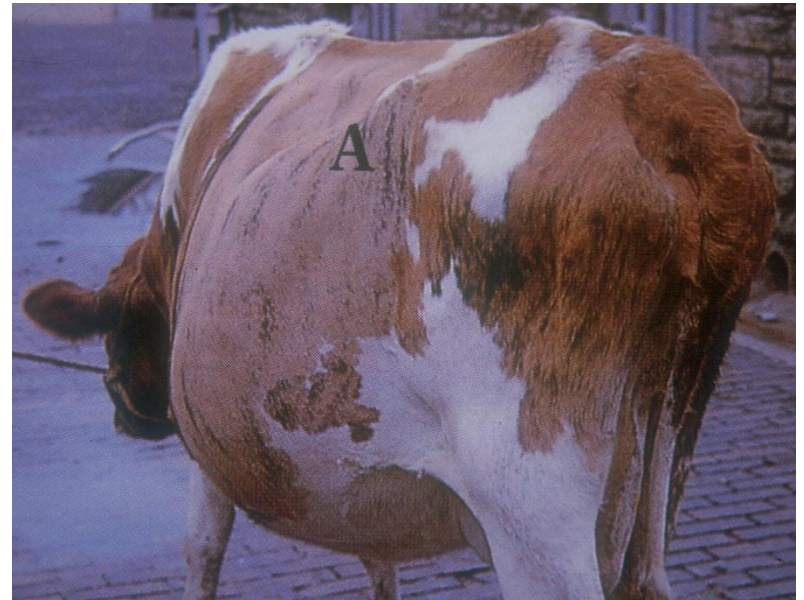Ruminotomia

- sutura do tecido subcutâneo e pele

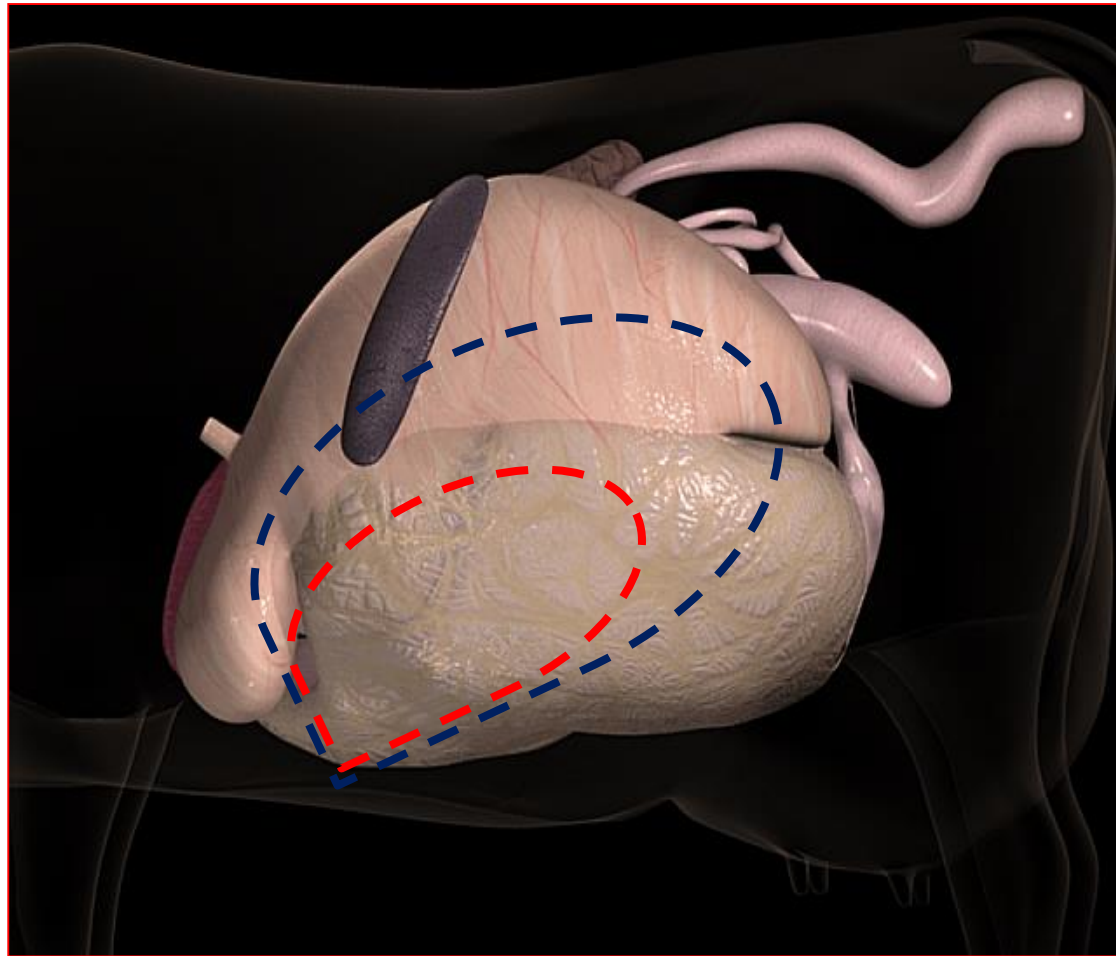


Abomasopexia

- Indicações:
 - deslocamento a esquerda
 - deslocamento a direita

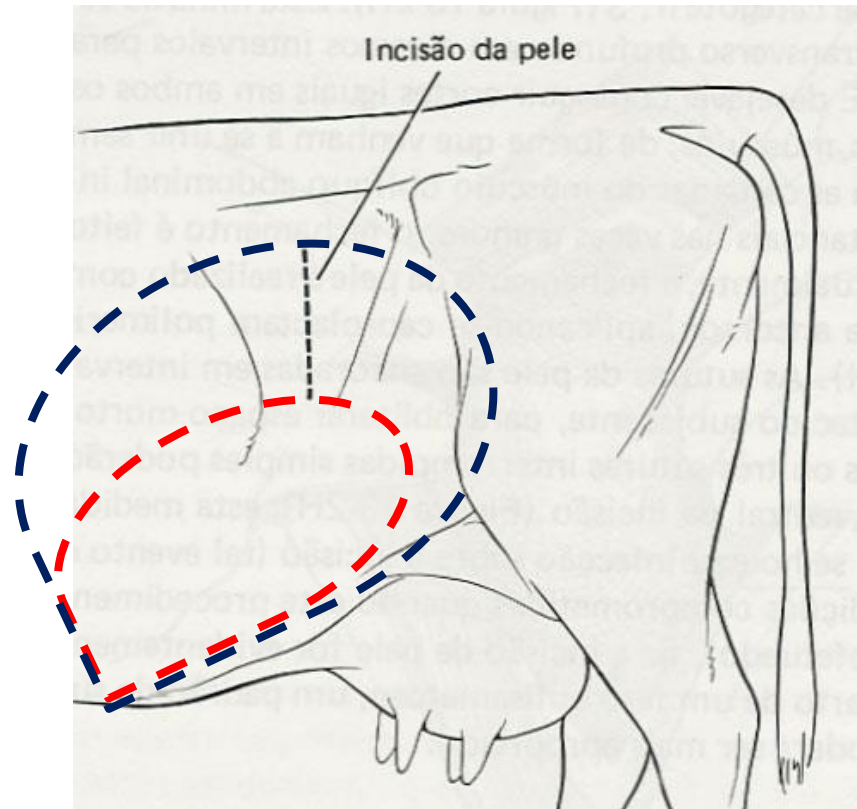


Anatomia cavidade abdominal ruminantes – esquerdo



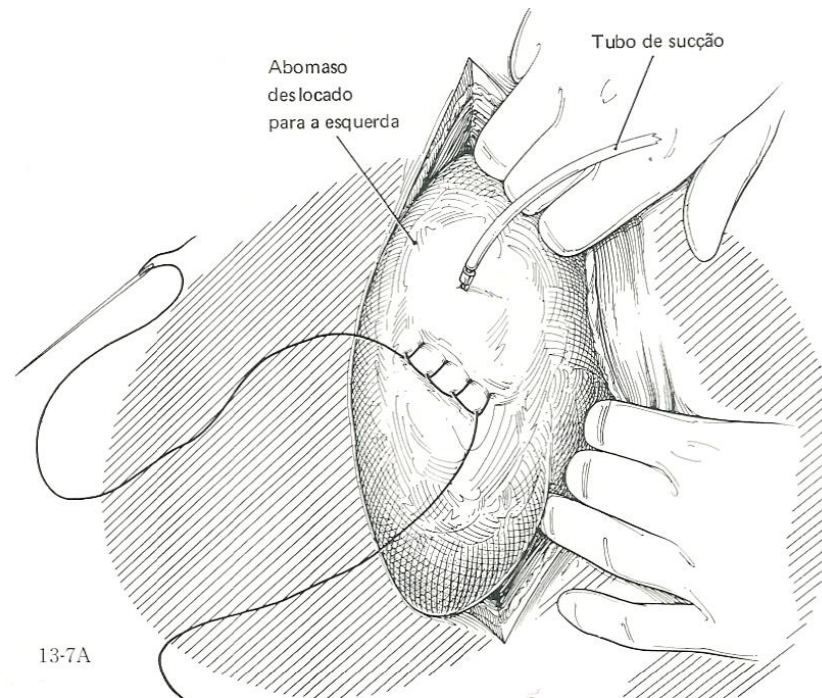
Abomasopexia – flanco esquerdo

- Técnica cirúrgica:
 - laparotomia pelo flanco - lado esquerdo
 - incisão de pele na fossa paralombar (20 cm)
 - divulsão dos três grupos musculares
 - incisão do peritônio



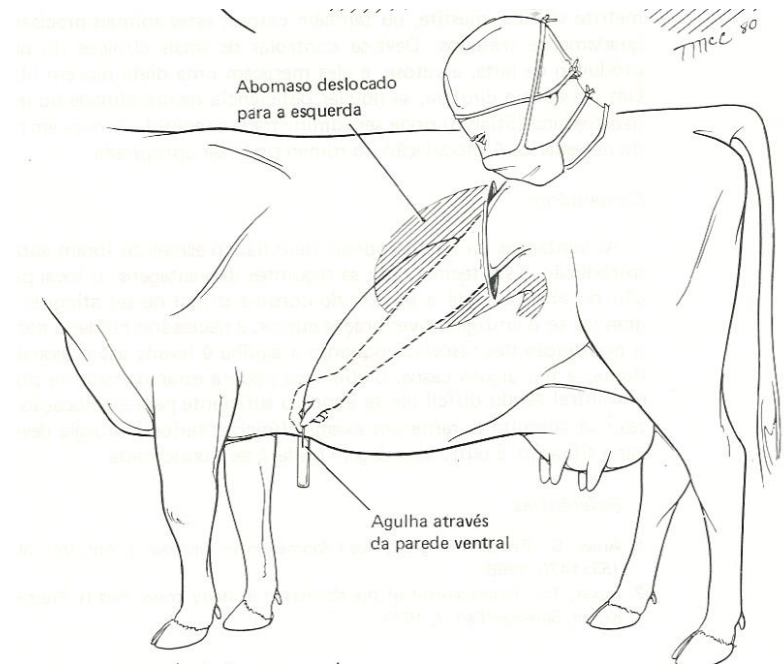
Abomasopexia

- sutura na curvatura maior do abomaso
- esvaziamento do abomaso



Abomasopexia

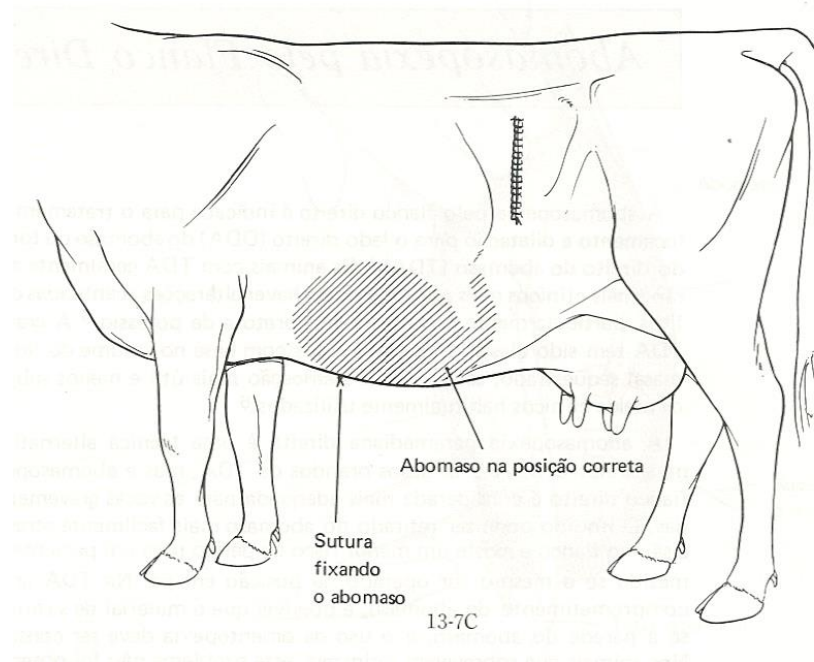
- fixação do abomaso na parede abdominal



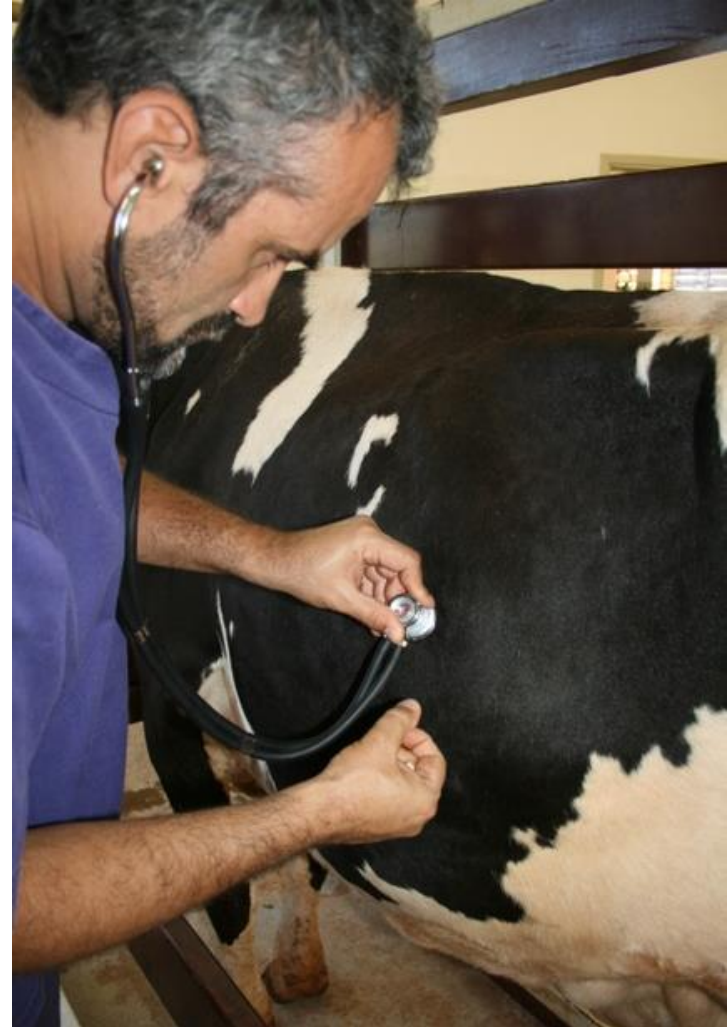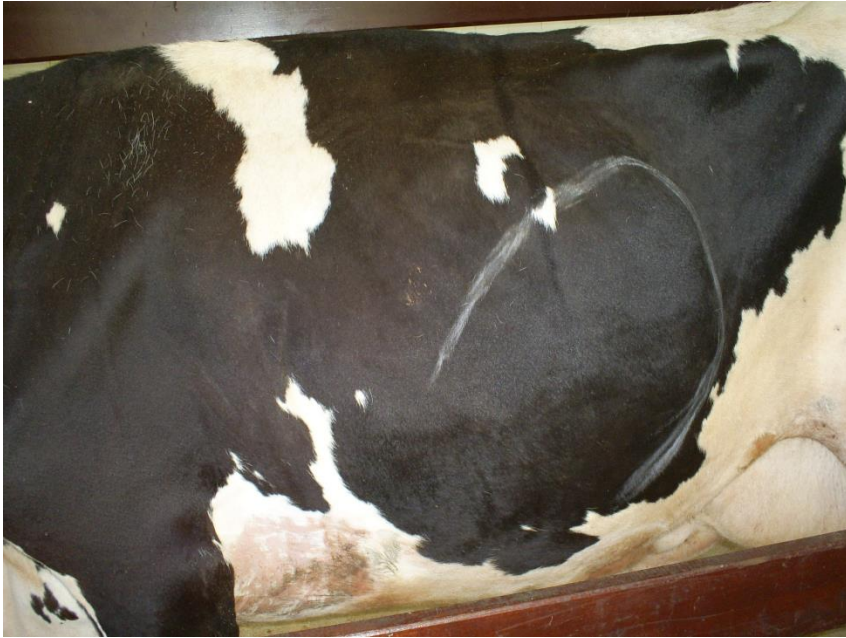Obs.: sutura mantida por 4 semanas para formação de aderências

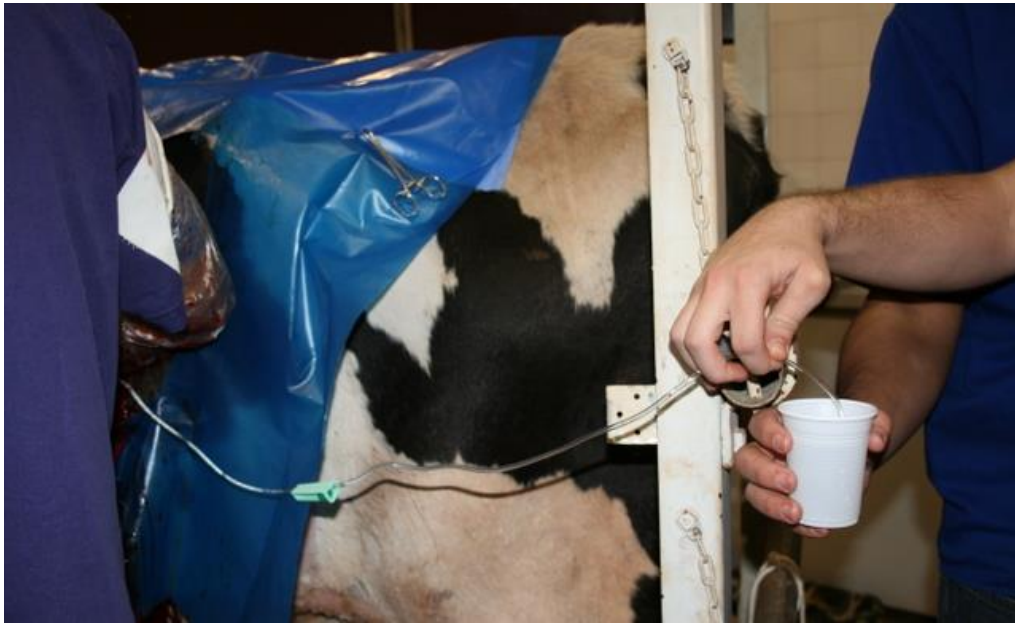Abomasopexia

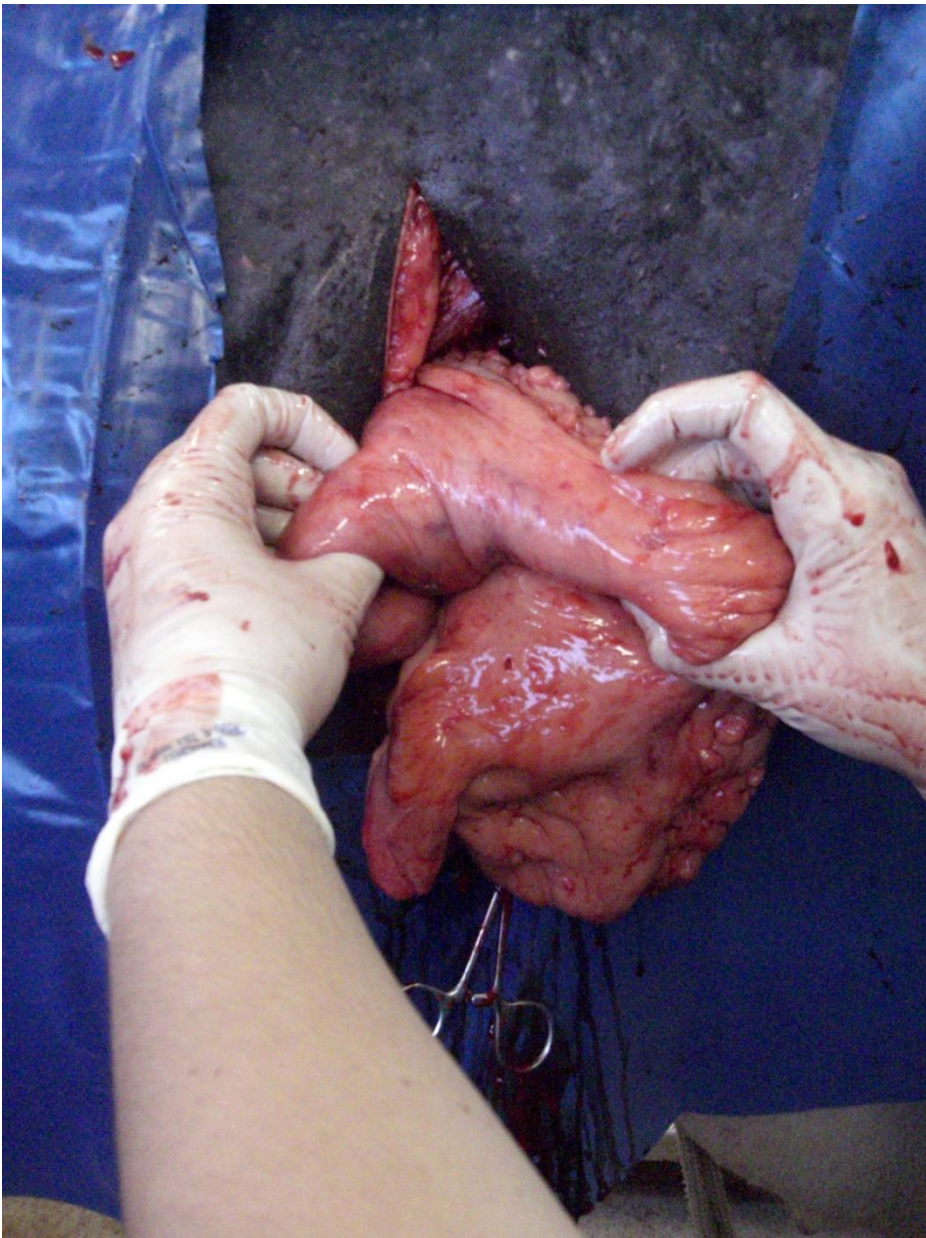
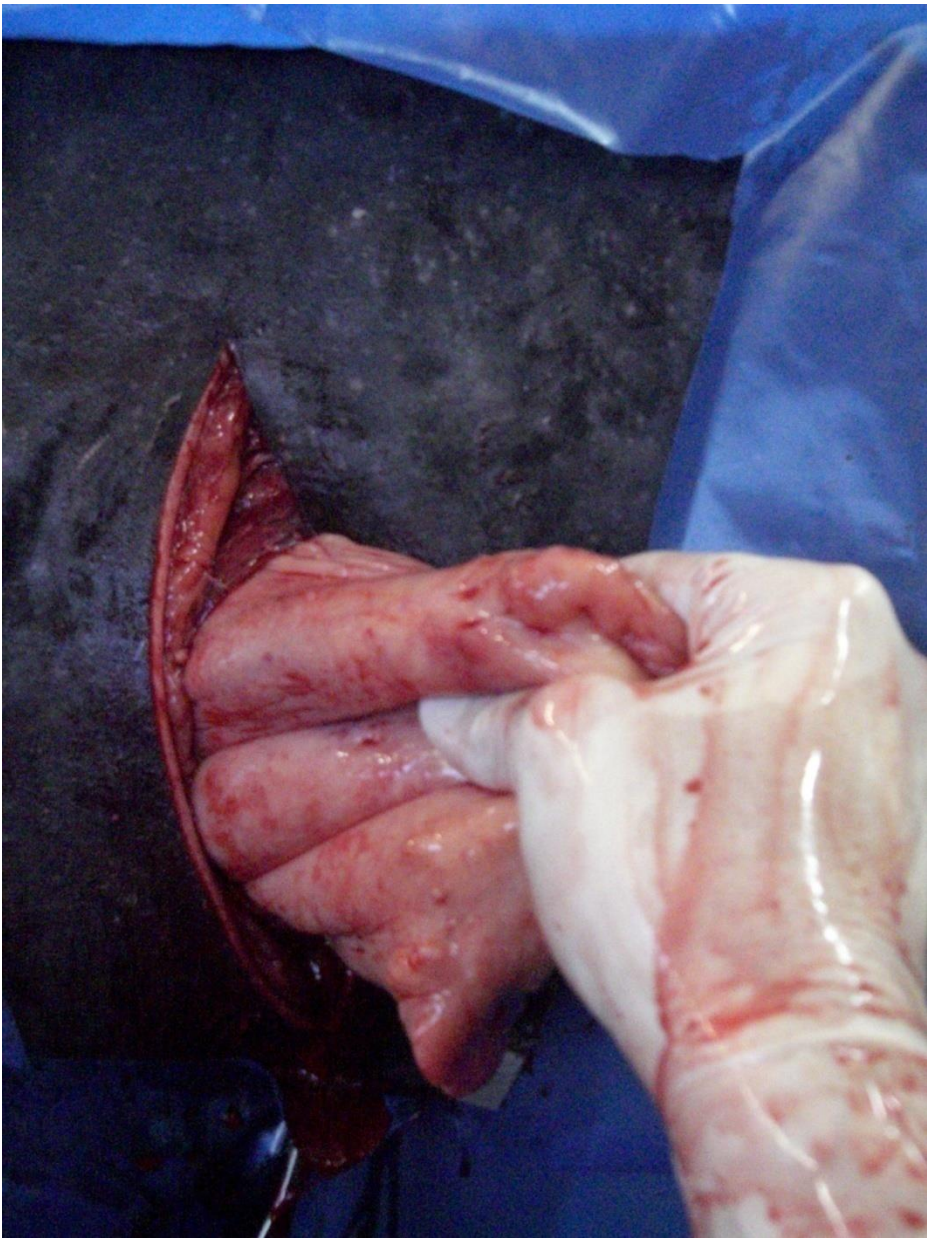- sutura de tecido subcutâneo e pele

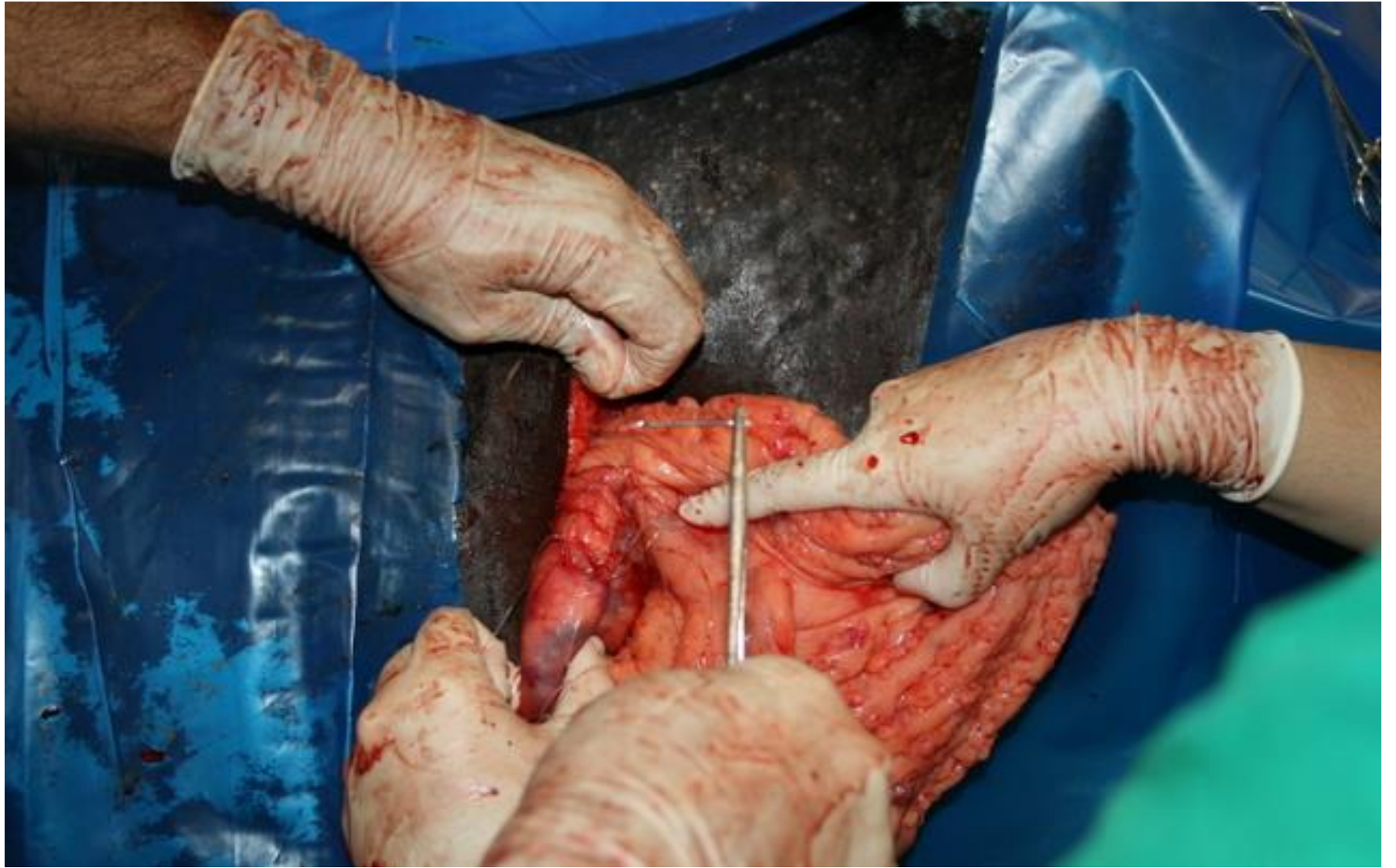

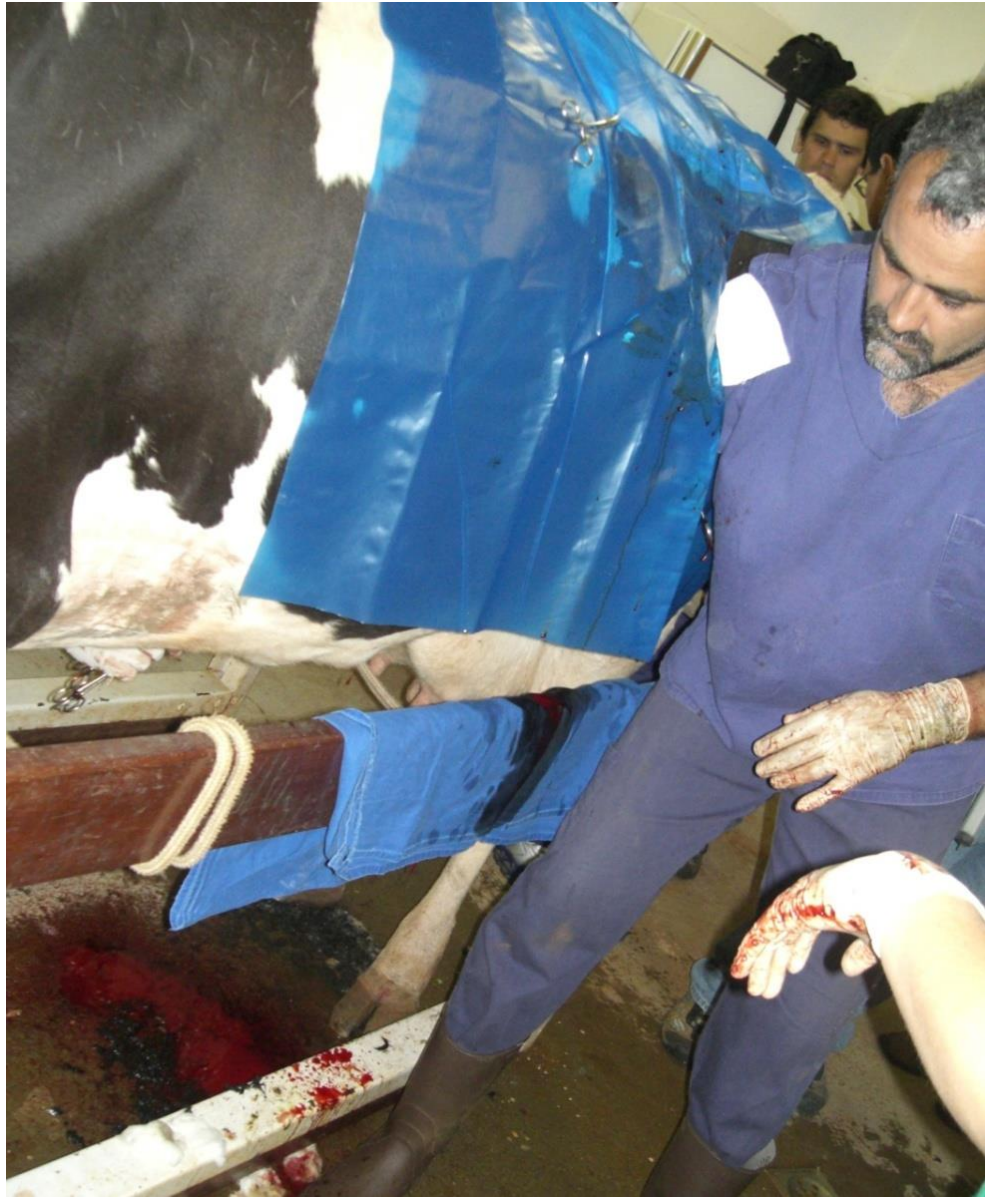Zona de som timpânico
(1/3 médio superior do
costado – 8^o ao 11^o
EIC);

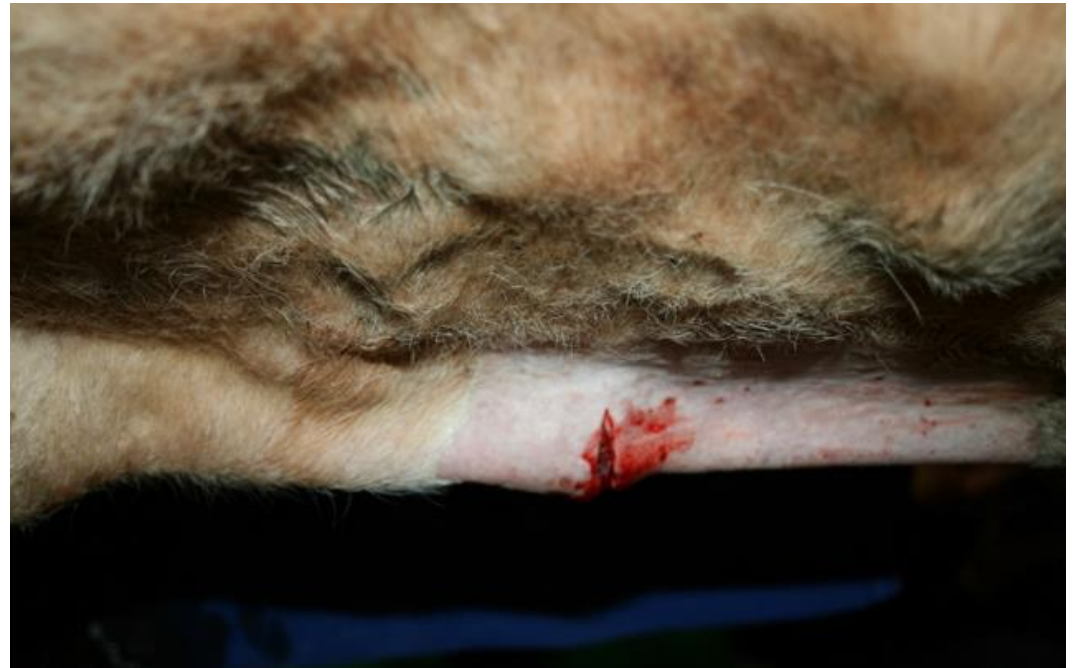
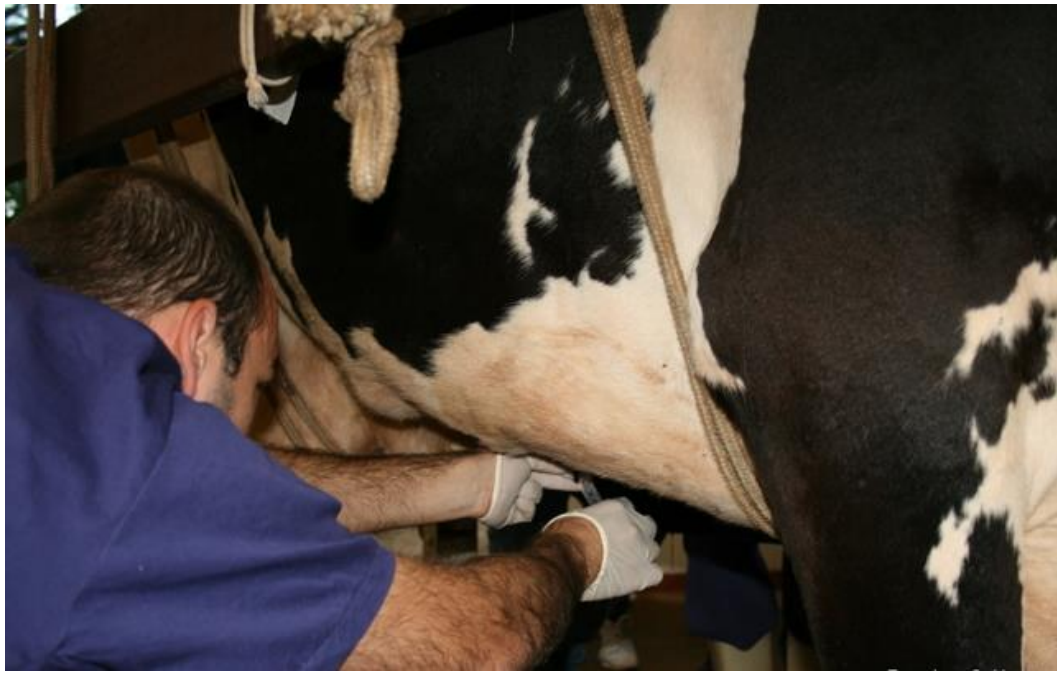


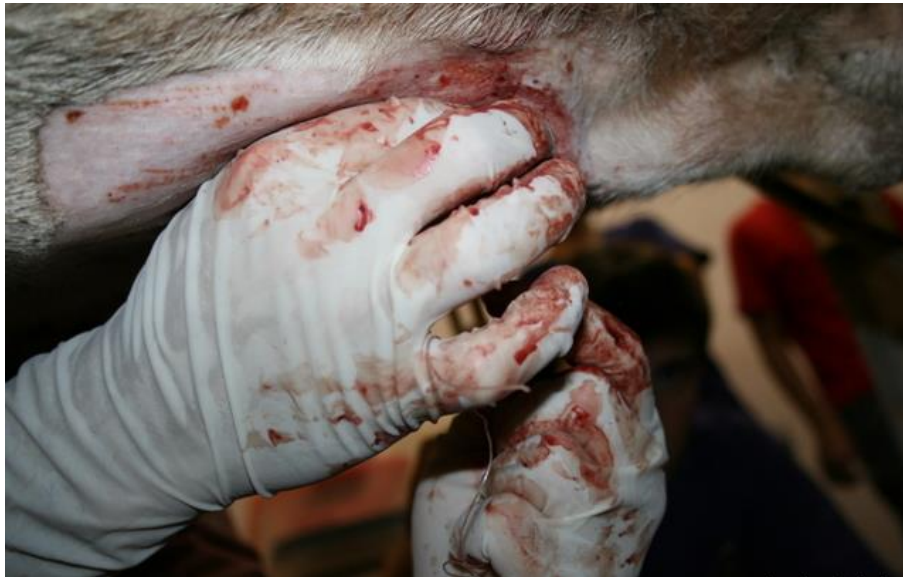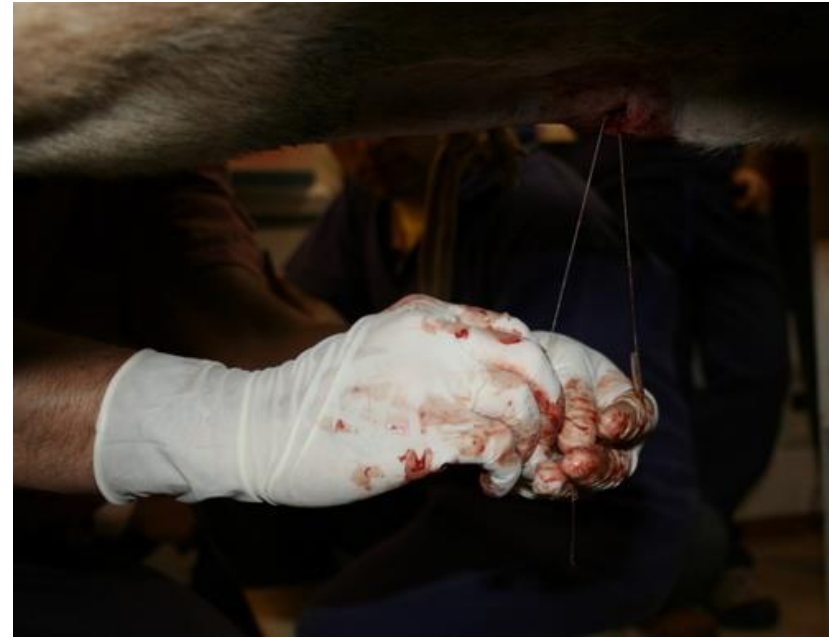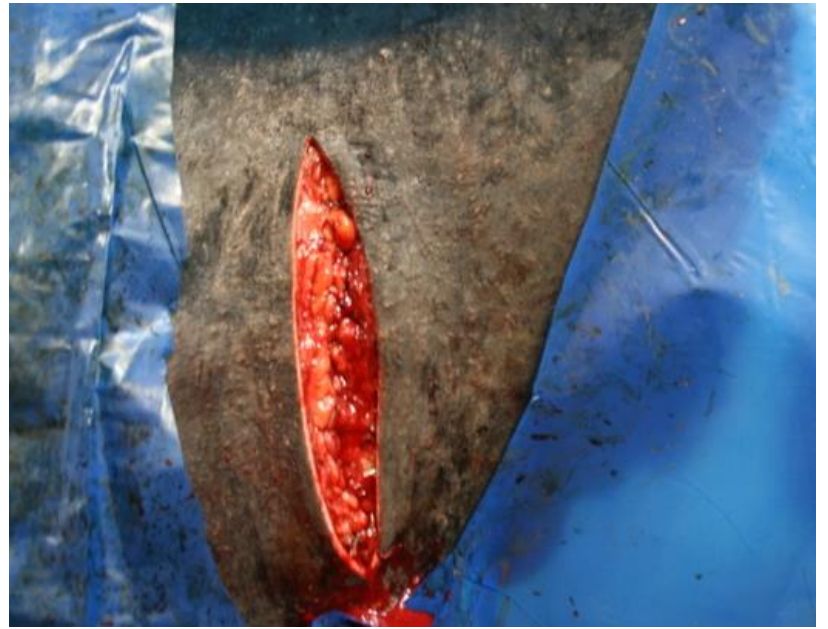




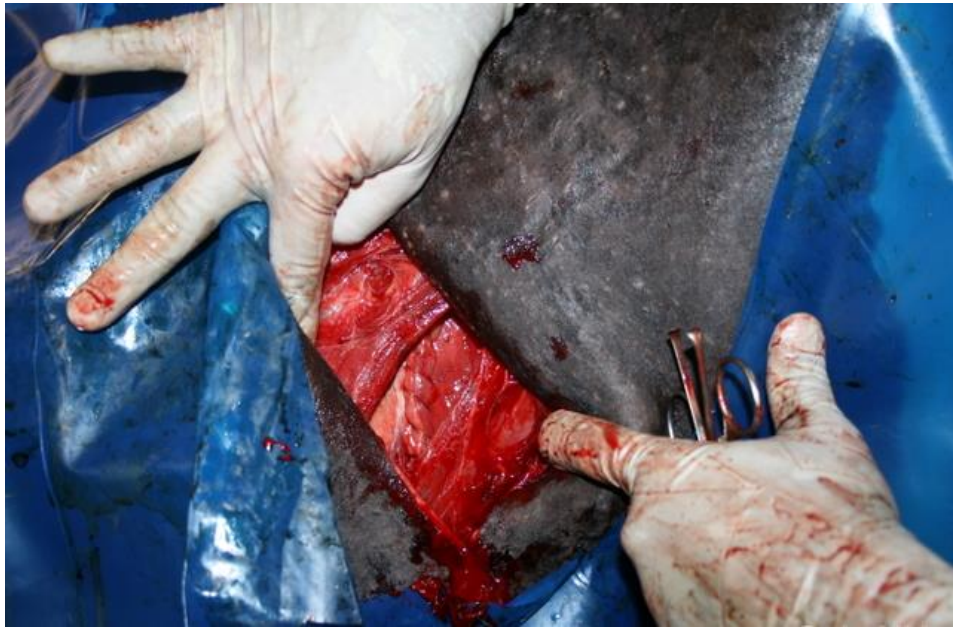
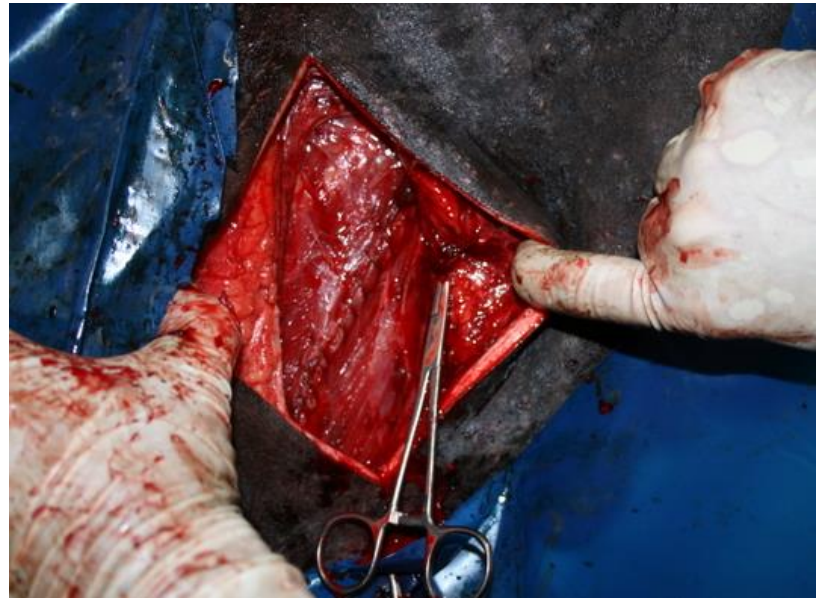
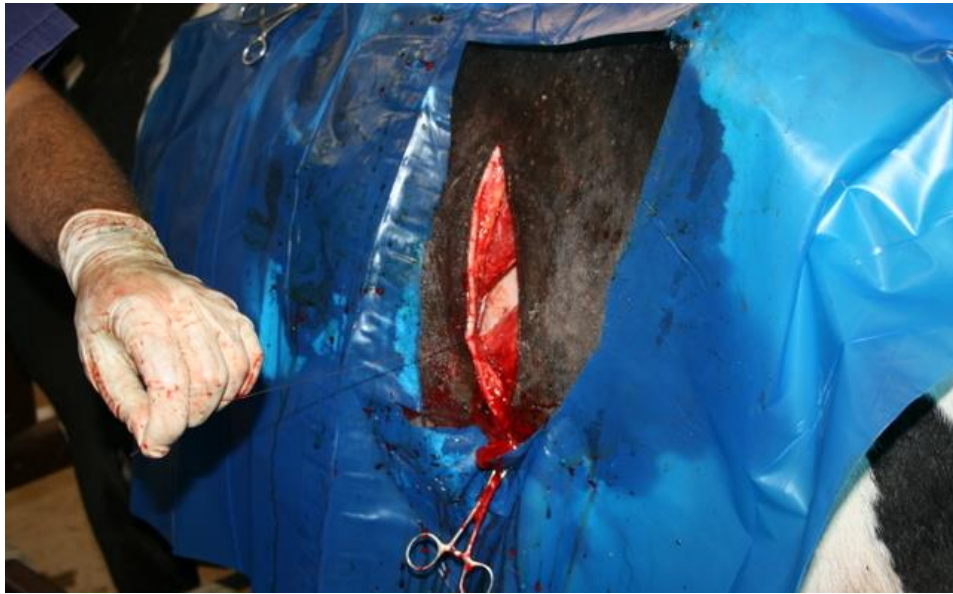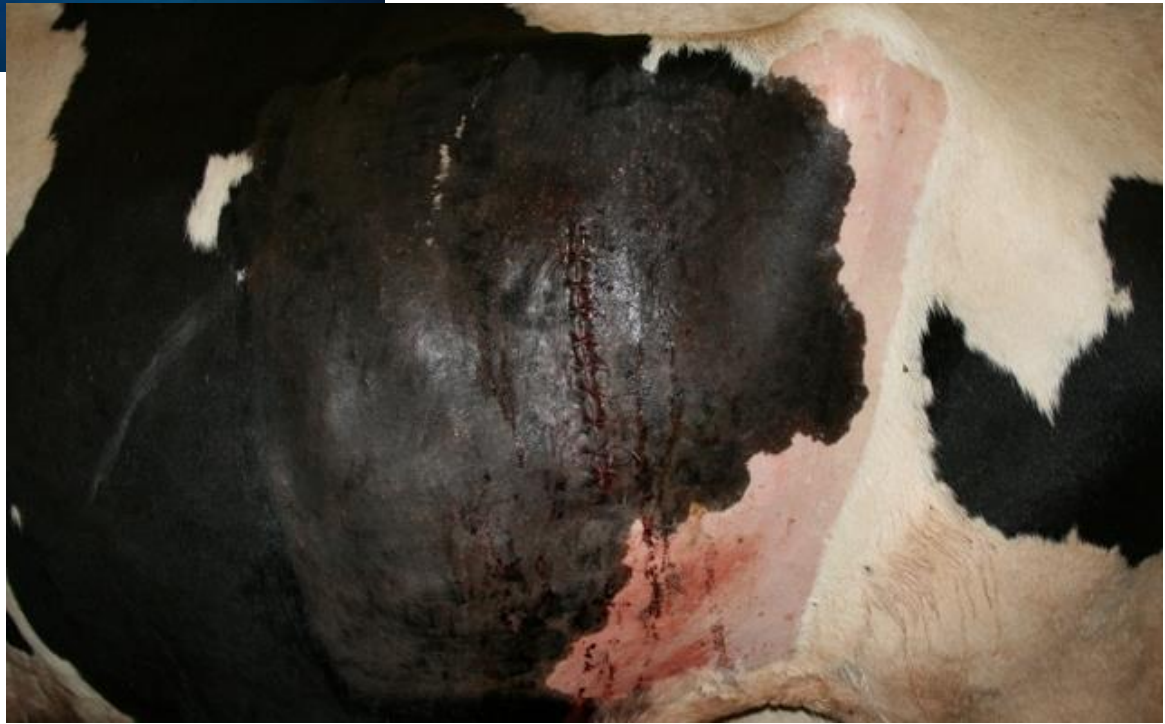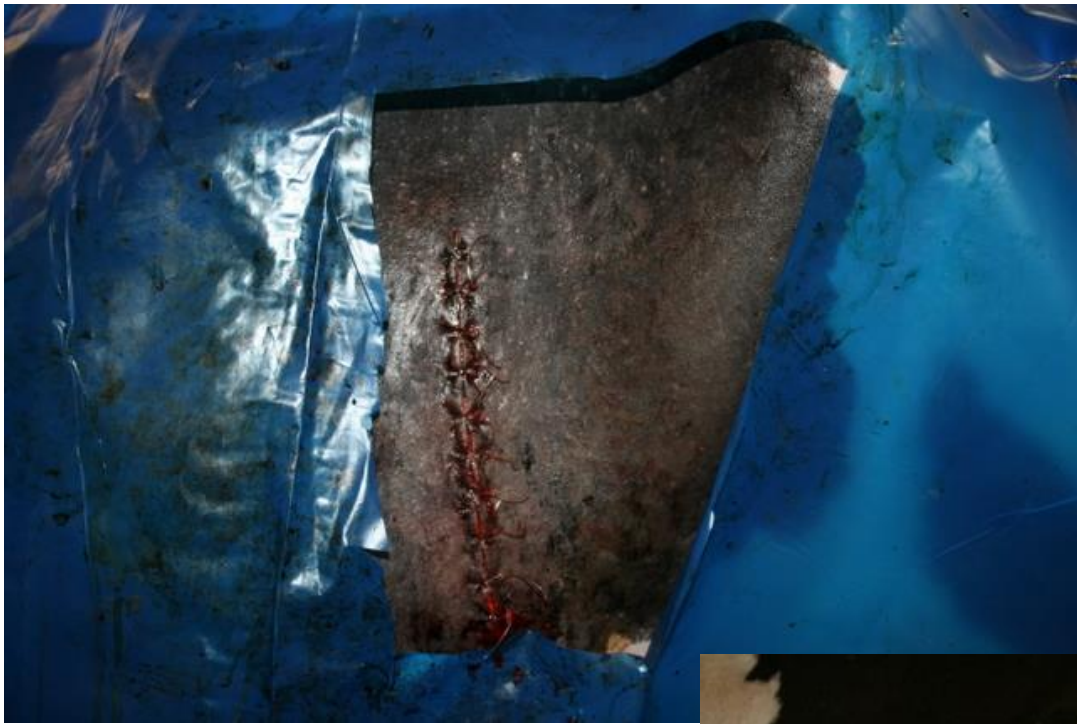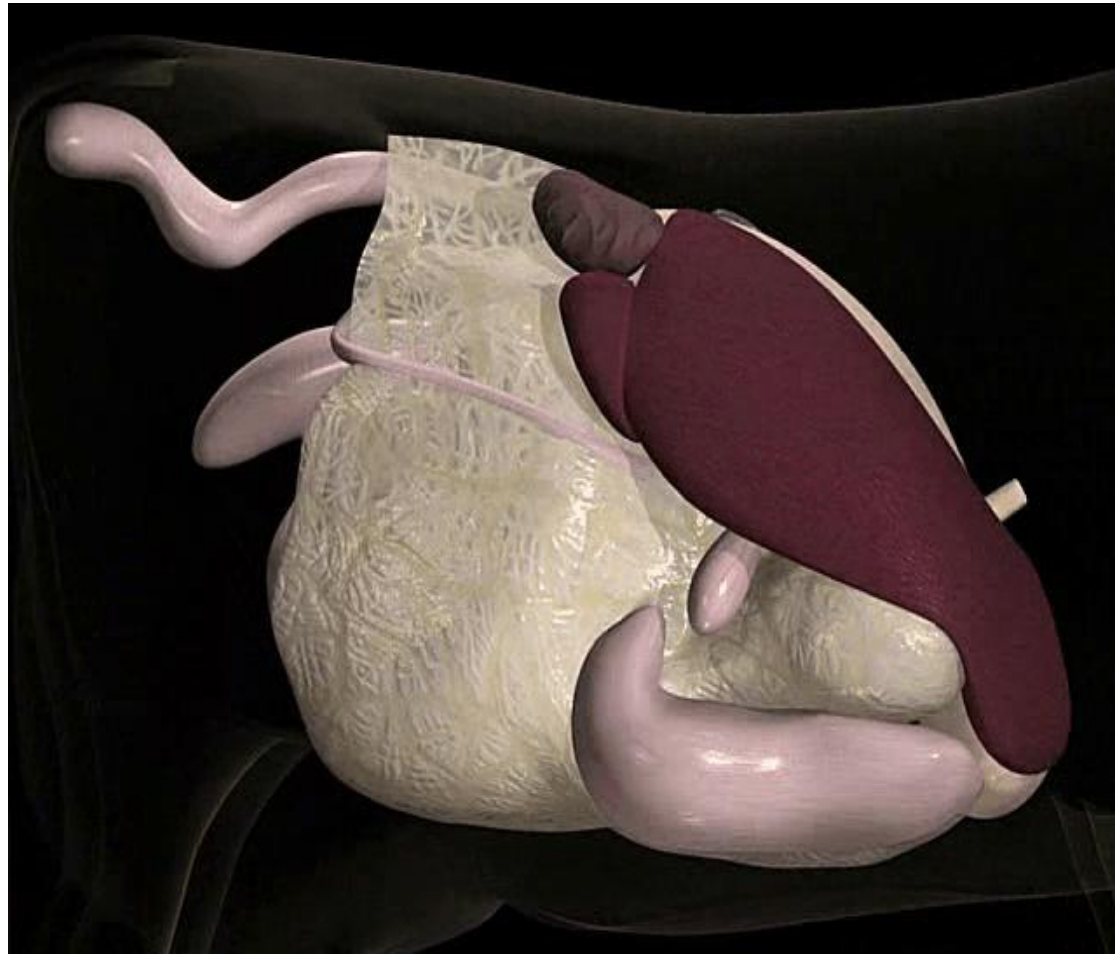








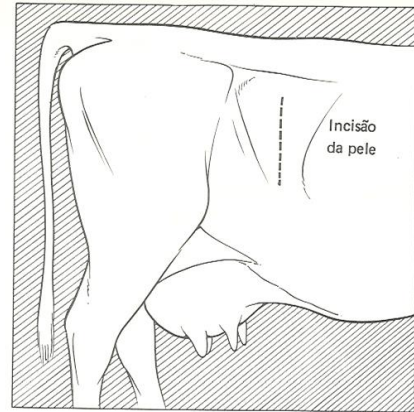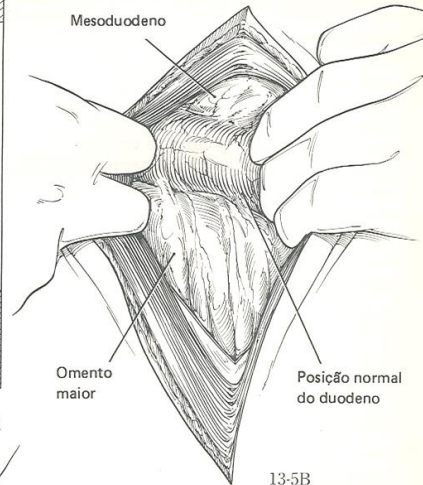
Anatomia cavidade abdominal ruminantes – direito



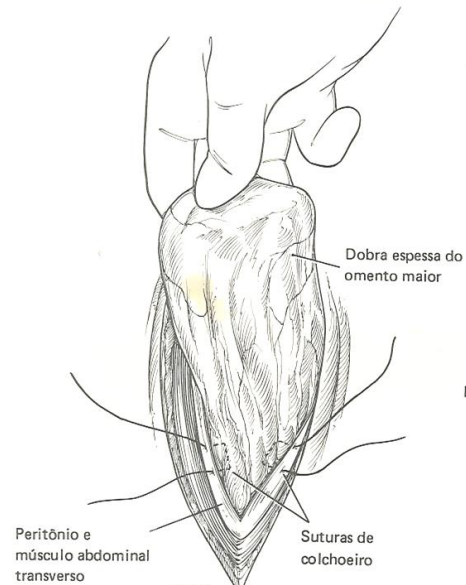
Omentopexia



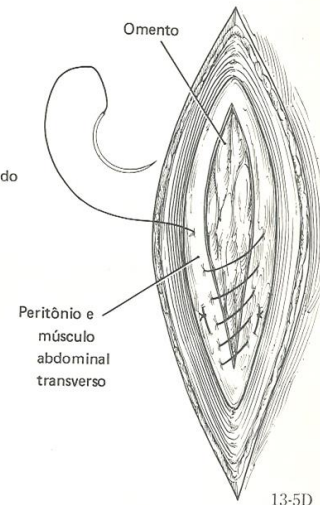
13-5A



13-5B

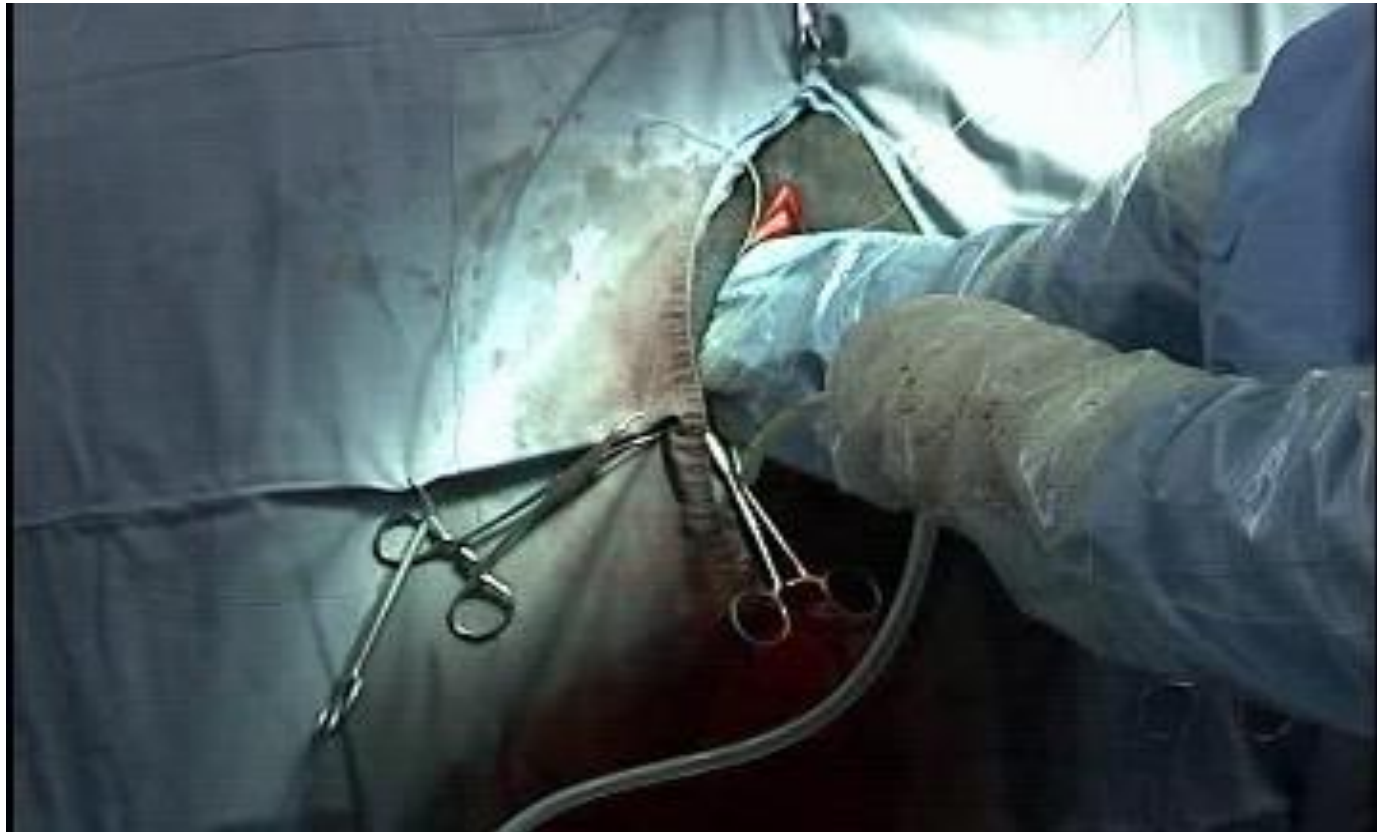

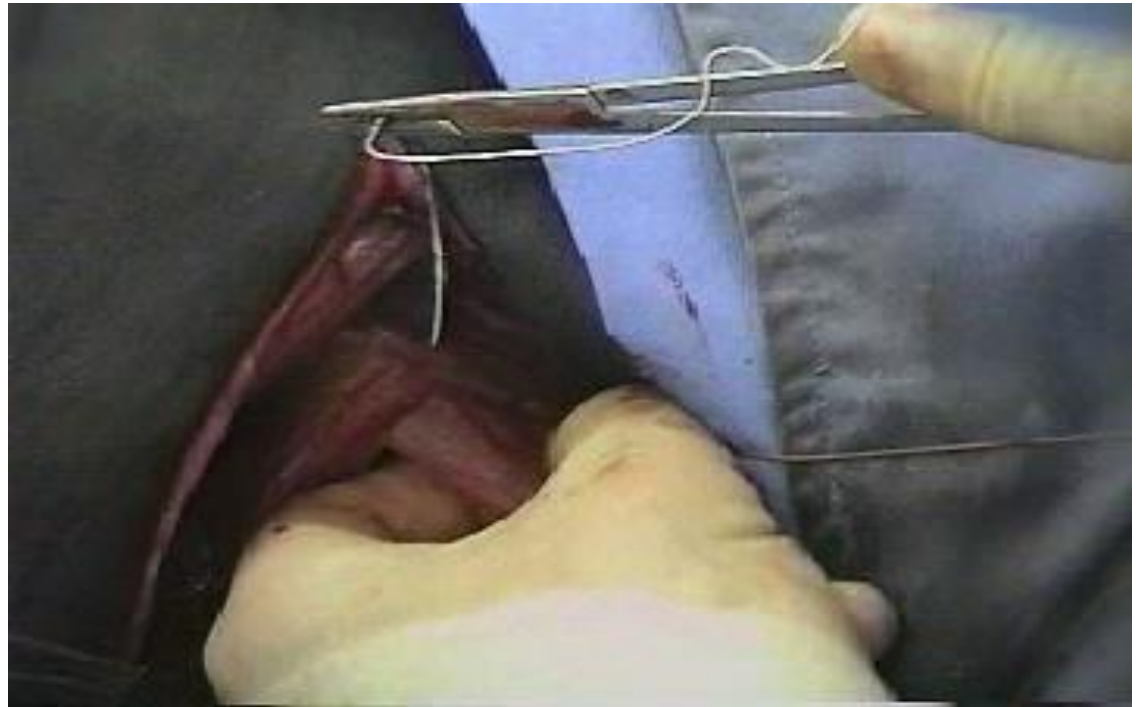
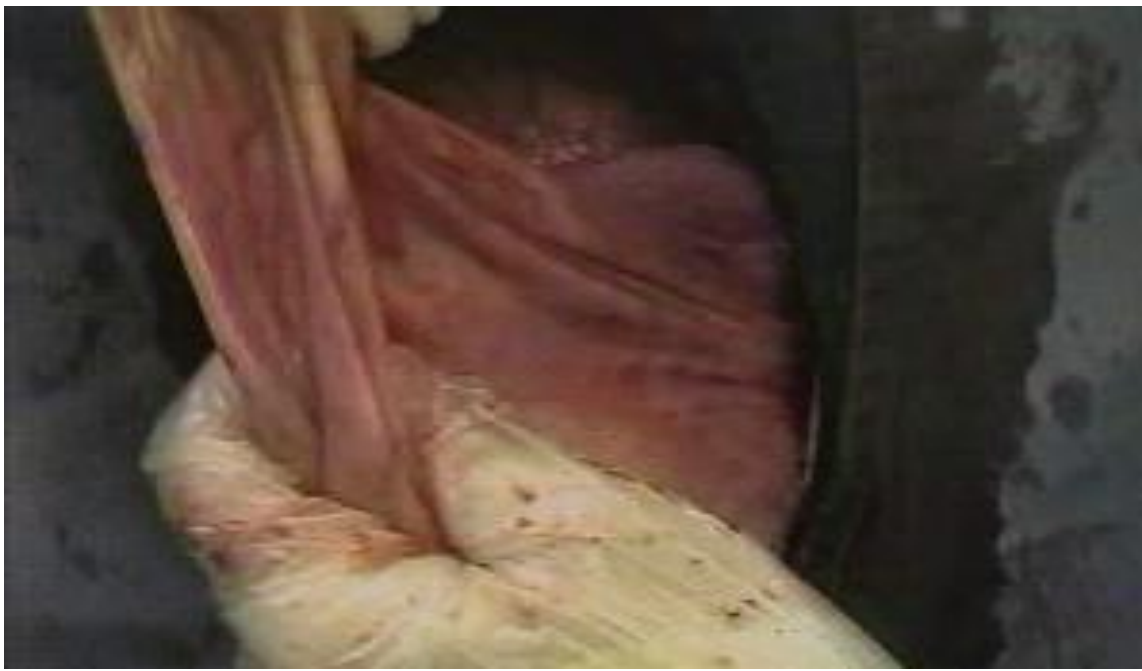13-5C



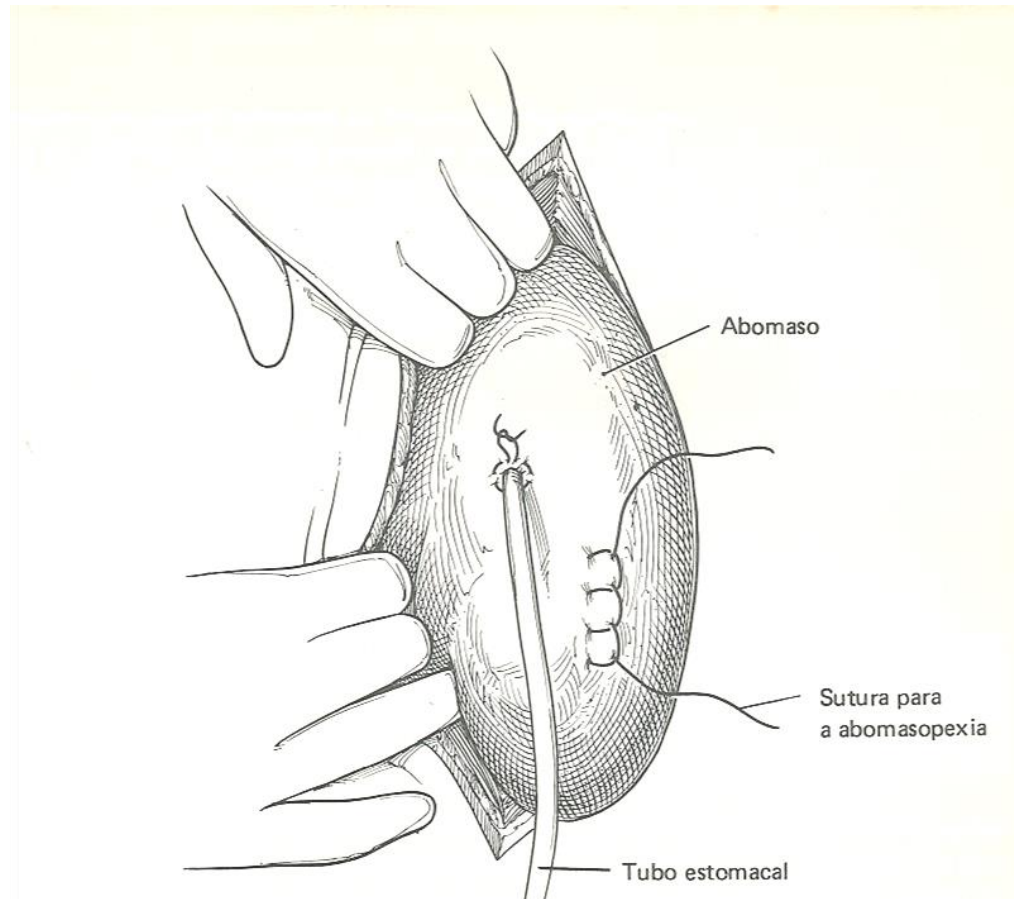
13-5D

Retirada de gás do abomaso (paralombar)





Abomasopexia direita



REFERÊNCIAS

- ADAMS, S. B.; FESSLER, J. F. Atlas of Equine Surgery. W. B. Saunders Company, Philadelphia, 2000, 428 p.
- AMSTUTZ, H. E. Bovine Medicine and Surgery. 2ª ed., Sta Barbara: American Veterinary Publication, 1980, 647 p.
- ASHDOWN, R.R.; DONE, S.H. Atlas Colorido de Anatomia Veterinária – Volume II – O Cavalo. Ed. Manole Ltda, São Paulo, 1989, 8.52p.
- AUER, J. A. Equine surgery, W.B. Saunders Co, Philadelphia, 1992, 1214 p.
- AUER, J.A; STICK, J.A. Equine Surgery. Ed. W.B. Saunders Co., 2 ed., Philadelphia, 937 p., 1999.
- BLOWEY, R.W.; WEAVER, A.D. A colour atlas of diseases and disorders of cattle. Ed. Wolfe Pub. Lim. Aylesbury, 223p., 1991.
- BUDRAS, K.; SACK, W.O.; RÖCK, S. Anatomy of the Horse. Mosby-Wolf, London, 1994, 135p.
- McILWRAITH, C.W.; TURNER, A.S. Técnicas cirúrgicas em animais de grande porte. Livraria Roca Ltda., São Paulo, 1985, 341 p.
- McILWRAITH, C.W.; TURNER, A.S. Equine Surgery Advanced Techniques, Lea & Febiger, Philadelphia, 1987, 391 p.
- REBHUN, W.C. Diseases of Dairy Cattle, Williams & Wilkins, Media, 1995, 530 p.
- WHITE II, N.A.; MOORE, J.N. Current Practice of Equine Surgery. Ed. J.B. Lippincott Co., Philadelphia, 763 p., 1990.