Cestóides

Silvia R. B. Uliana

Departamento de Parasitologia

ICB-USP

EUKARYOTA

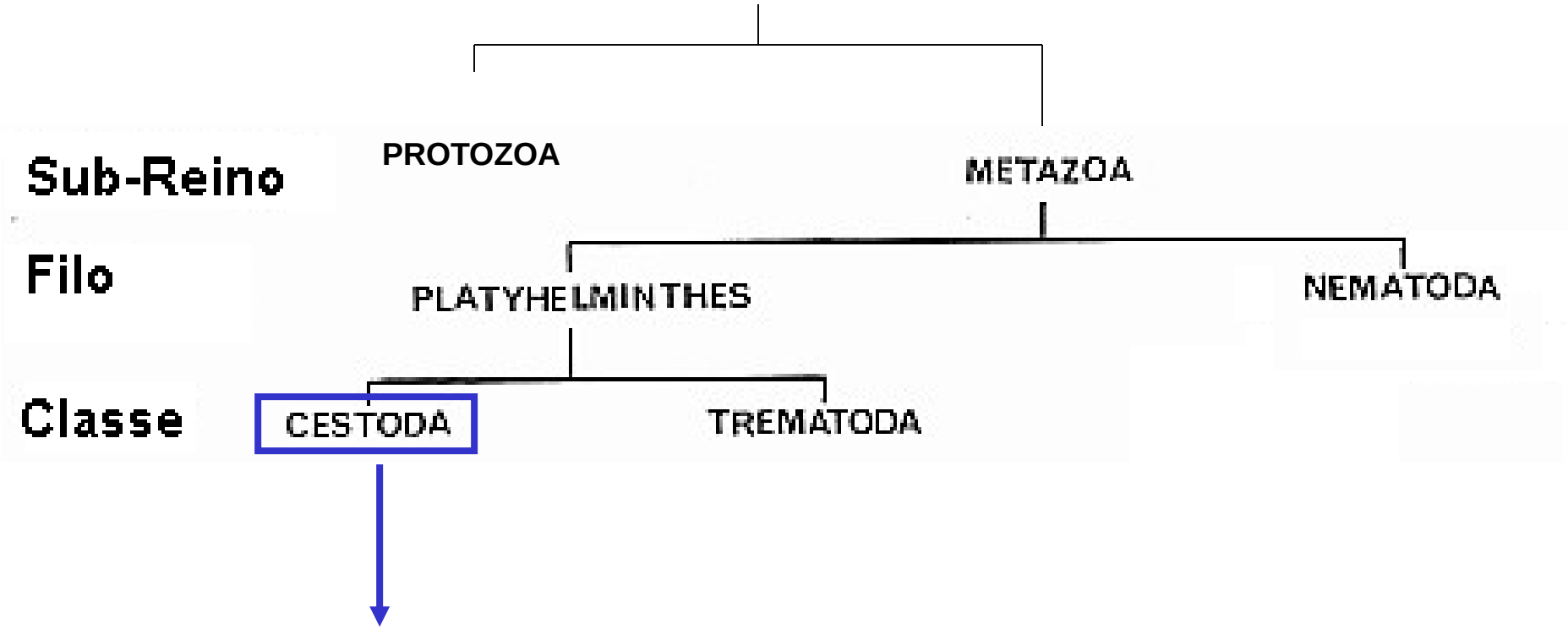

Teníase e Cisticercose

Hidatidose

Himenolepíase

Difilobotríase

CICLO DE VIDA DE UM CESTÓIDE

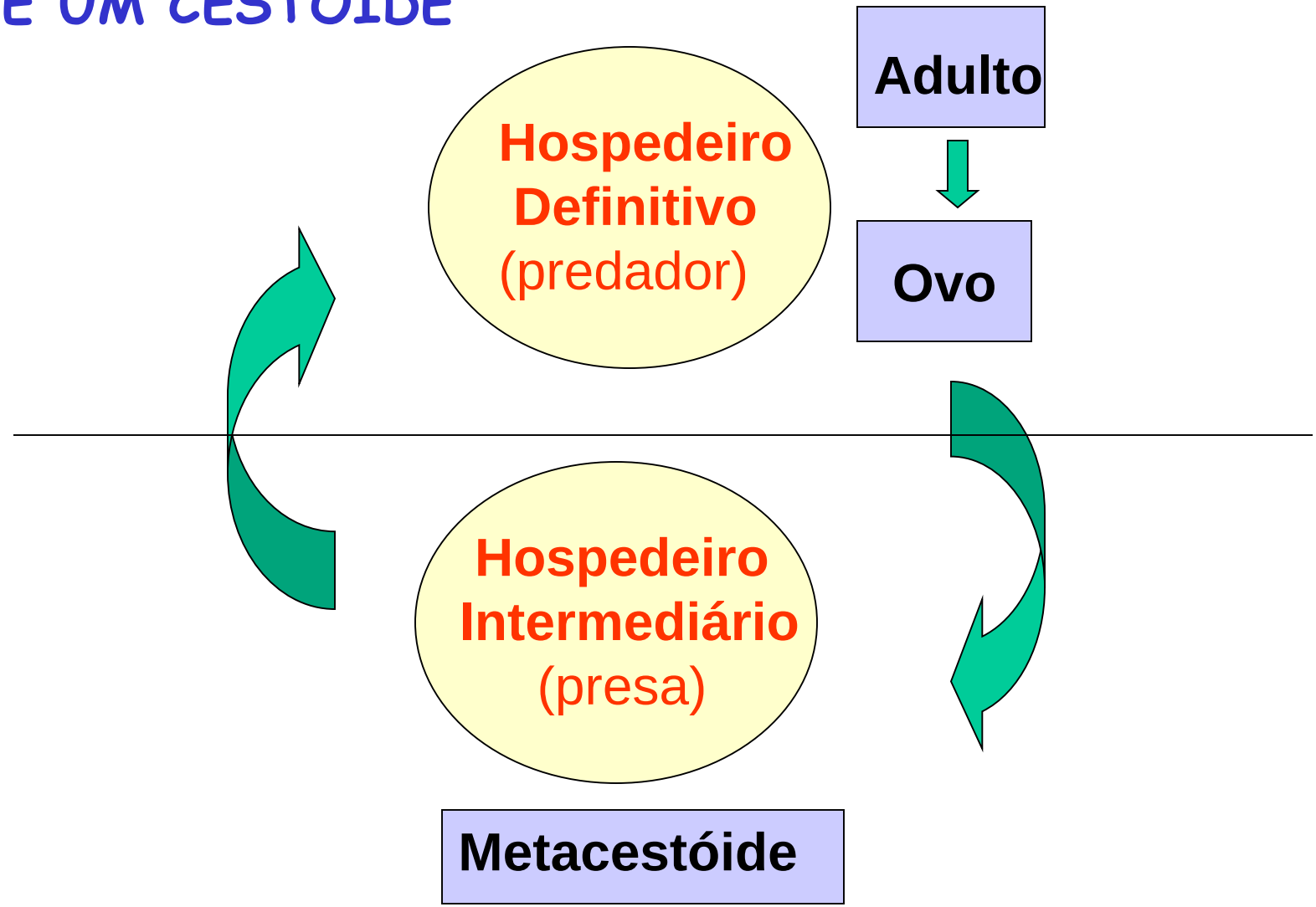

Aspecto geral de um cestóide adulto

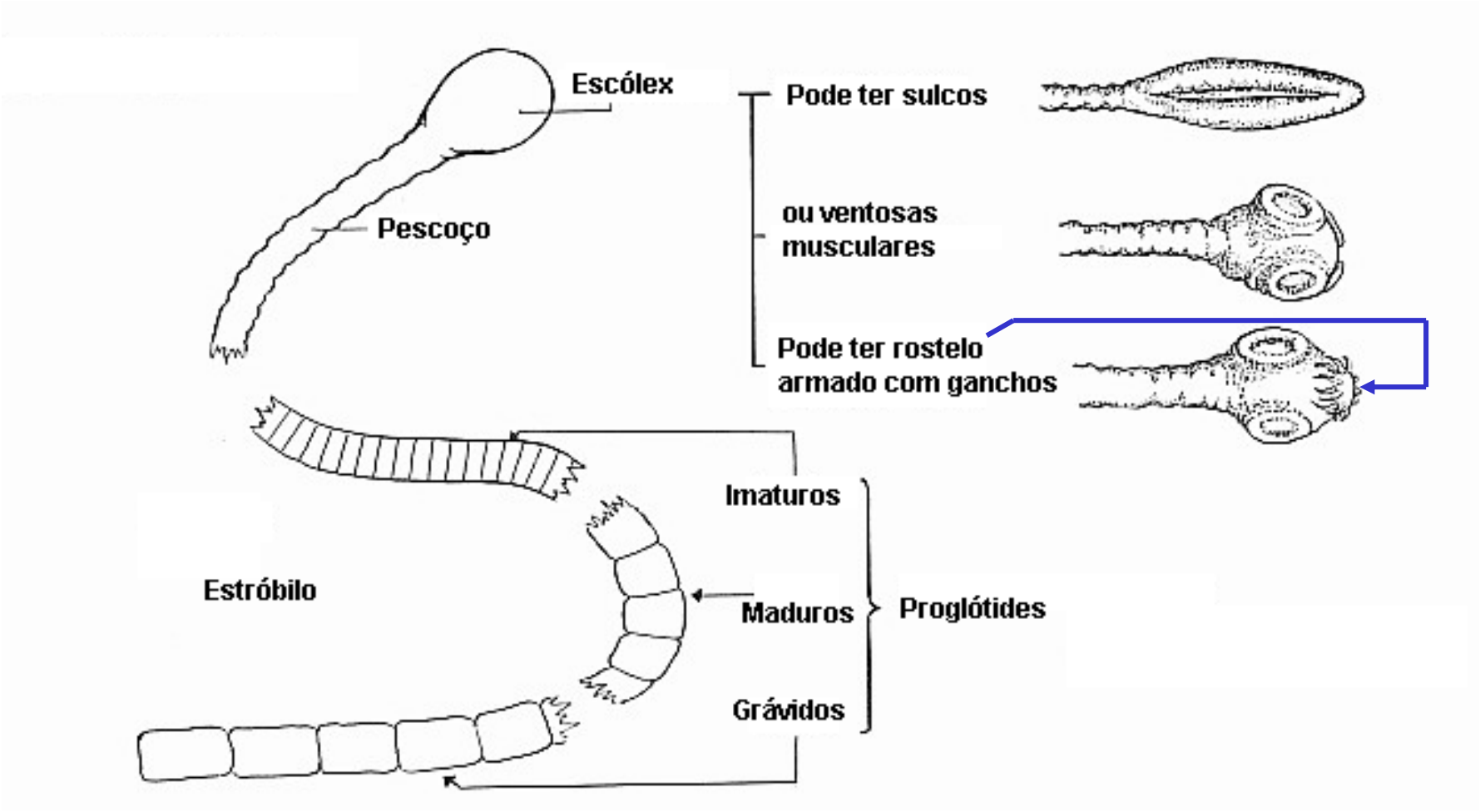

Taenia saginata

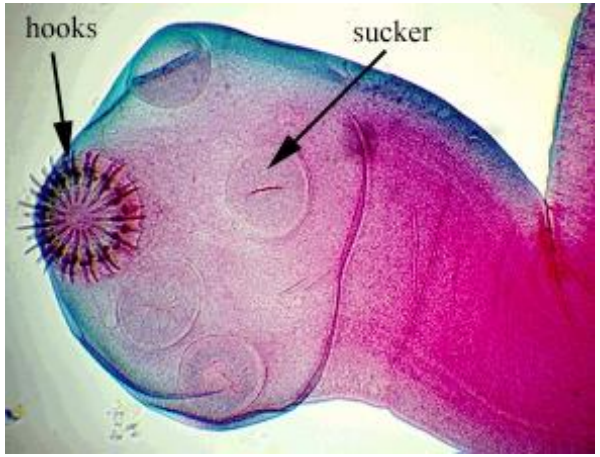

Taenia solium

Hymenolepis nana

Echinococcus granulosos

Ultraestrutura do Tegumento de Cestóides

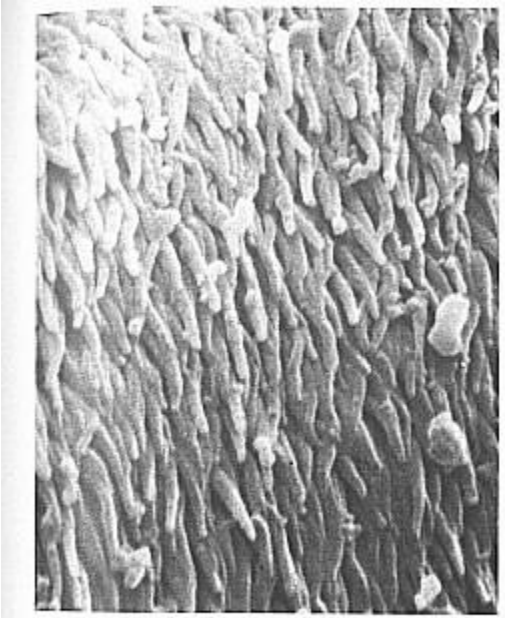

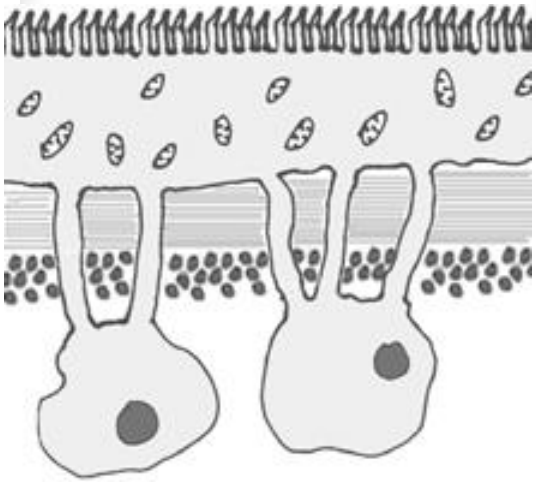

Comparação entre um enterócito de mamífero e o tegumento de um céstóide

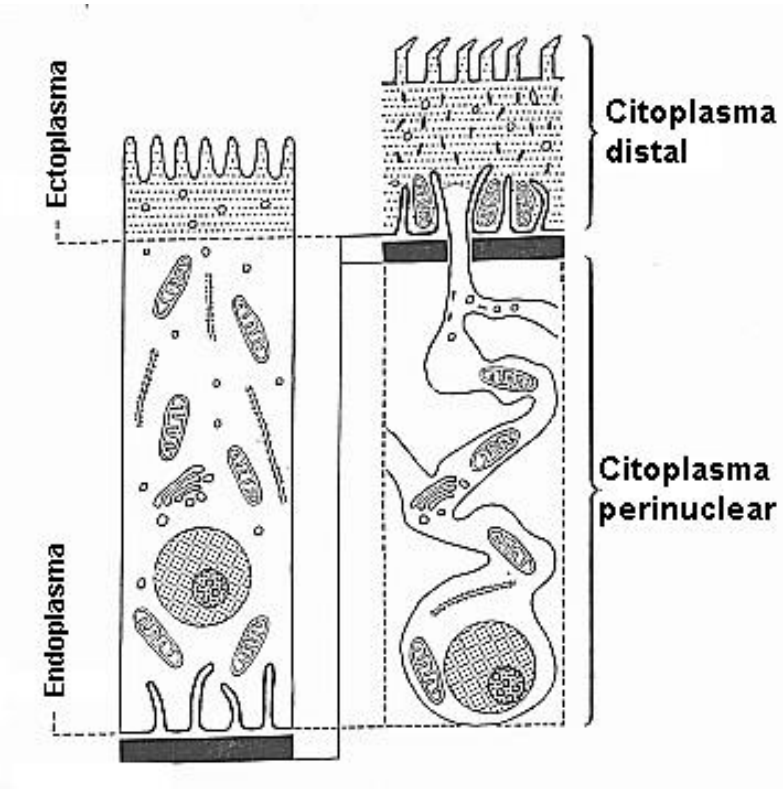

Glicocálix

Glicocálix

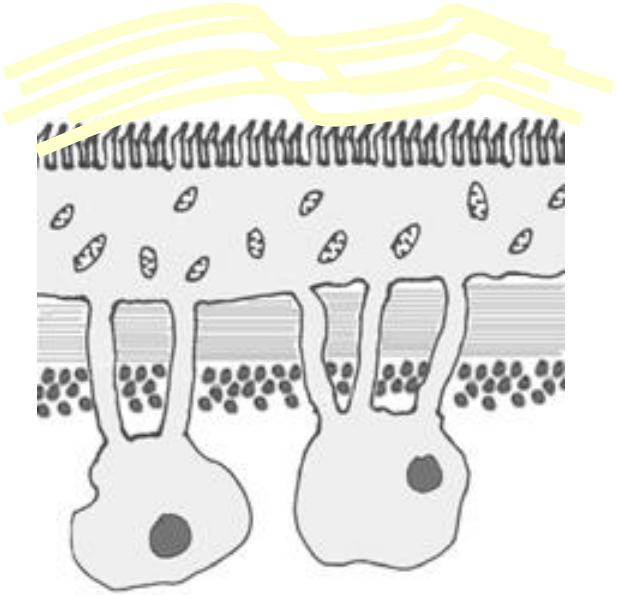

inibição de enzimas digestivas do hospedeiro

adsorção de sais biliares

atividade de amilase

Sistema Nervoso em Cestóides

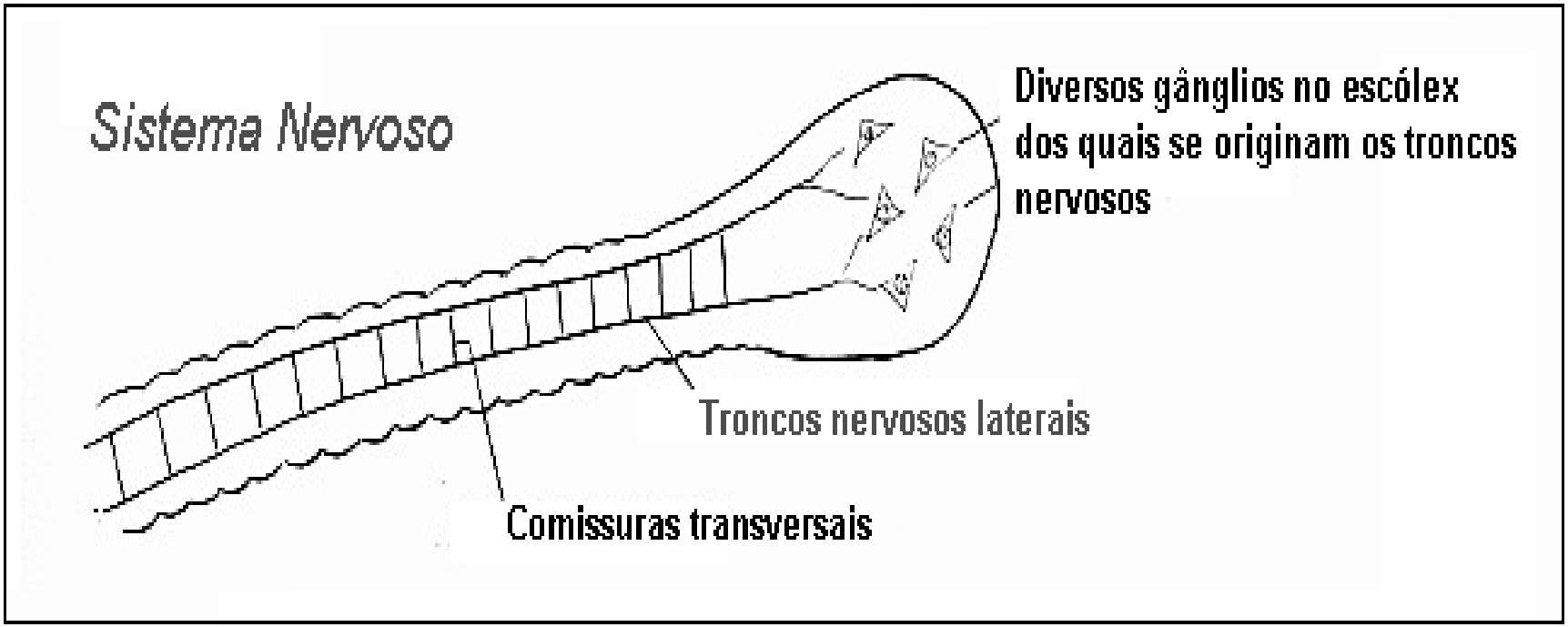

Serotonina: excitatória

Acetilcolina: inibitória

Percepção tátil e química

Movimento

Sistema Excretor em Cestóides

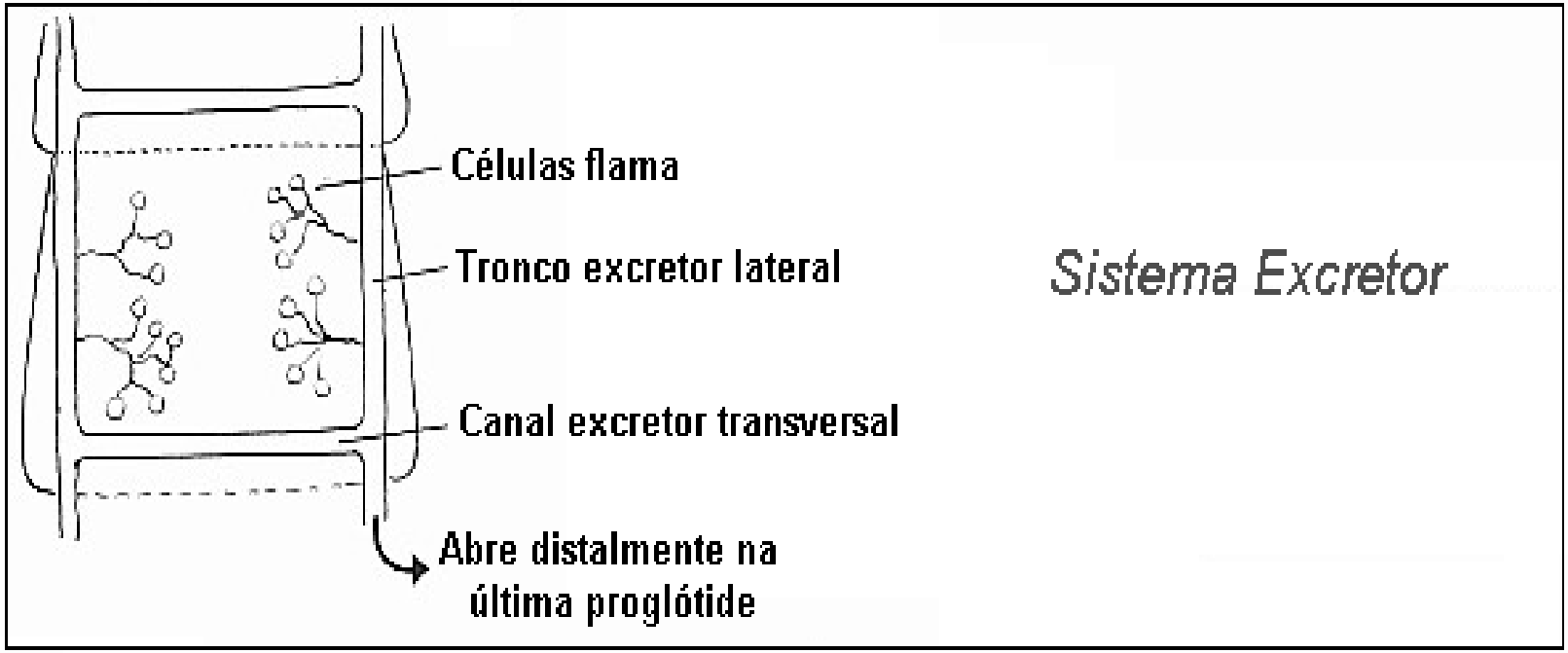

transporte ativo de produtos excretados
regulação iônica
osmo-regulação

Desenvolvimento do Estróbilo

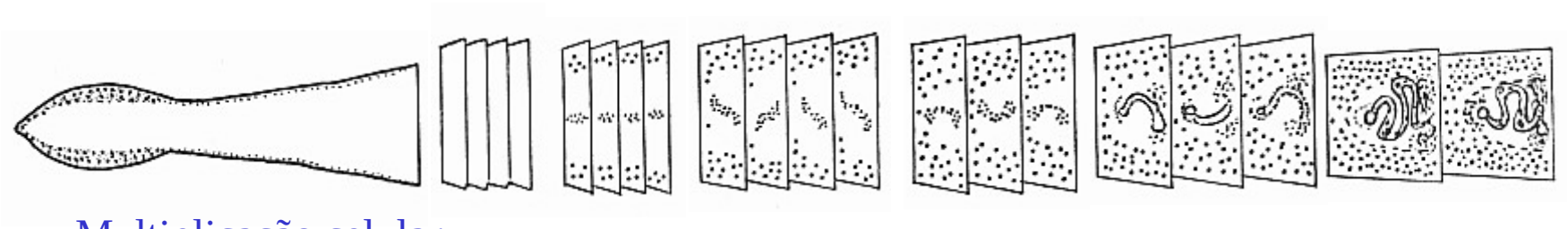

Multiplicação celular

"Segmentação"

Organogênese

Gametogênese

Formação da casca

Oviposição

Estróbilo

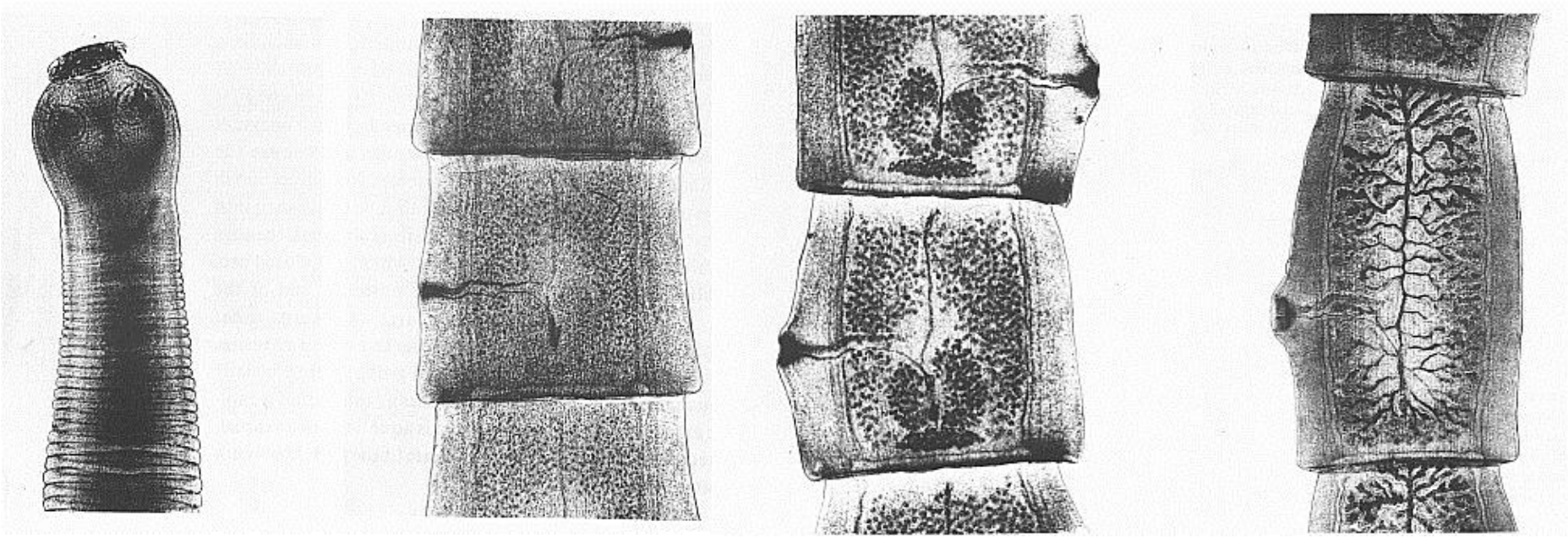

Escólex | Seção Imatura | Seção Madura | Seção grávida

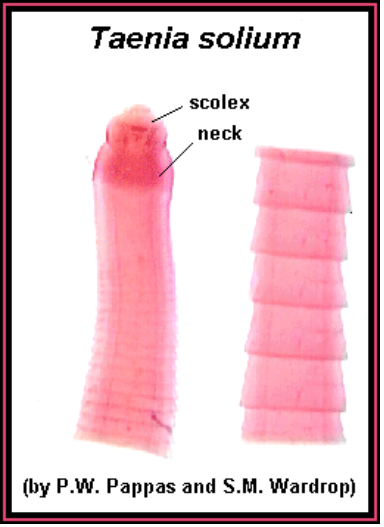

Sistema reprodutivo

Proglótide Jovem

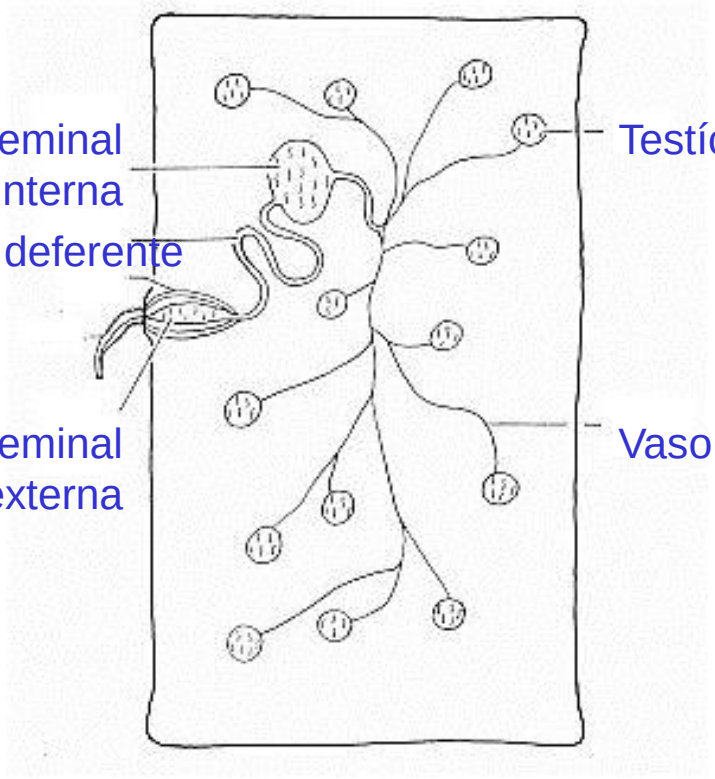

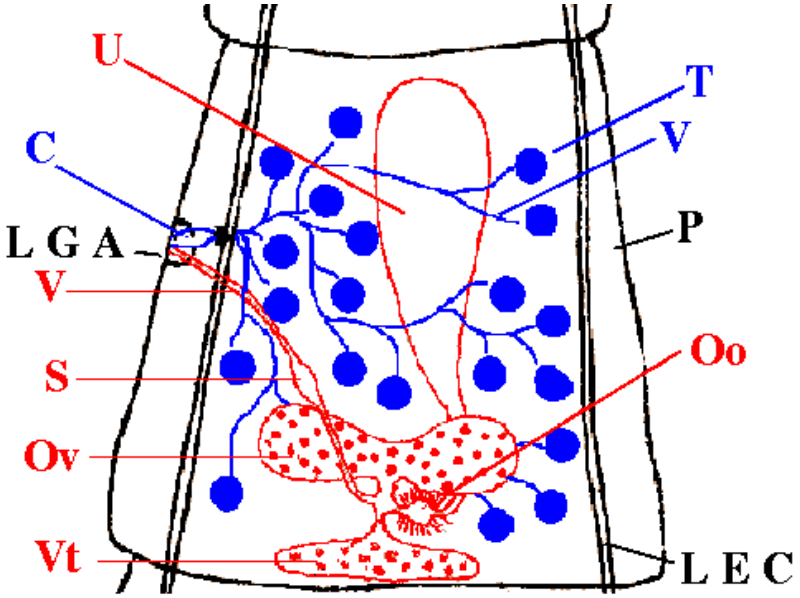

Proglótide Madura

Taenia
mature proglottids



(by P.W. Pappas and S.M. Wardrop)

Taenia solium

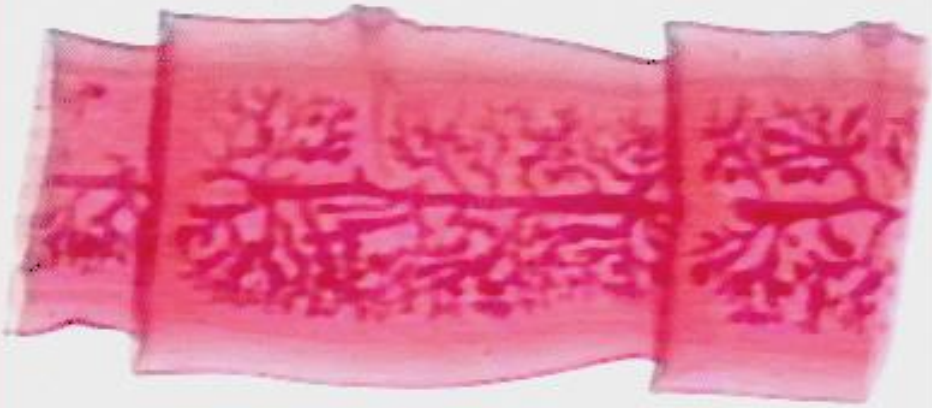

gravid proglottid

(by P.W. Pappas and S.M. Wardrop)

Ovos de *Taenia* sp.

50.000 a 100.000 ovos/estróbilo

Desenvolvimento de um cisticerco

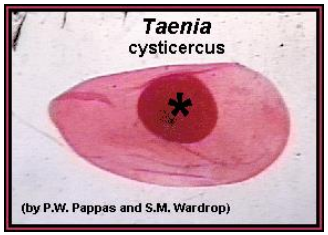

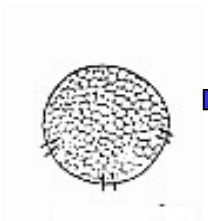

Oncosfera

Surgimento de uma região cheia de líquido

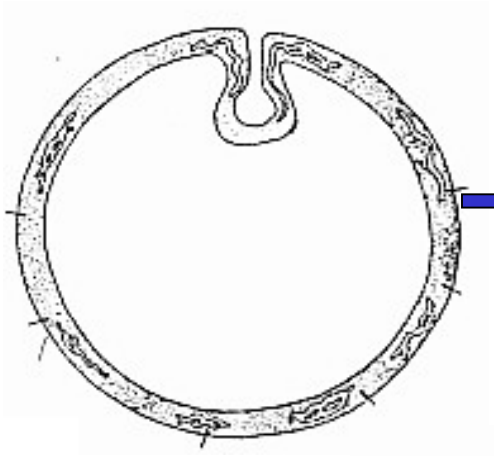

Invaginação da Parede

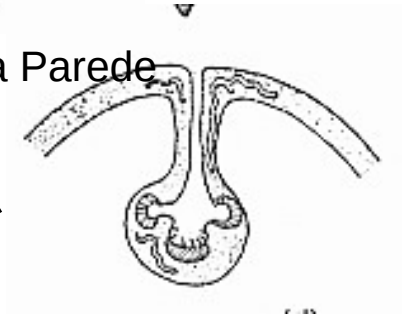

Formação do rostelo e vento-sas

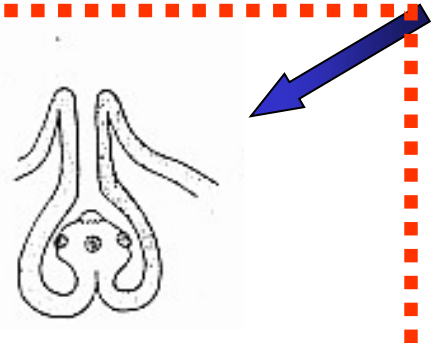

Início da evaginaçao

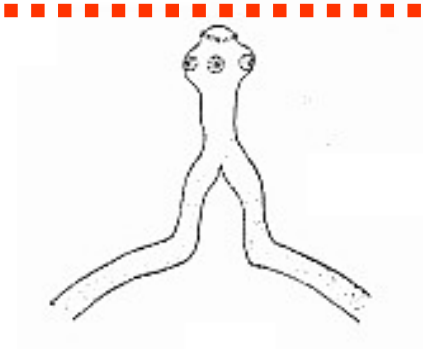

Final da evaginaçao

hospedeiro definitivo

Principais formas larvárias dos cestóides que infectam o homem



Cisticerco

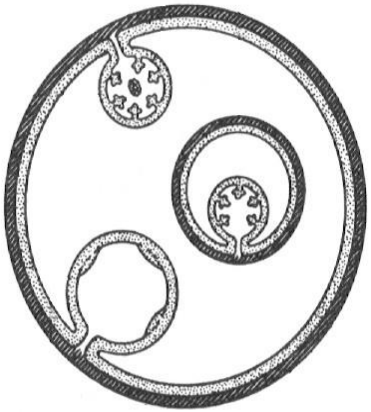

Hidátide

Cisticercóide

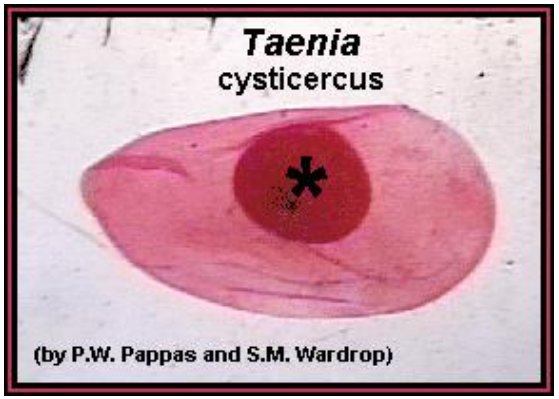

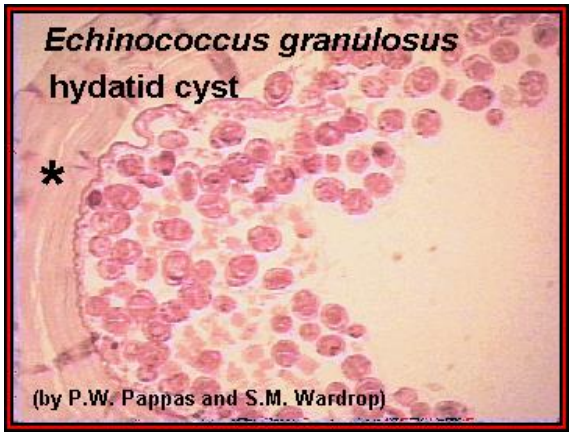

CICLO DE VIDA DE UM CESTÓIDE

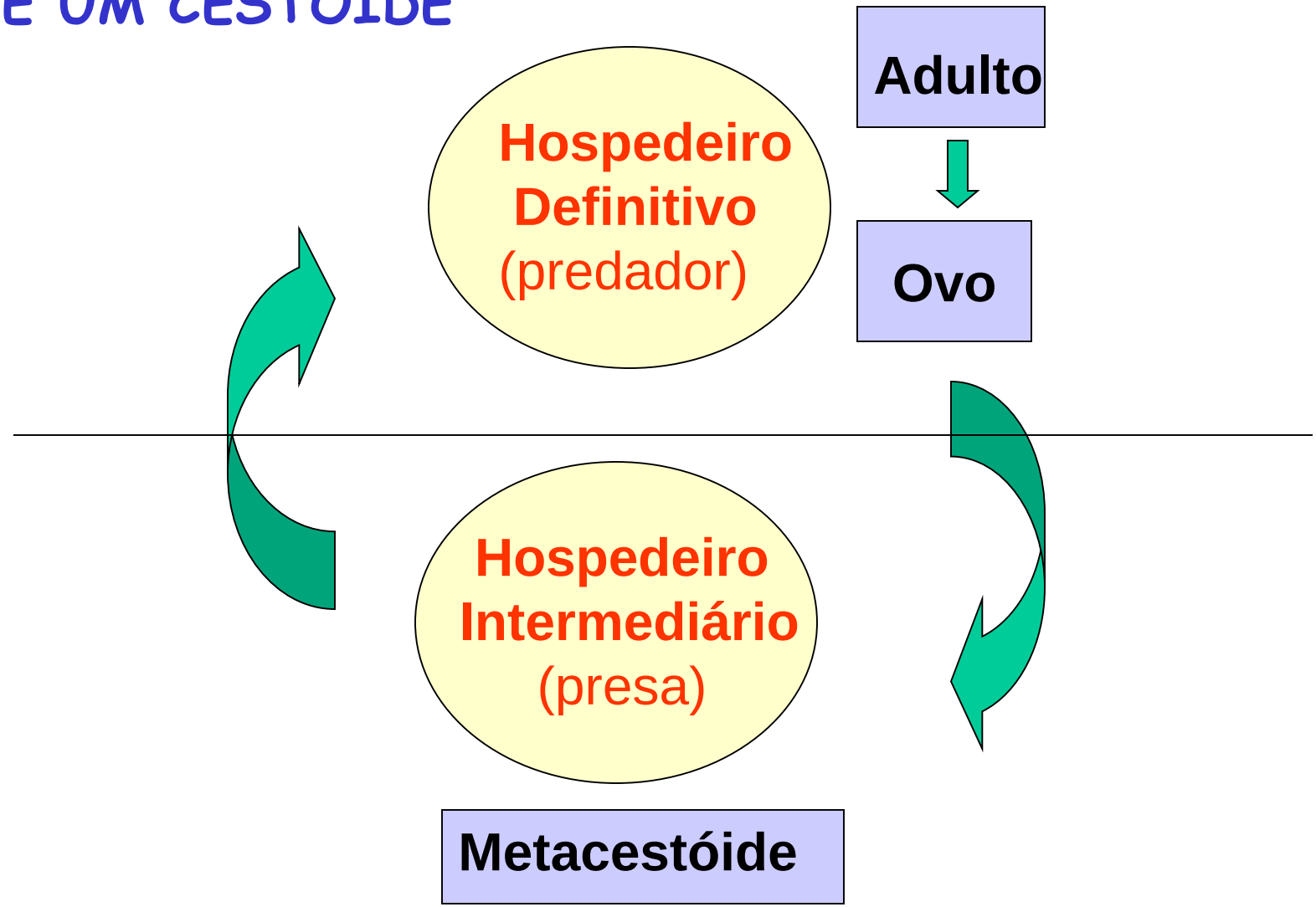

Ciclo de vida de *Taenia solium* e *Taenia saginata*

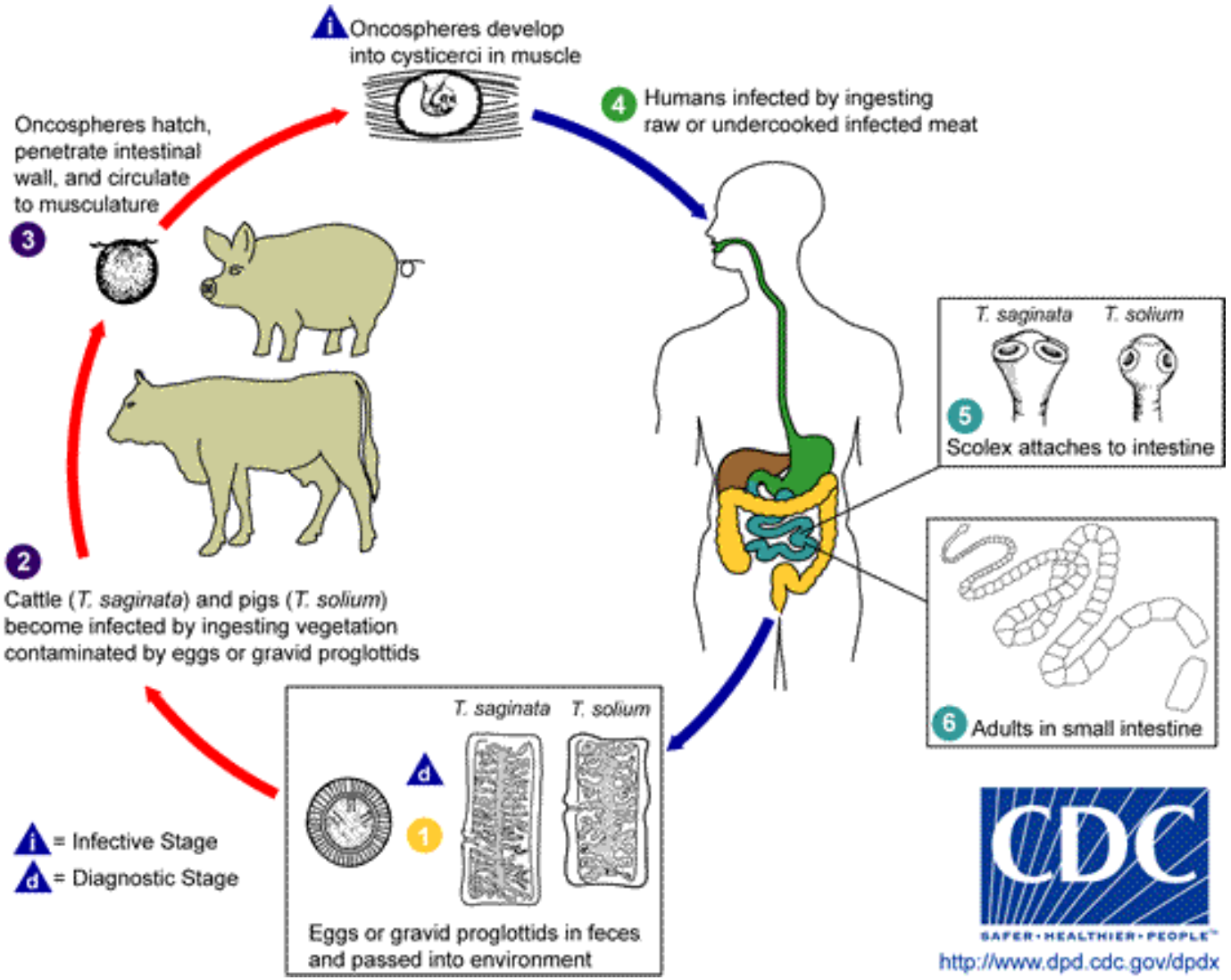

Cisticercos em carne bovina

Taenia solium

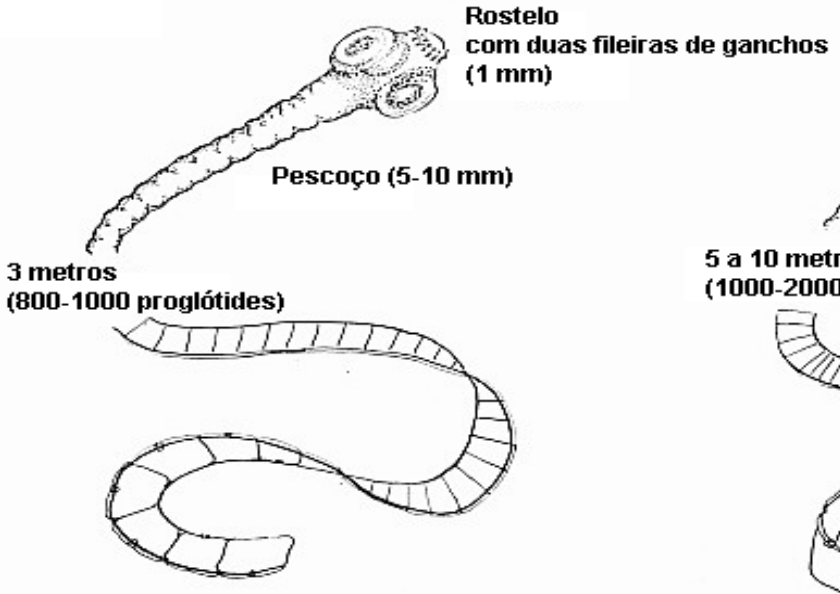

Taenia saginata

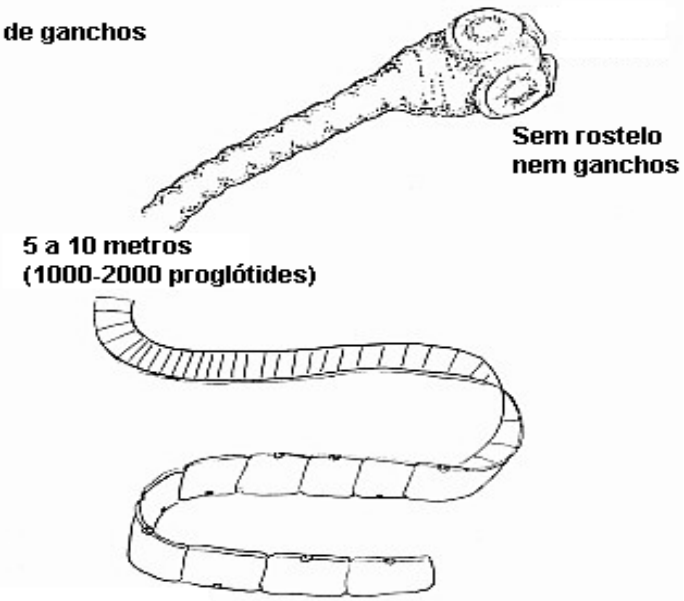

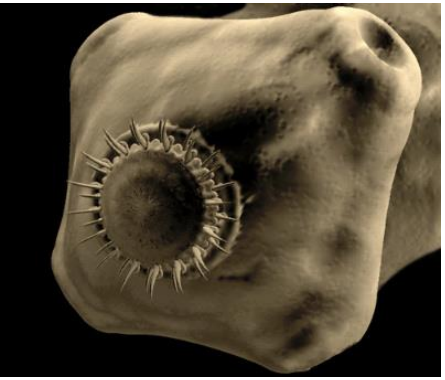

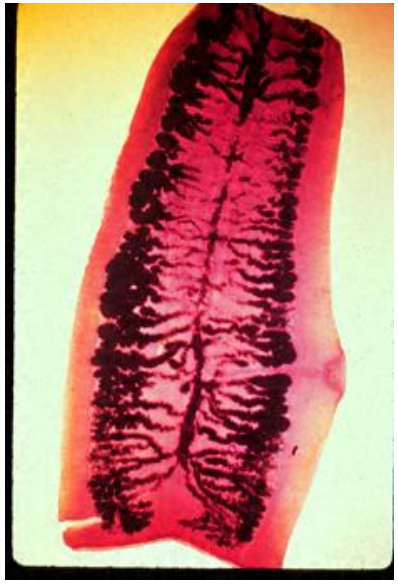

Diferenciação entre

Taenia solium e *Taenia saginata*

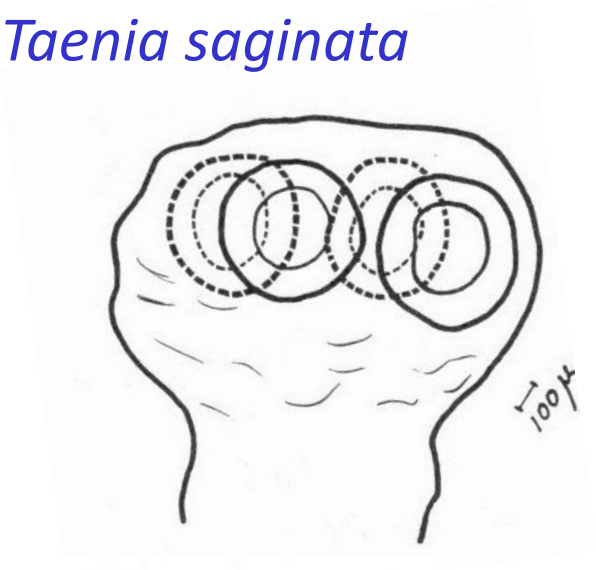

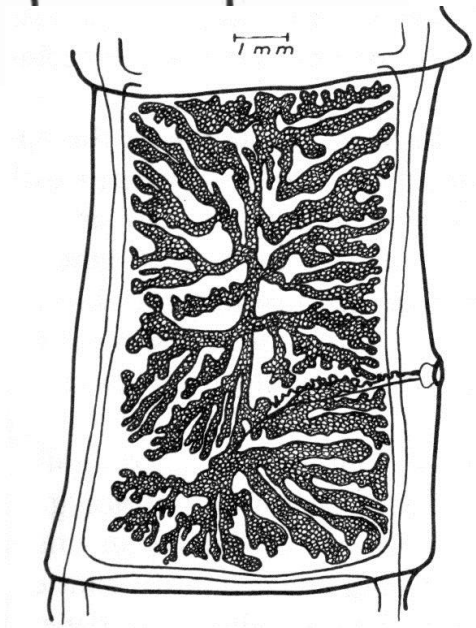

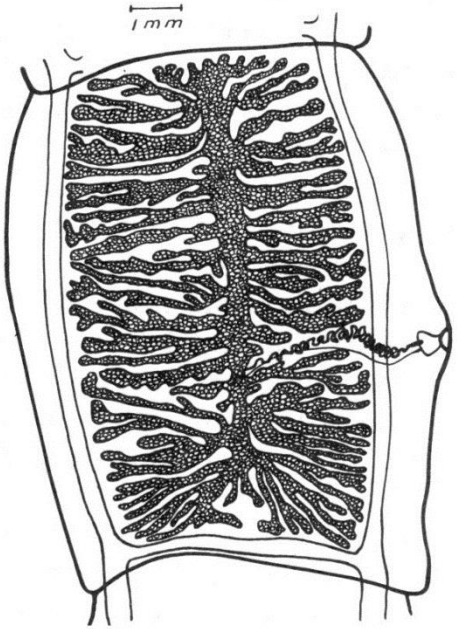

Endemicity of *Taenia solium*, 2015

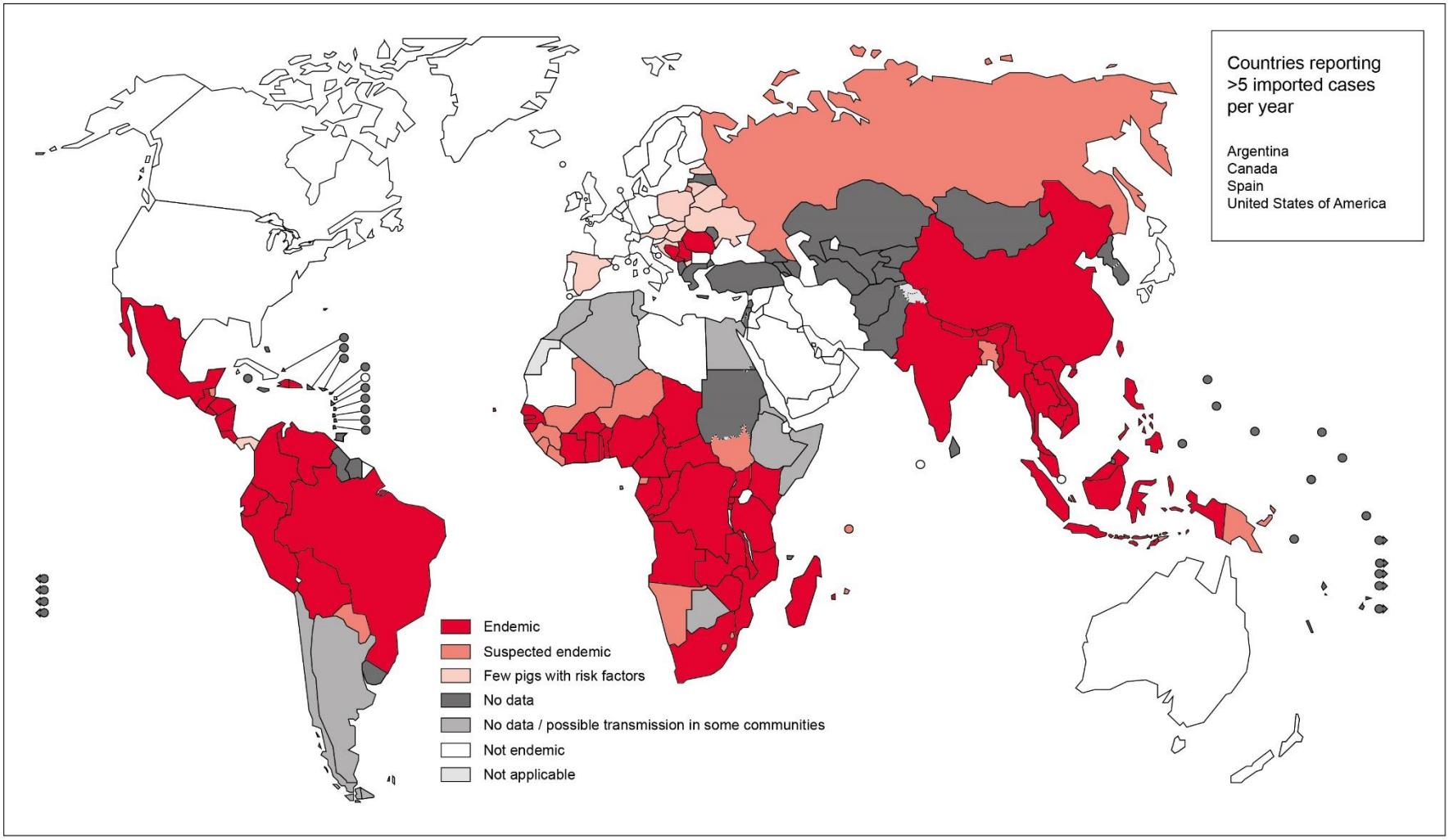

The boundaries and names shown and the designations used on this map do not imply the expression of any opinion whatsoever on the part of the World Health Organization concerning the legal status of any country, territory, city or area or of its authorities, or concerning the delimitation of its frontiers or boundaries. Dotted lines on maps represent approximate border lines for which there may not yet be full agreement. © WHO 2016. All rights reserved

Data Source: World Health Organization
Map Production: Control of Neglected Tropical Diseases (NTD)
World Health Organization

World Health Organization

Patologia

Os vermes adultos se nutrem do conteúdo intestinal do hospedeiro.

Sintomatologia pobre: dor abdominal, diarréia, cefaléia.

Não há imunidade permanente para o hospedeiro definitivo.

Cisticercose - *T. solium*

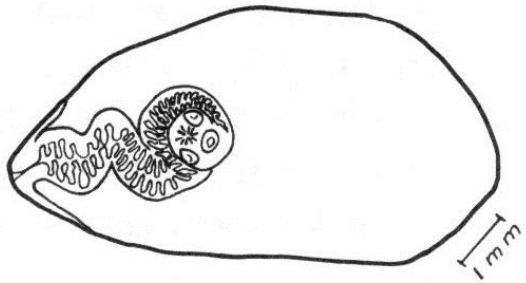

Patologia

Depende da localização do cisticerco.

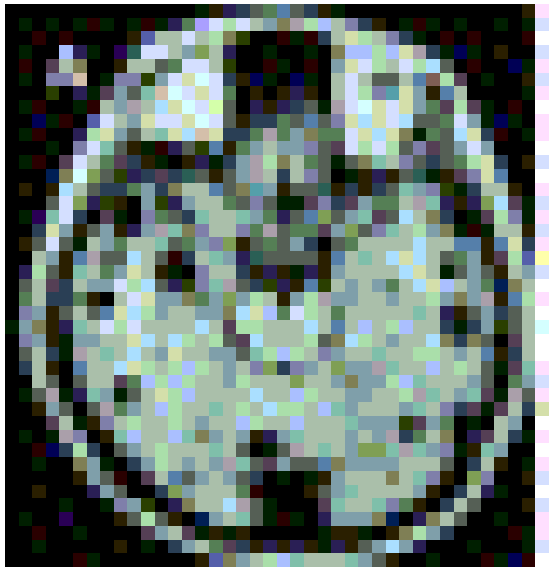

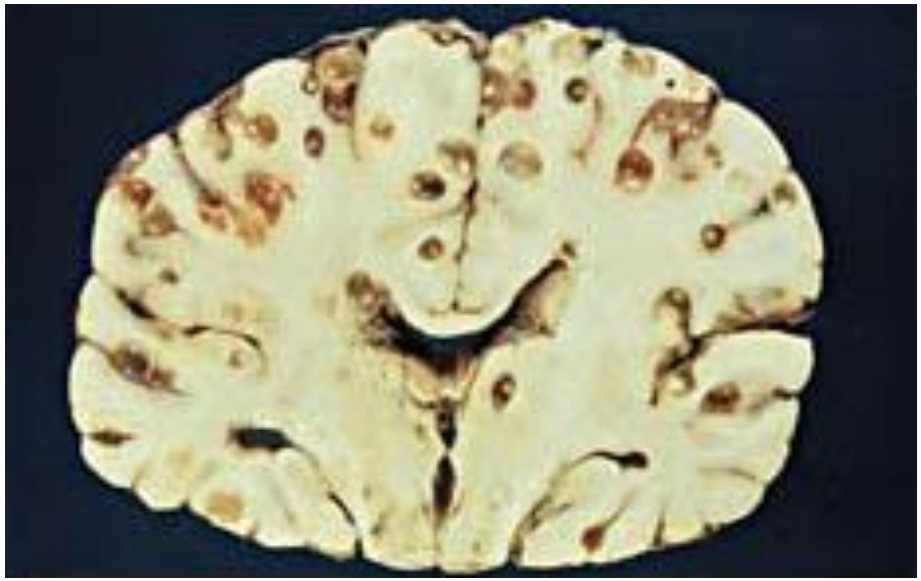

Localizações mais frequentes: subcutâneo, olho, cérebro. Cistos podem ser encontrados em qualquer tecido.

Epilepsia

Não ocorre reação inflamatória ao redor do cisticerco vivo.

Cysticercal encephalitis

Nelly Gonzalez, Maria Guadalupe Trevino, Hector R Martinez, Gerardo Rivera Silva

Lancet 2014; 383: 342
Published Online
August 30, 2013
http://dx.doi.org/10.1016/S0140-6736(13)60691-1

Universidad de Monterrey, Health Science Division, Monterrey, NL, Mexico (N Gonzales MD, M G Trevino PhD, H R Martinez MSc, G Rivera Silva PhD).

Correspondence to: Dr Gerardo Rivera Silva, Av. I. Morones Prieto # 4500 Pte, San Pedro Garza Garcia, NL, 66238 Mexico
gerardo.rivera@udem.edu.mx

A 10-year-old boy was brought to our emergency room with generalized tonic-clonic seizures that had started one hour before. There was a three-year history of seizures treated with phenytoin (5 mg per kg twice daily) and headache associated with fever. The patient went into cardiopulmonary arrest (RR 5 per min, HR 40 per min, SBP 50 mmHg, weak pulse, capillary refill >15 sec). On examination, he was unconscious (GCS: 3/15), with both pupils dilated and unresponsive. Cardiopulmonary resuscitation was done, but vital signs did not return; the patient was declared dead. In postmortem analysis, a coronal section of the brain showed bilateral ventricular cavities collapsed, and generalized cerebral oedema with cortical and subcortical distribution of numerous intraparenchymal cysts of various sizes, some with visible larvae (figure). Microscopically, the cysts contained the larvae preserved (figure) or in degrees of decomposition (figure). Interstitial deposits, fibrosis, gliosis, and necrosis were also found.

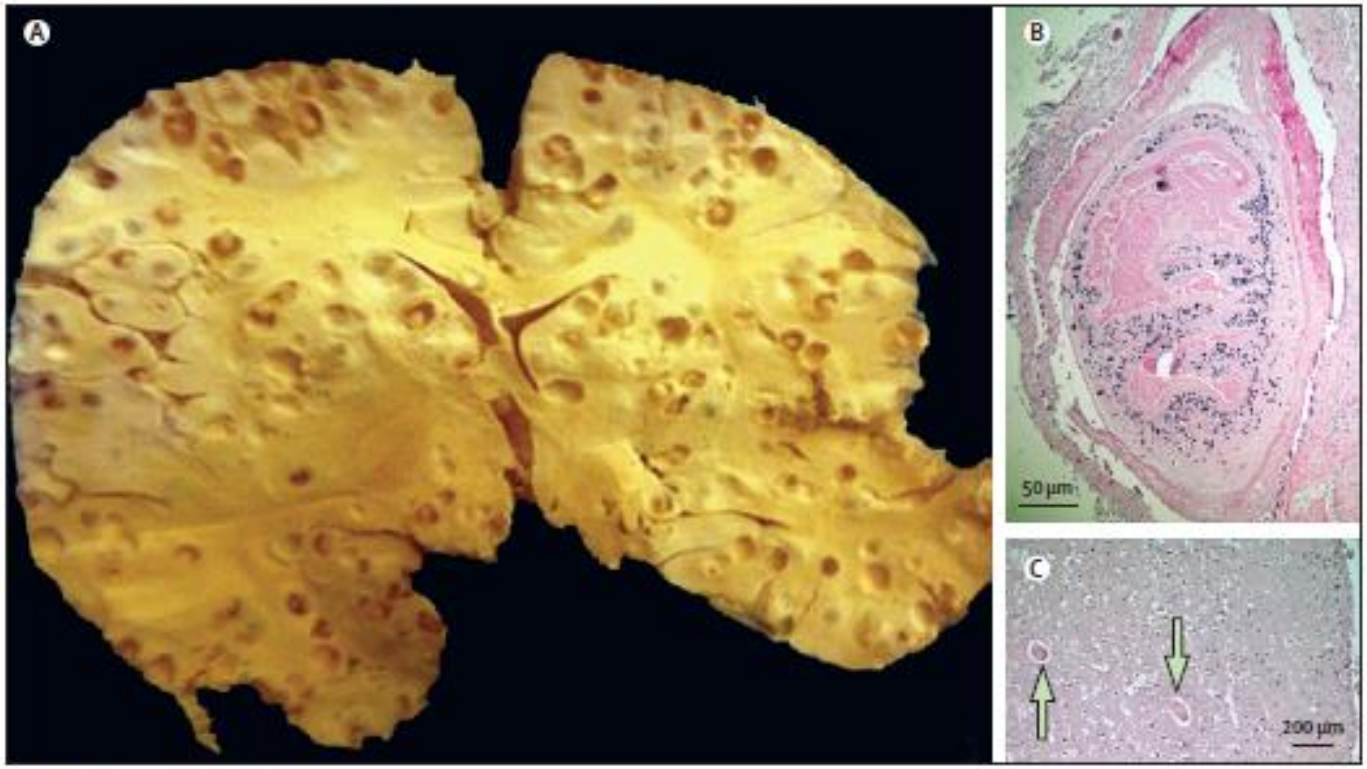

Figure: Cysticercal encephalitis
(A) Coronal section of brain, showing intraparenchymal cysts, (B) preserved larvae (haematoxylin and eosin stain), (C) decomposed larvae (arrows; haematoxylin and eosin stain).

Diagnóstico

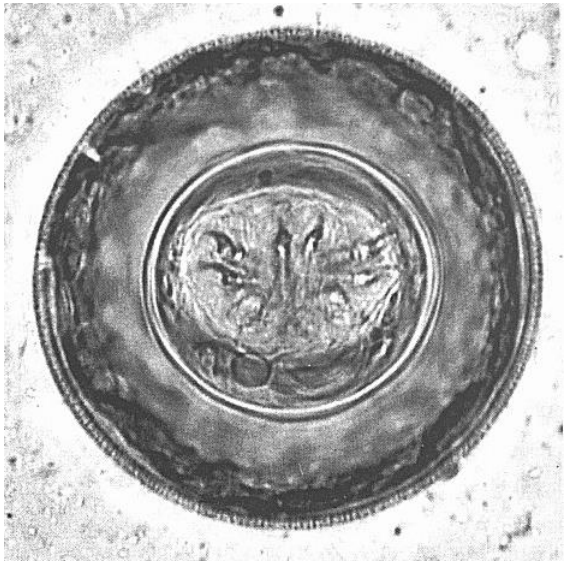

Teníase - ovos nas fezes
- fita adesiva
- pesquisa de antígenos nas fezes

Cisticercose (*T. solium*)

imagem radiológica
reações imunológicas (soro, LCR)

Diagnóstico

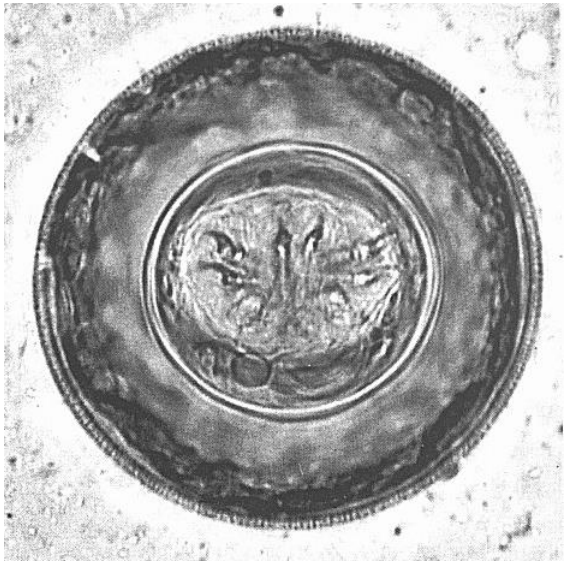

Teníase - ovos nas fezes
- fita adesiva
- pesquisa de antígenos nas fezes

Cisticercose (*T. solium*)

imagem radiológica
reações imunológicas (so

Tratamento

Teníase: niclosamida (ou clorossalicilamida), praziquantel

Cisticercose: albendazol ou praziquantel; corticosteróides

Praziquantel produz um rápido influxo de cálcio (Ca^{2+}) acompanhada por rápida contração da musculatura e formação de bolhas e vacúolos no tegumento.

Albendazol reduz a produção de ATP pelo verme, inibe a polimerização dos microtúbulos (imobilização).

Efeitos de praziquantel

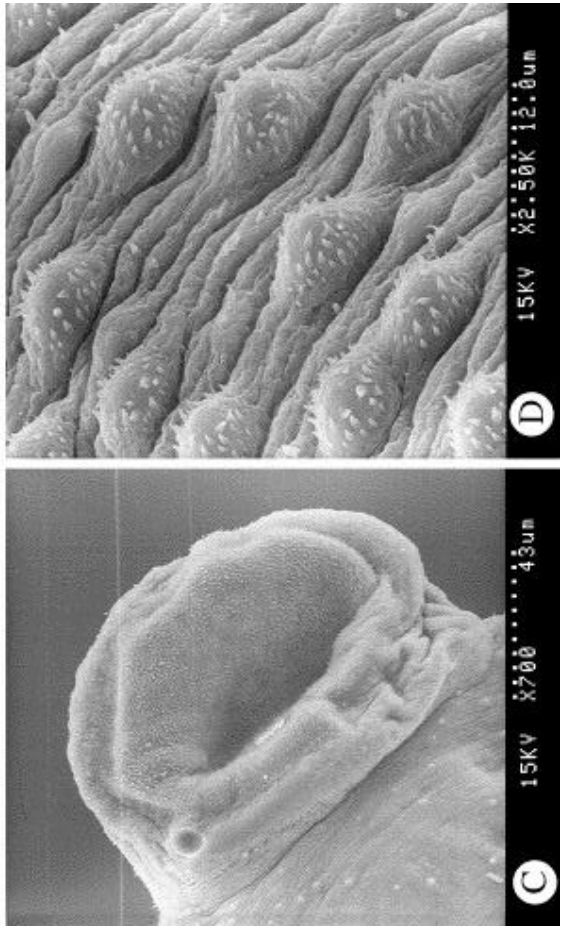

Normal

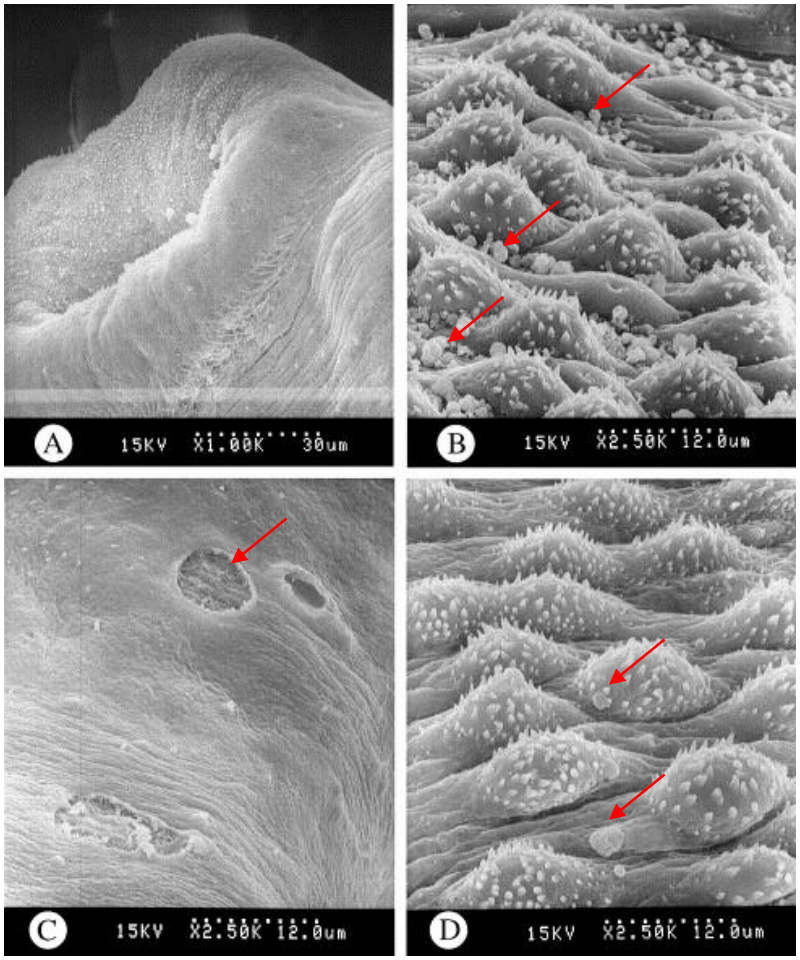

Tratado

Jiraungkoorskul et al. Effects of praziquantel and artesunate on the tegument of adult *Schistosoma mekongi* harboured in mice. Parasitol Int. 2005 Sep;54(3):177-83.

Controle de teníase

-tratamento adequado dos alimentos (cocção)

-controle e congelamento da carne

-tratamento dos animais

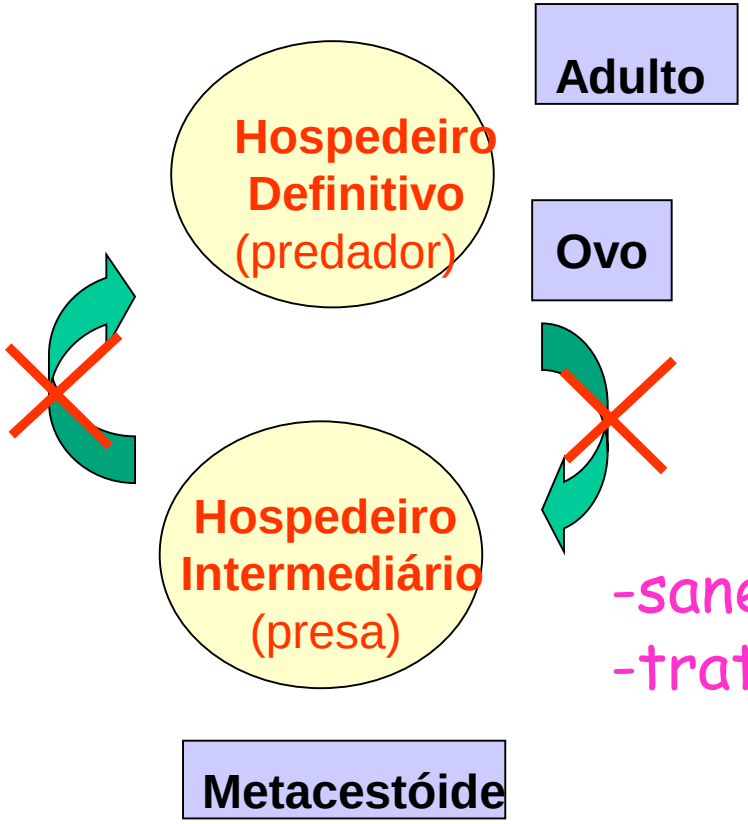

-saneamento básico
-tratamento dos doentes

Controle de teníase e cisticercose

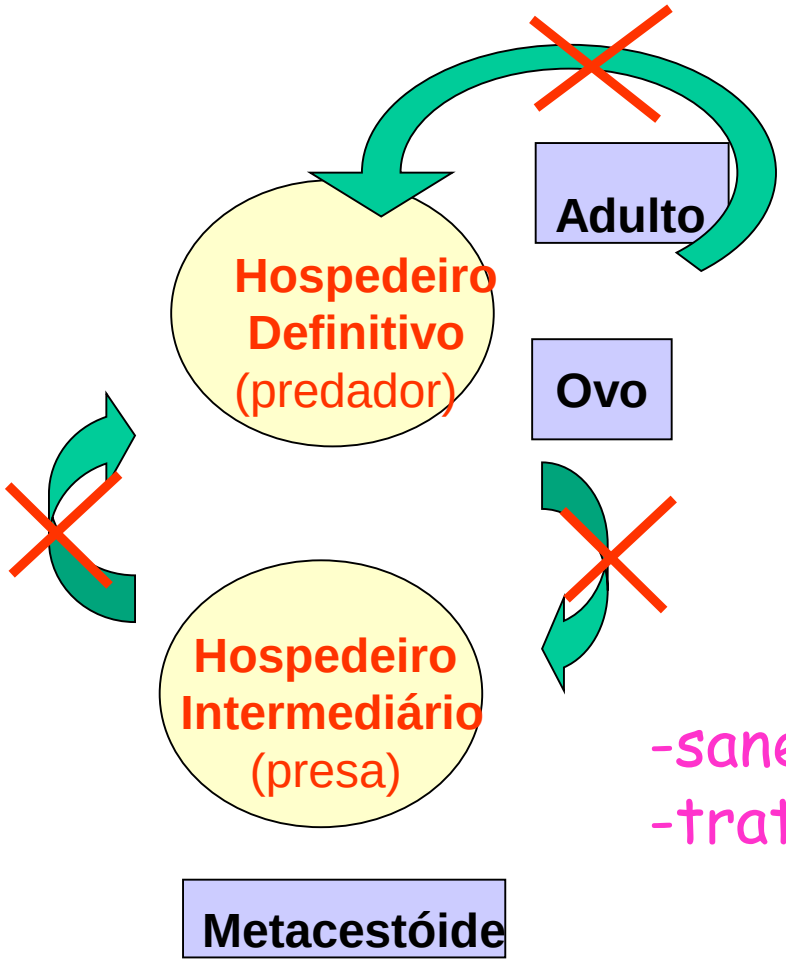

-higiene pessoal
-saneamento básico
-tratamento adequado dos alimentos
- tratamento dos doentes

-tratamento adequado dos alimentos

-controle e congelamento da carne

-tratamento dos animais

-saneamento básico
-tratamento dos doentes

Vacina: clonagem de antígenos recombinantes

BioOne® RESEARCH EVOLVED

Development of the S3Pvac Vaccine Against Porcine *Taenia solium* Cysticercosis: A Historical Review

Author(s): Edda Sciutto, Gladis Fragoso, Marisela Hernández, Gabriela Rosas, José J. Martínez, Agnès Fleury, Jacquelynne Cervantes, Aline Aluja, and Carlos Larralde

Source: Journal of Parasitology, 99(4):686-692.
Published By: American Society of Parasitologists
https://doi.org/10.1645/GE-3102.1
URL: http://www.bioone.org/doi/full/10.1645/GE-3102.1

Echinococcus granulosus

Ciclo de vida de *Echinococcus granulosus*

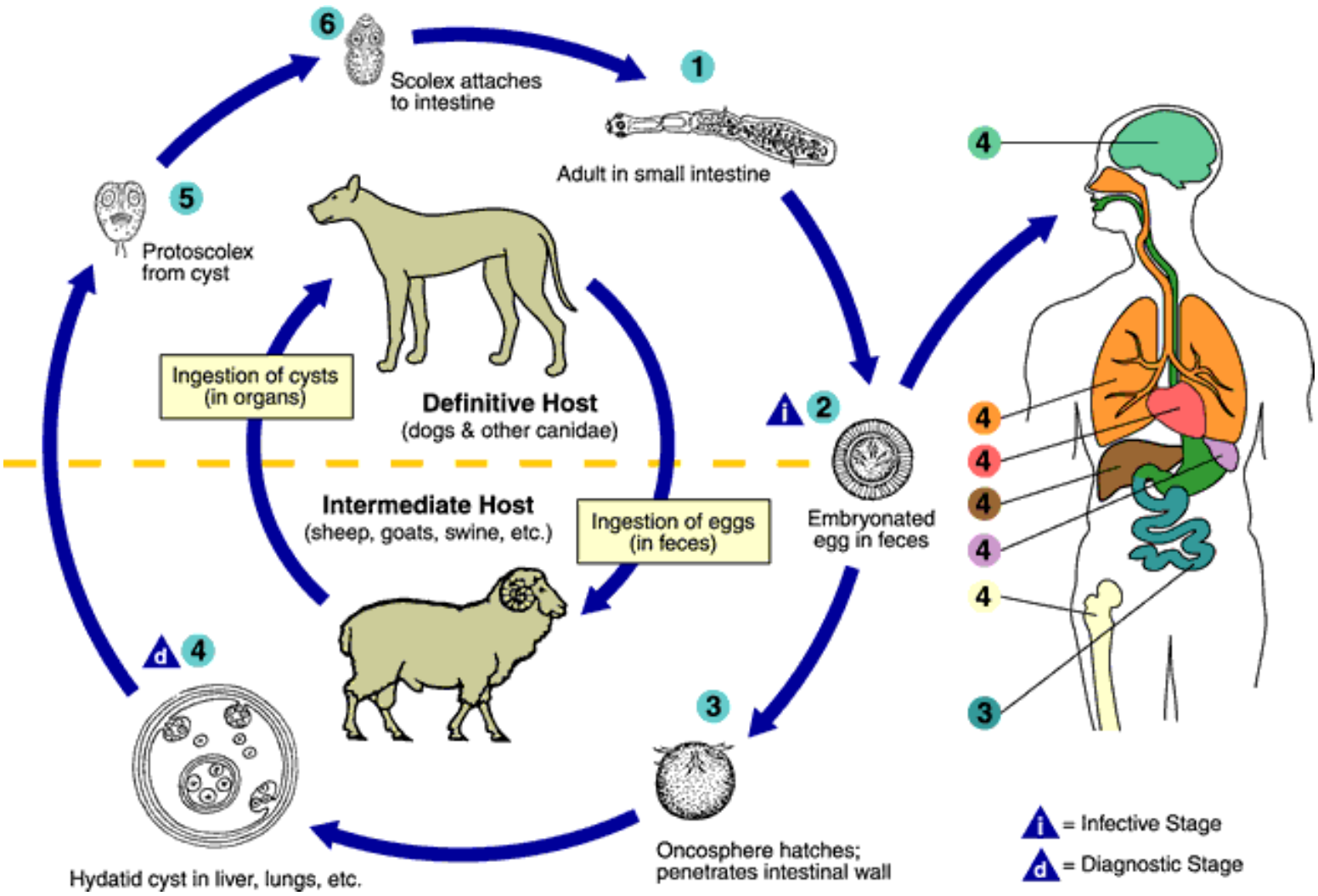

E. granulosus- Equinococose ou Hidatidose

Epidemiologia: Austrália, Sul da América do Sul, América do Norte, Europa, Ásia, África.

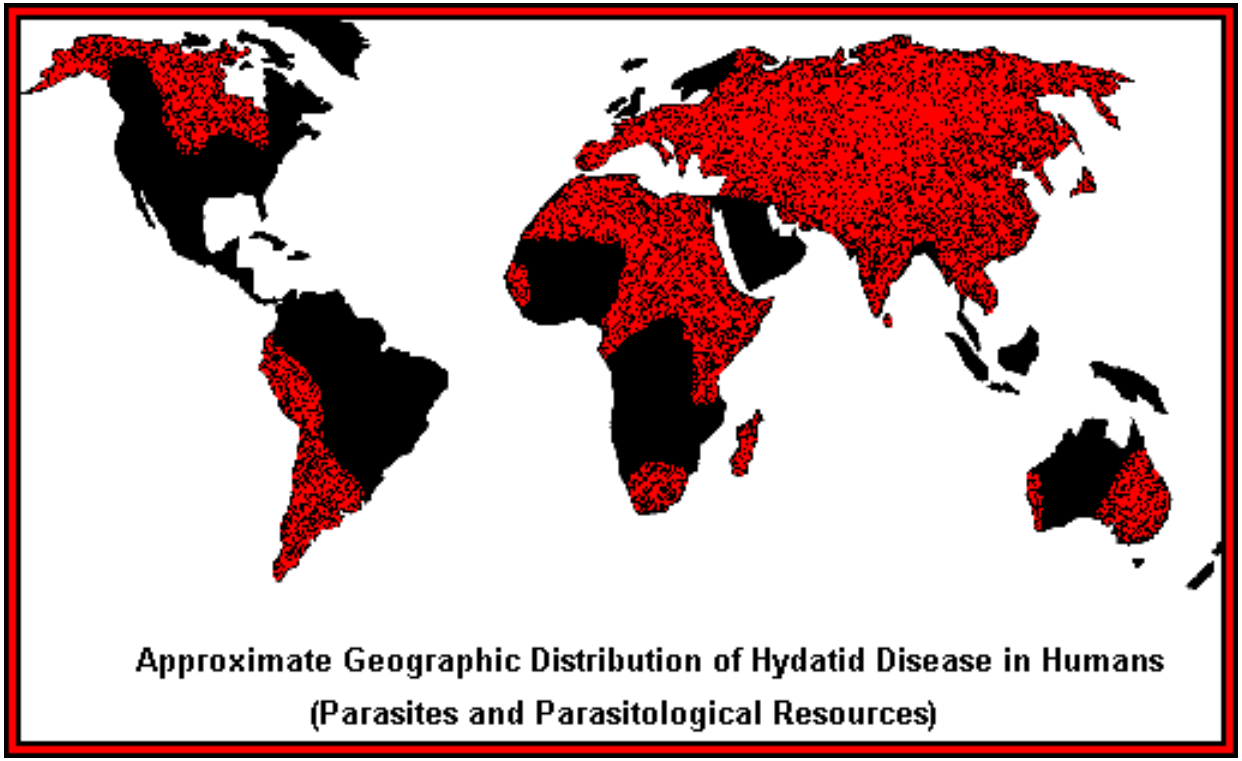

Cisto hidático

O cisto,mais frequentemente localizado no fígado, leva a sinais compatíveis com uma massa tumoral: icterícia, emagrecimento. O cisto pode evoluir por anos sem sintomatologia.

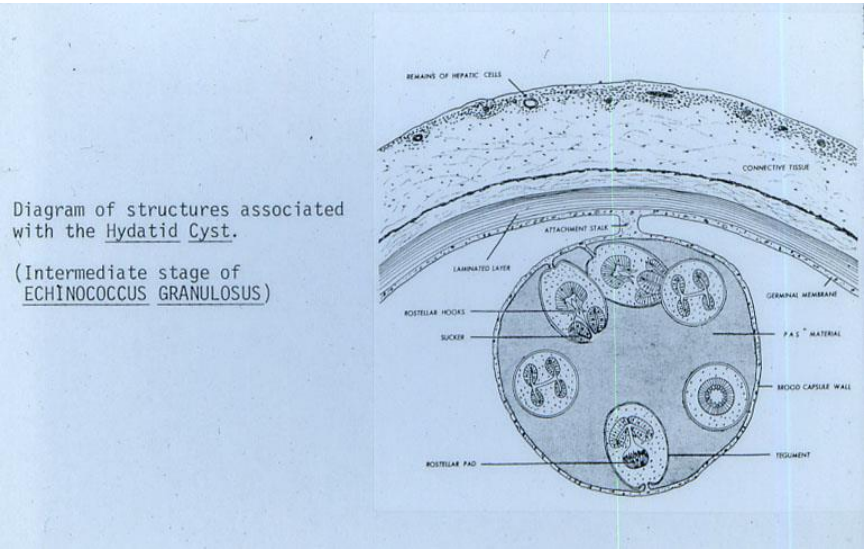

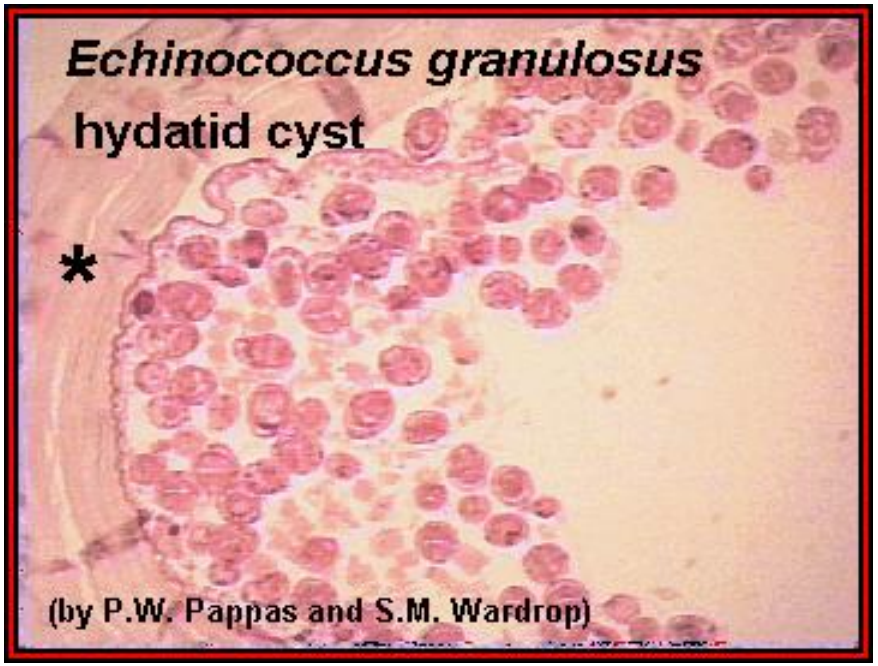

Estrutura da hidátide de *Echinococcus granulosus*

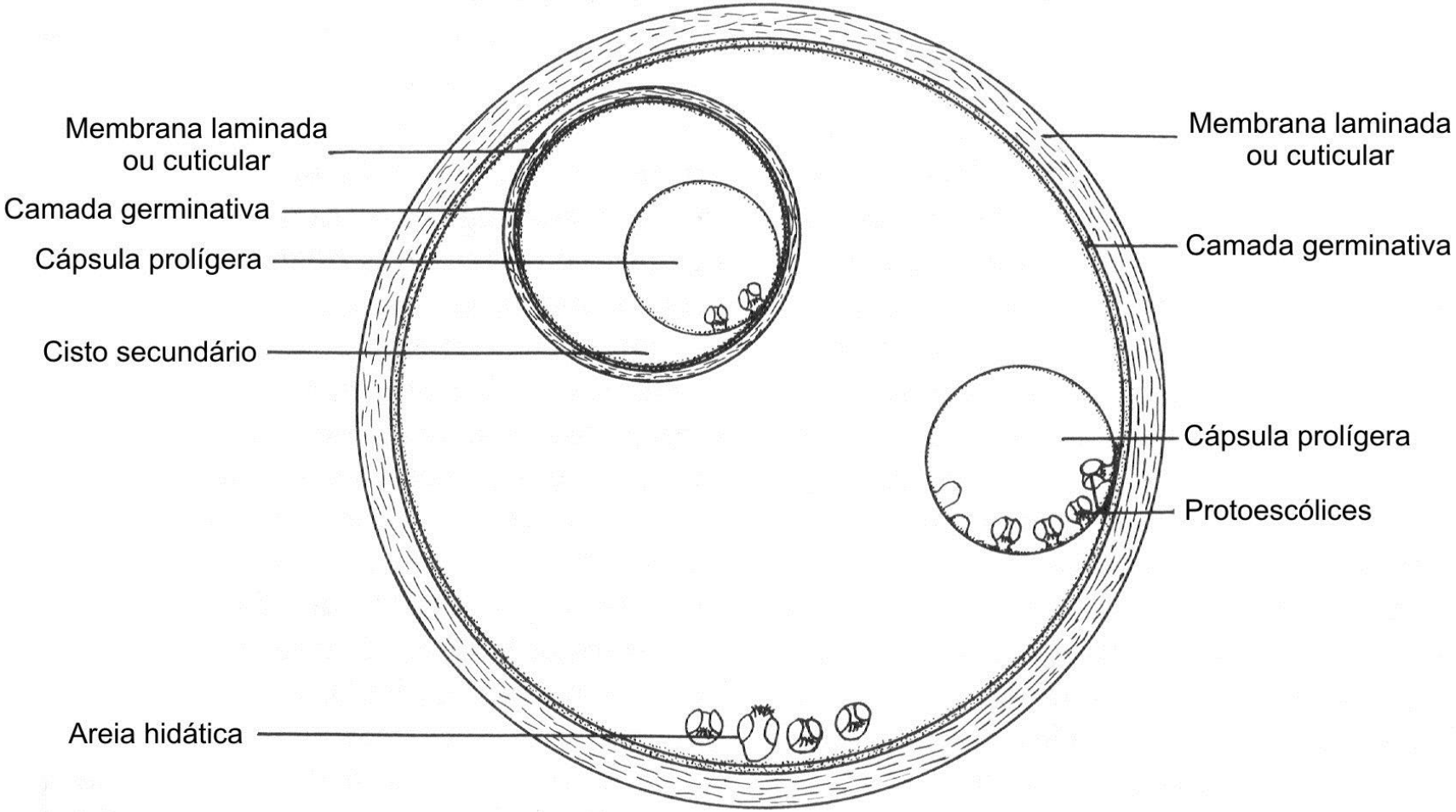

Hidatidose

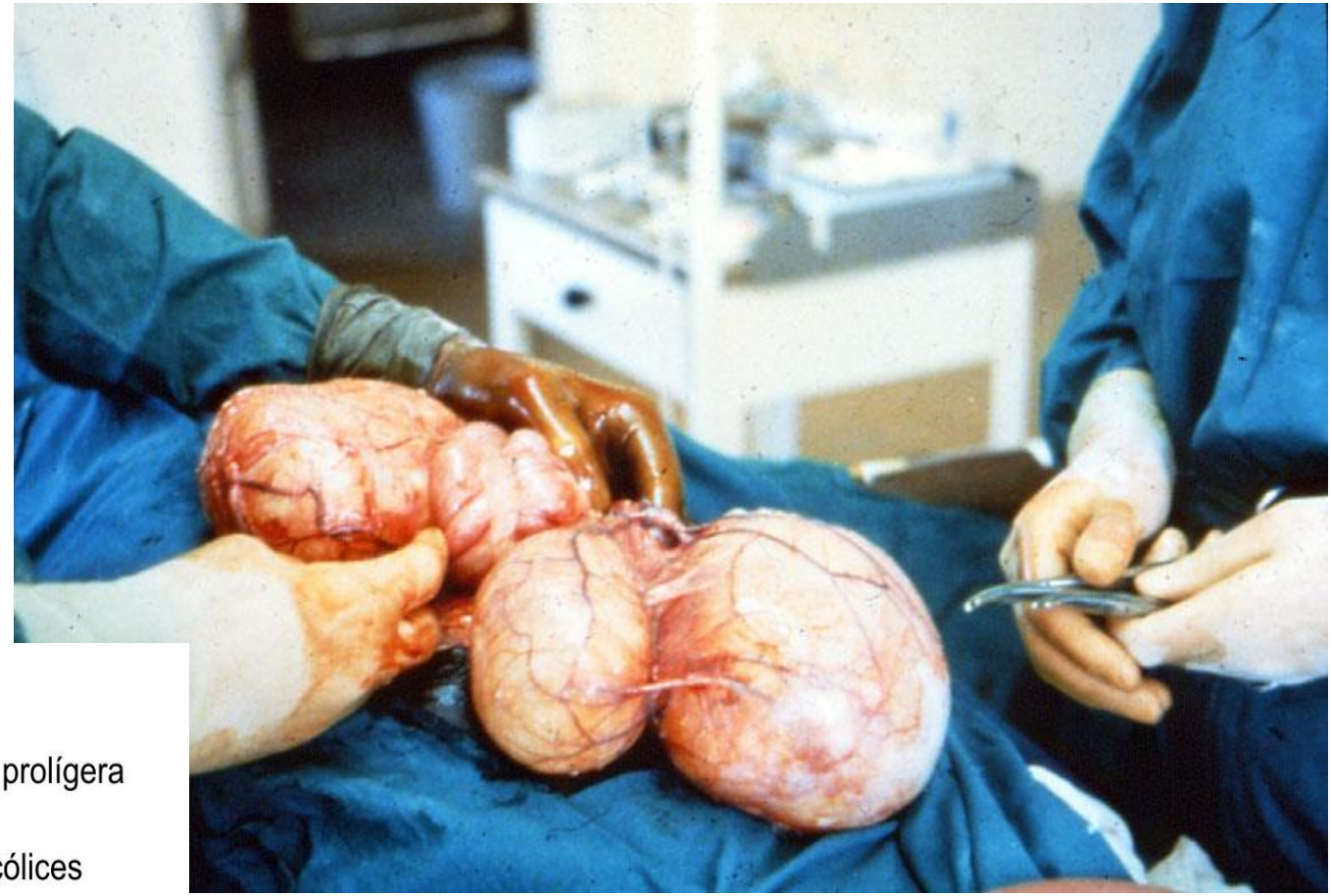

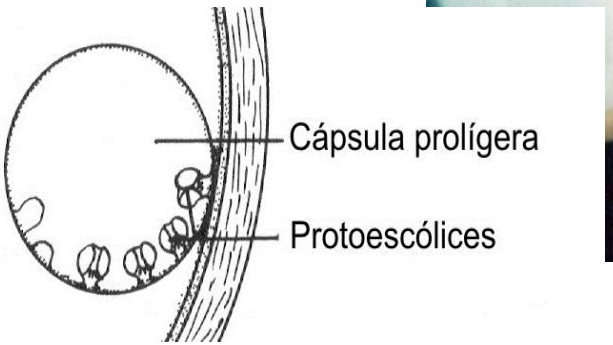

Hidatidose *(E. granulosus)*

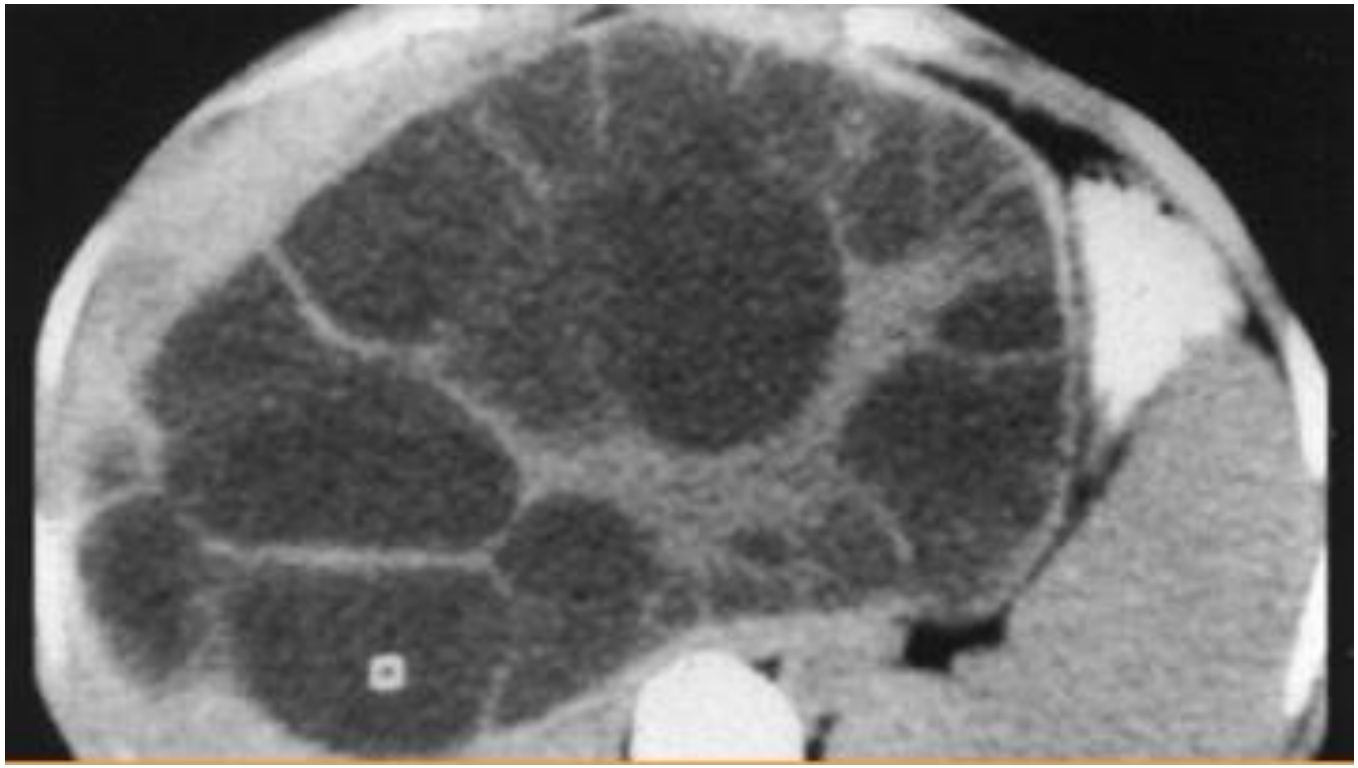

Diagnóstico

ultrassonografia
reações imunológicas

Controle de hidatidose

-impedir contato do cachorro com carcaças de animais do rebanho,
-tratamento do cachorro

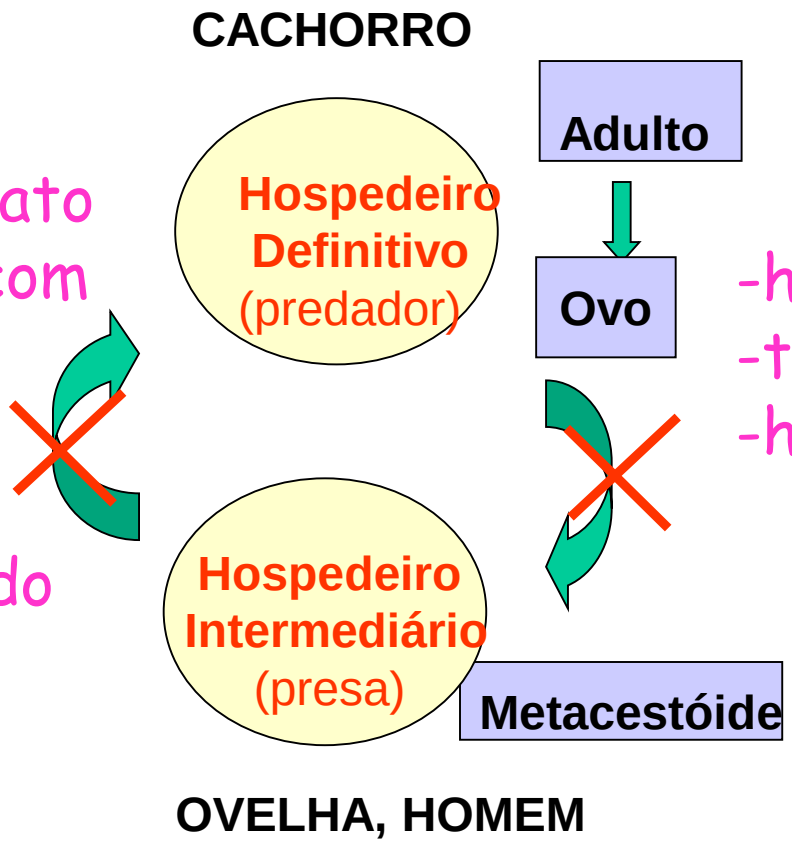

-higiene pessoal
-tratamento da água
-higiene de alimentos

-Vacina em fase de teste (carneiros)

"EG95 host-protective antigen" de *Echinococcus granulosus,* boa proteção (95-100% redução no número de cistos viáveis)

FOLHAONLINE

COTIDIANO

05/04/2005 - 09h07

Peixe cru causa surto de doença em SP; 18 casos foram anotados no ano

Diphyllobothrium latum

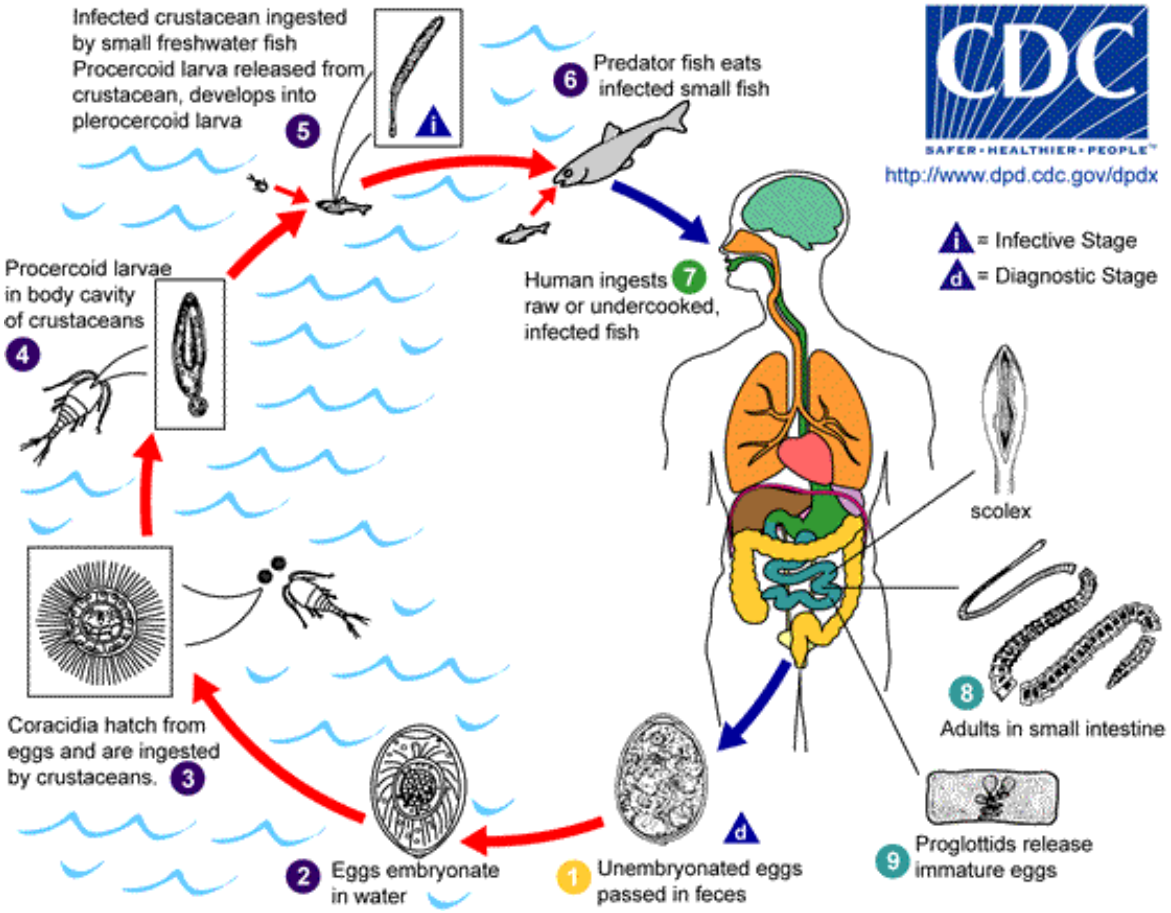

Hosp. Def.

Homem
Cães
Gatos
Raposas
Ursos
Porcos

Diphyllobothrium latum

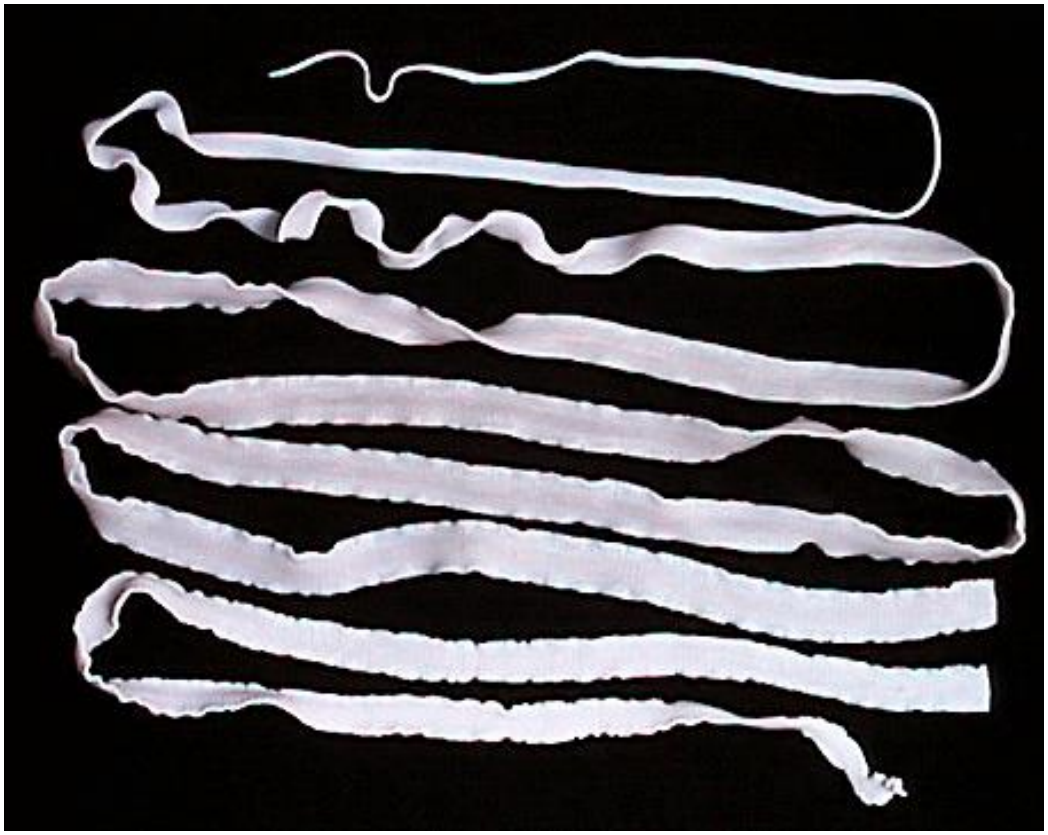

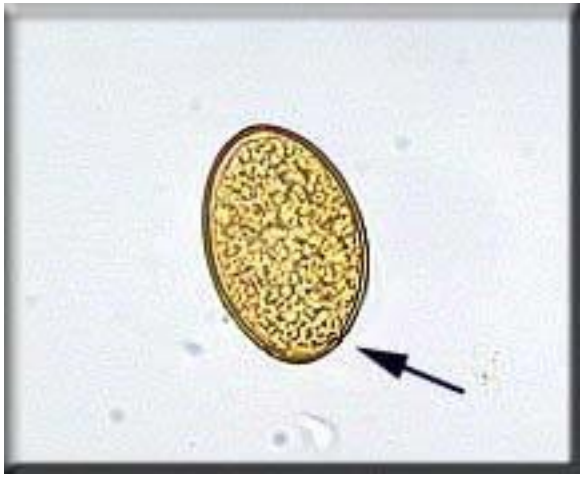

Interação parasita-hospedeiro

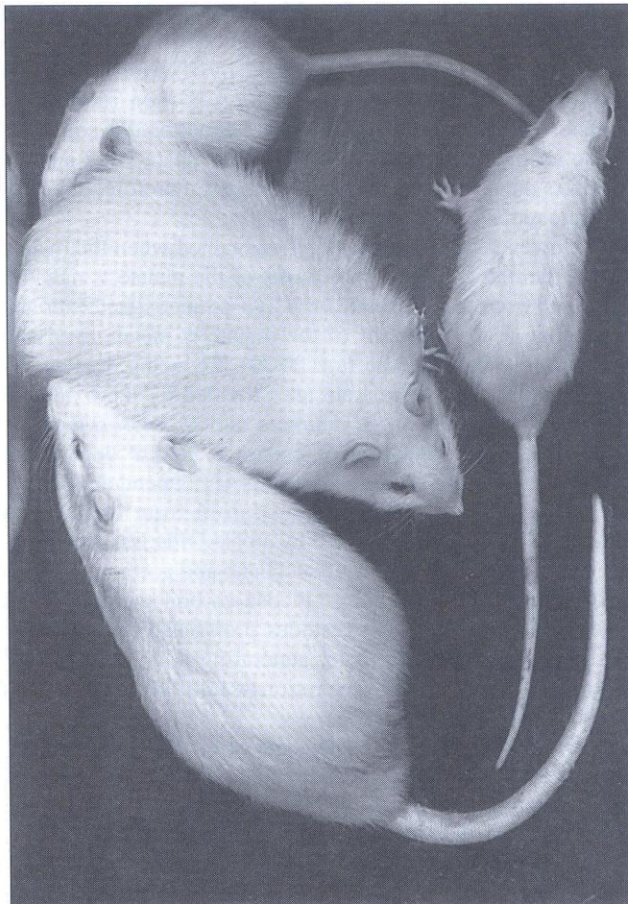

Ratos hipofisectomizados e infectados ou não com *Diphyllobothrium mansonoides*

Hymenolepis nana

"Tênia anã" - 40 mm

Hosp def: homem, roedores
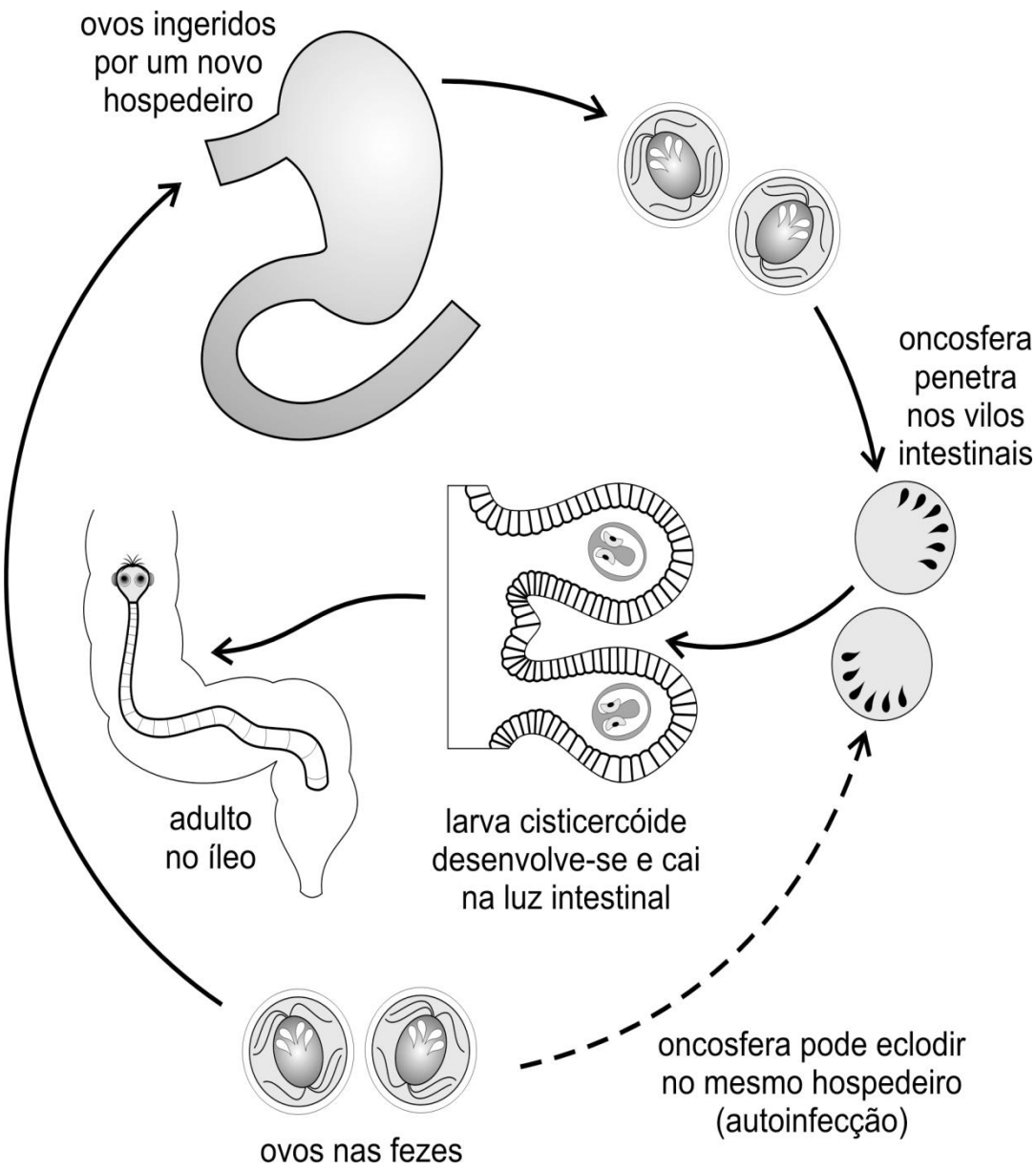
H. diminuta, um parasita de roedores, também pode infectar o homem.