



Exame Radiológico Vascular

Física Médica



*Division of Interventional Radiology
CCIFM – HC – FMRP - USP*





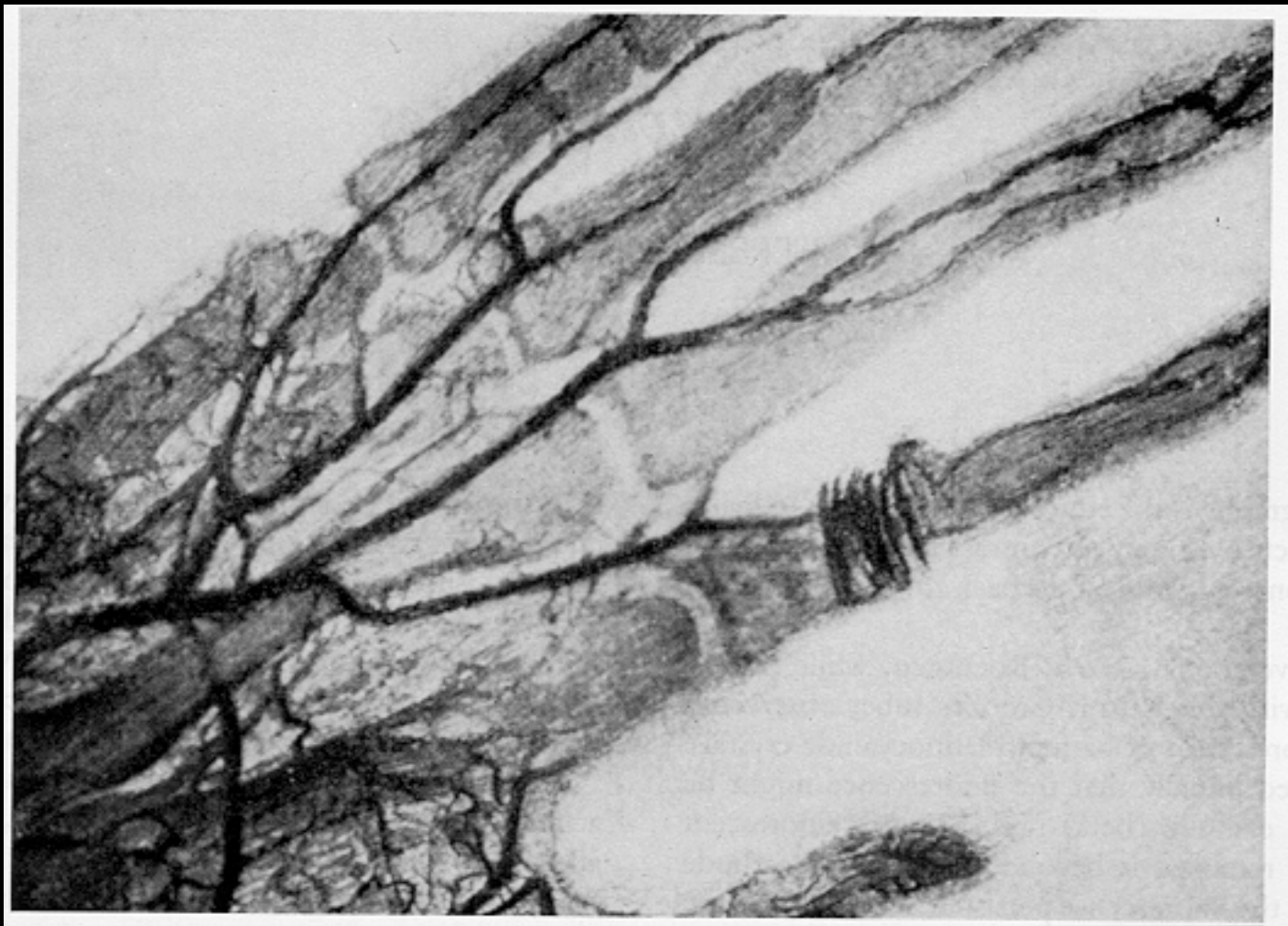
Exame Radiológico Vascular

1. **Angiografia por Subtração Digital**
2. **Angiografia por Tomografia Computadorizada**
3. **Angiografia por Ressonância Magnética**



Exame Radiológico Vascular

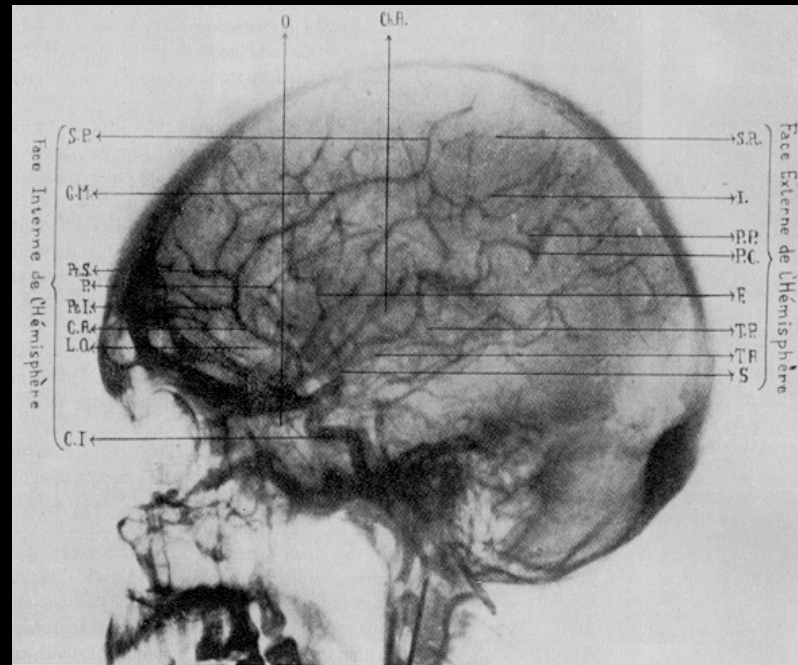
1. **Angiografia por Subtração Digital**
2. **Angiografia por Tomografia Computadorizada**
3. **Angiografia por Ressonância Magnética**

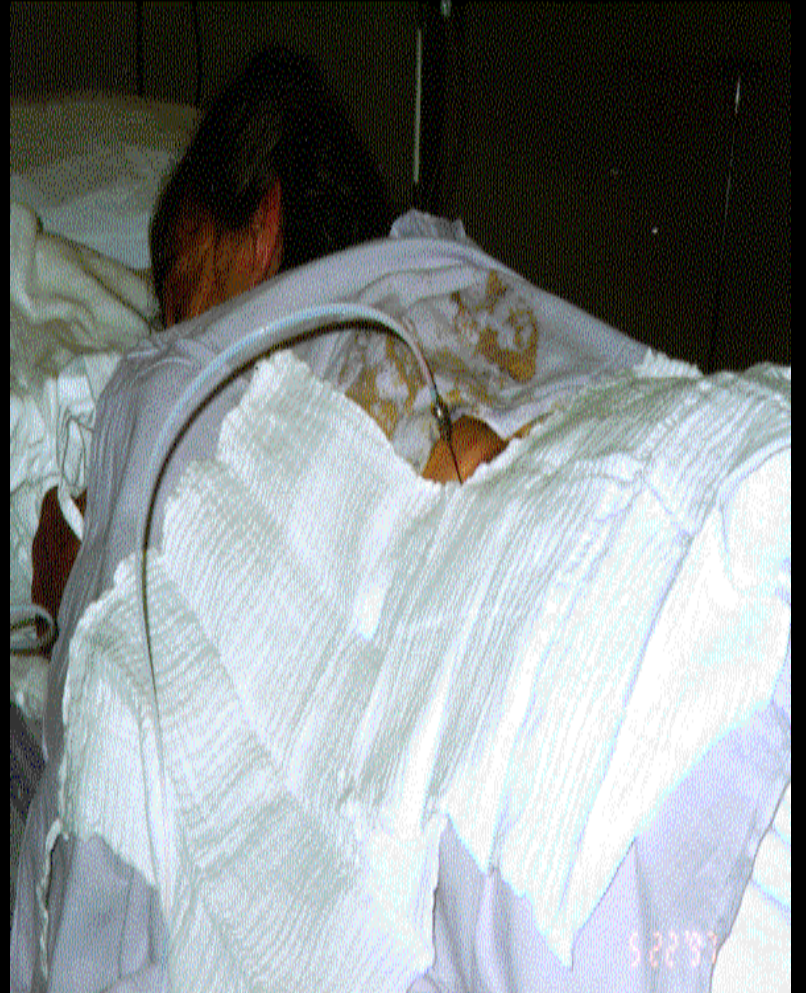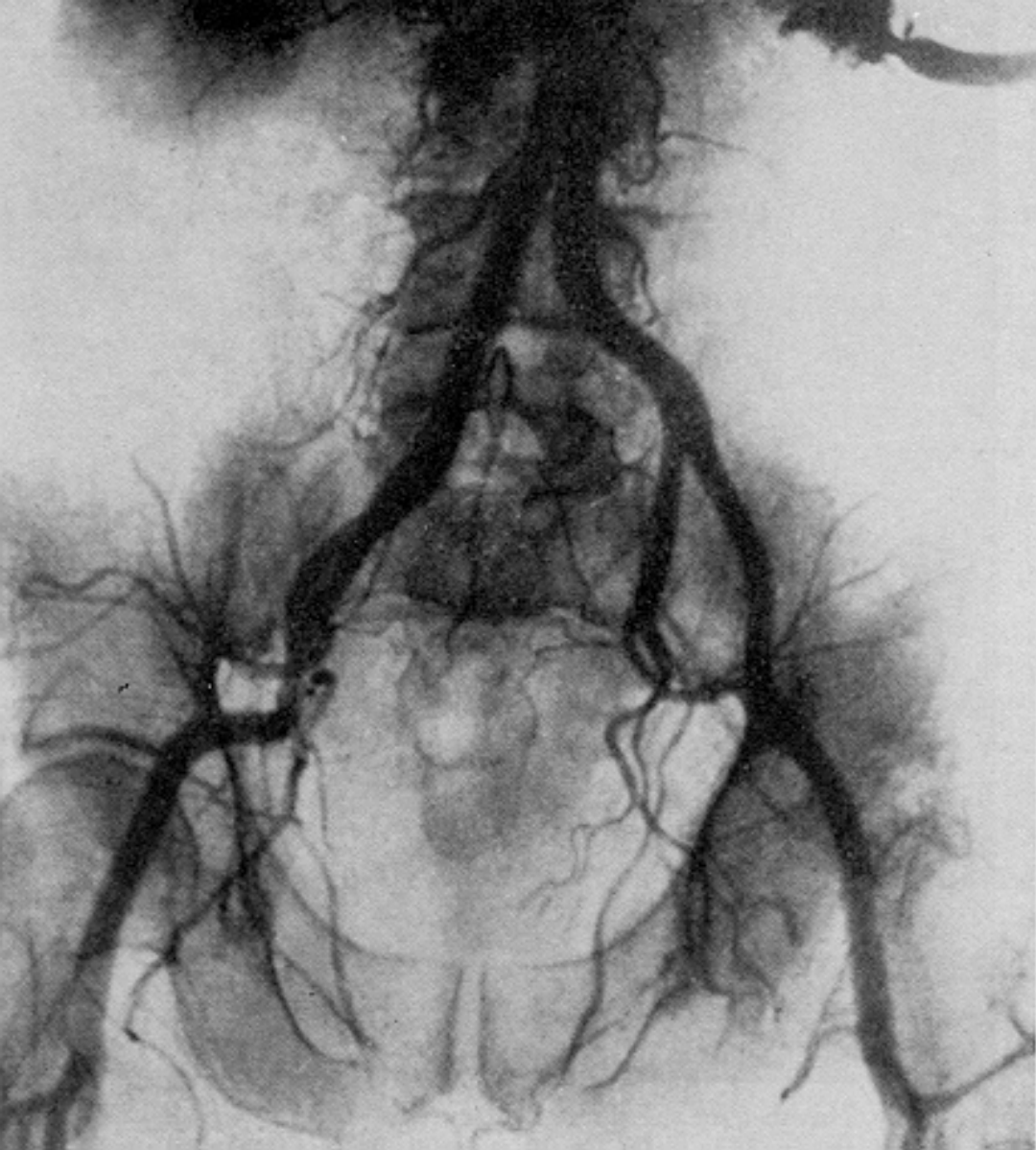


**Injeção de bismuto, prata e bário em uma mão amputada.
Primeira radiografia de vasos.
Haschek E. e Lidenthal O.T. - 1896**

Antônio Egas Muniz

1927: Angiografia cerebral







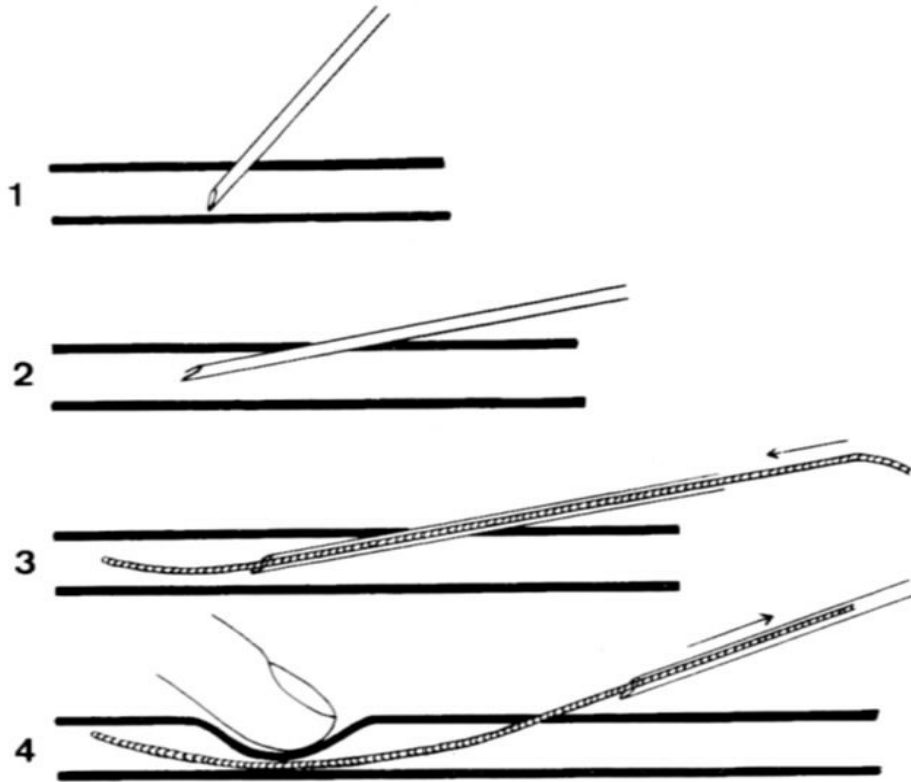
**Primeira aortografia translombar
Dos Santos, Lamas e Pereira-Caldas - 1929**

BIRTH OF A NEW SPECIALTY

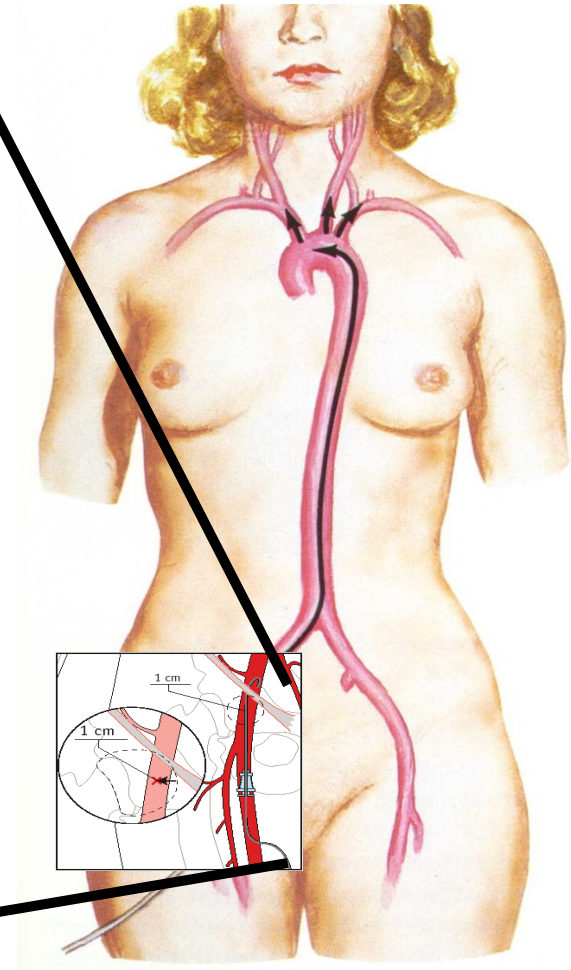
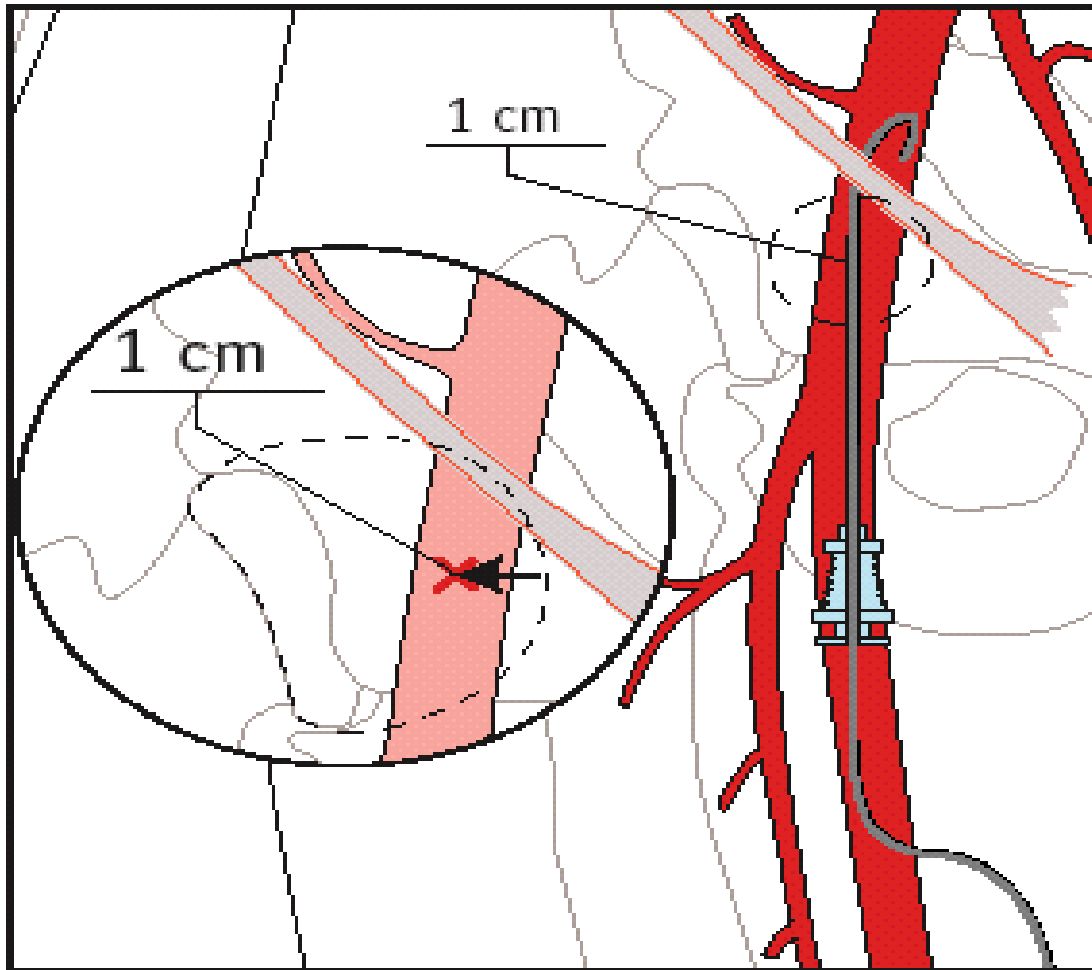
- Sven-Ivar Seldinger MD
- 1953
- Descrição da técnica de Seldinger technique
- Acesso seguro a órgão e vasos



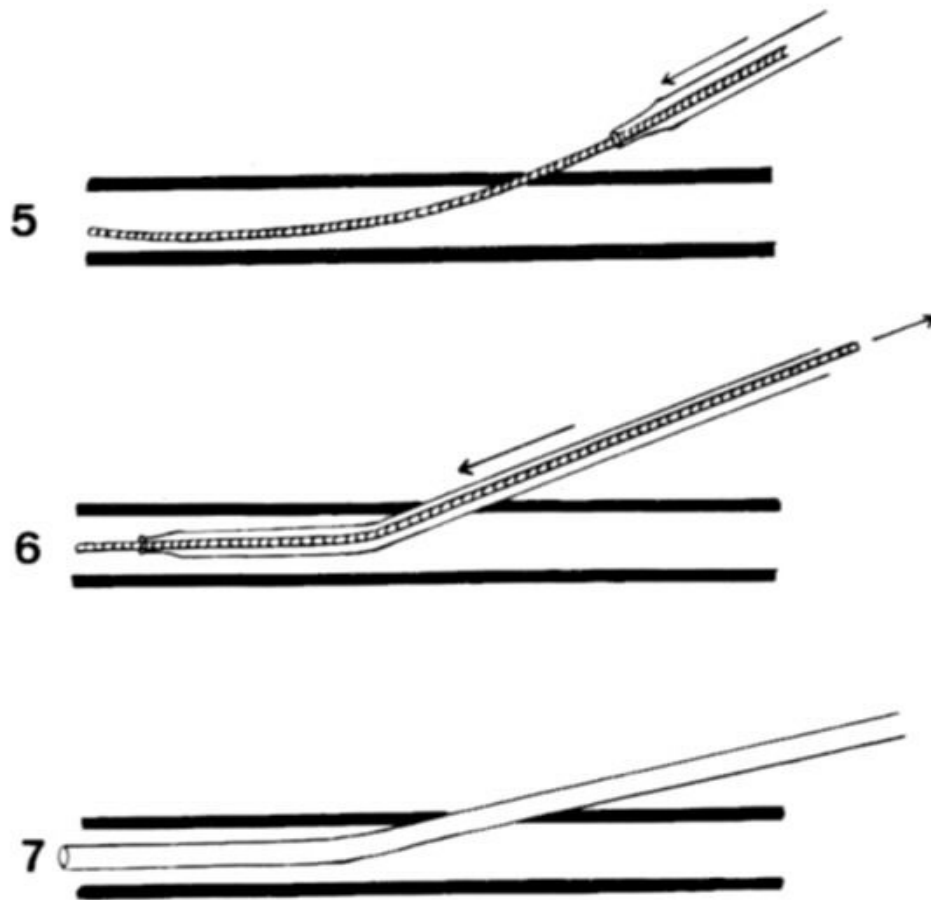
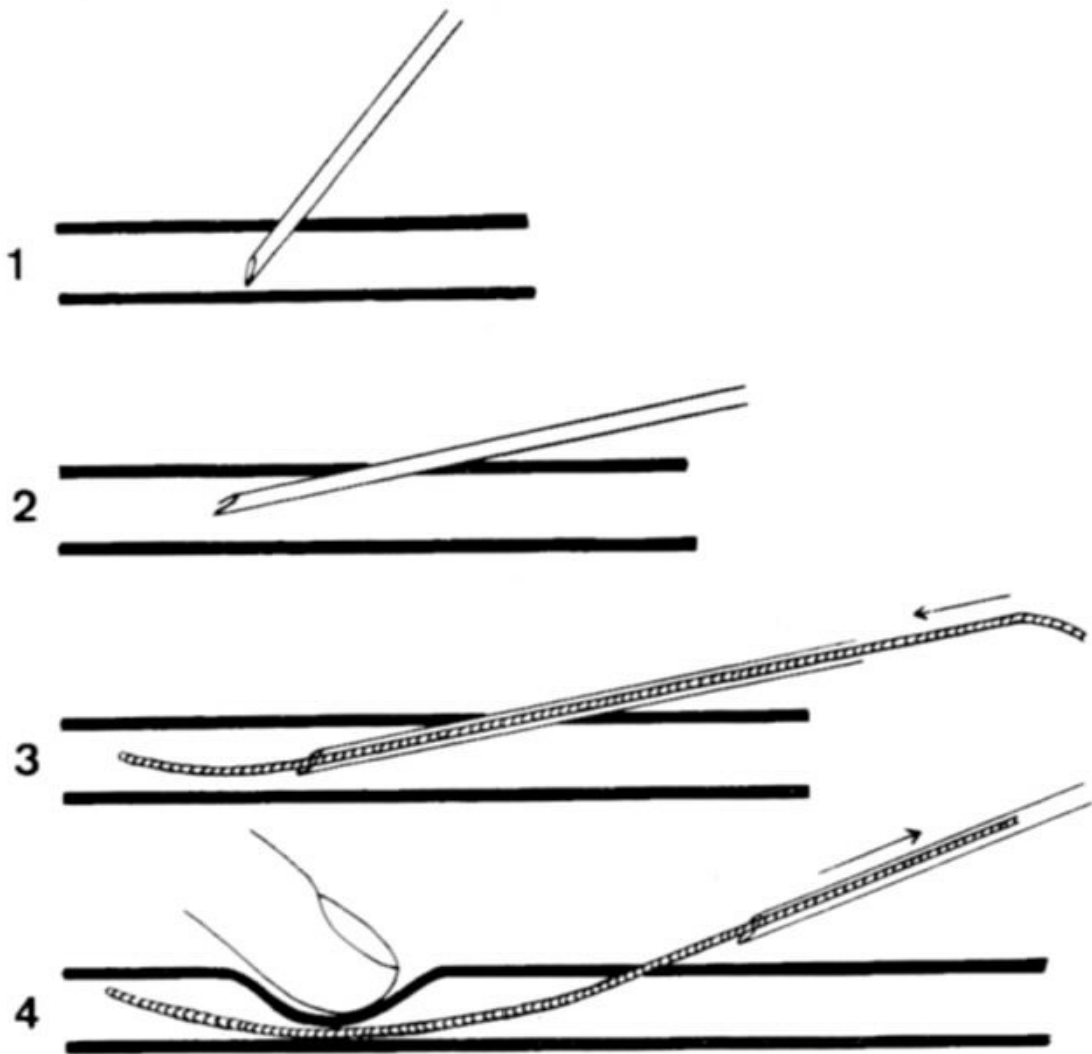
SELDINGER TECHNIQUE



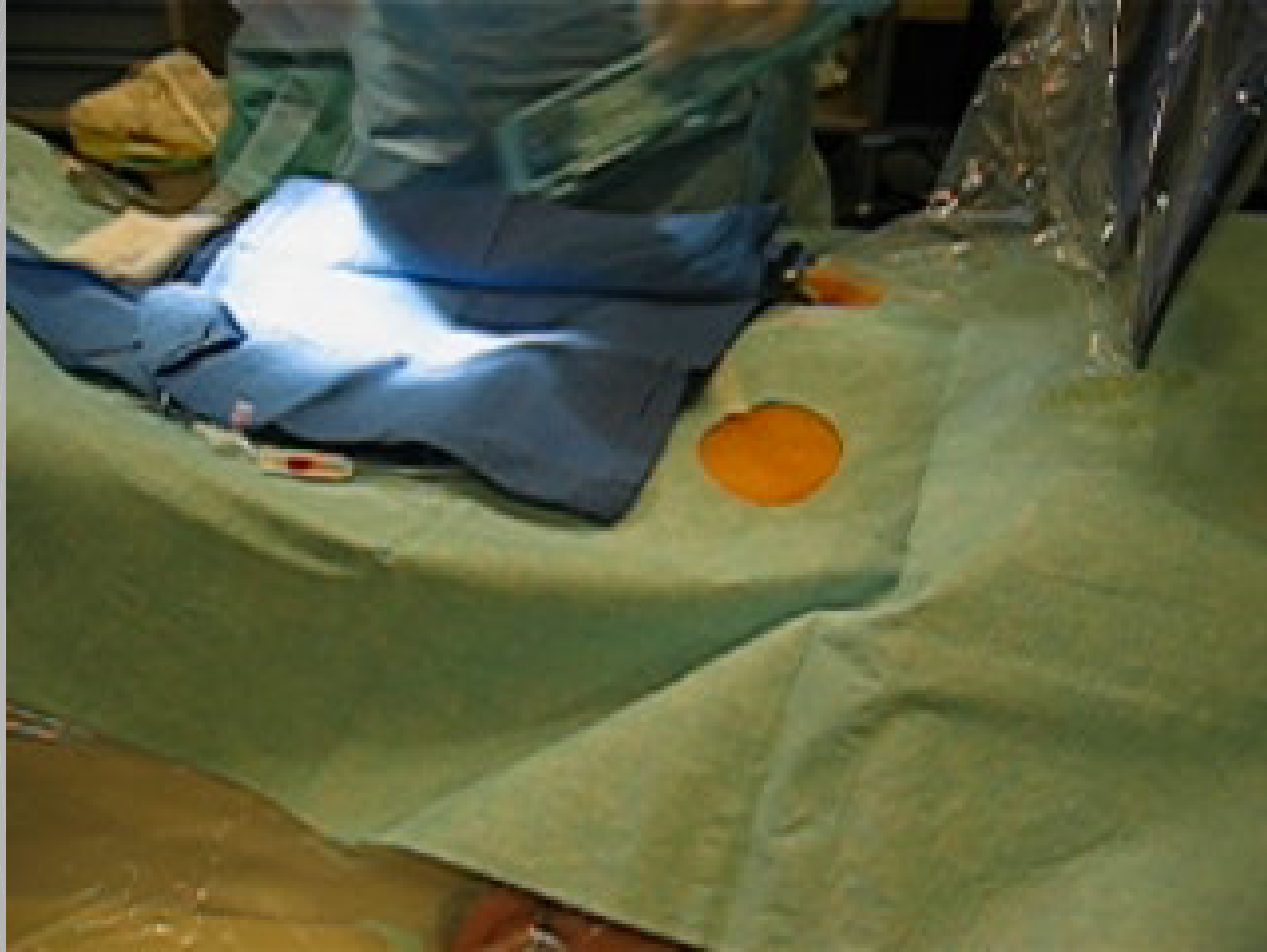
SELDINGER TECHNIQUE



Técnica de Seldinger



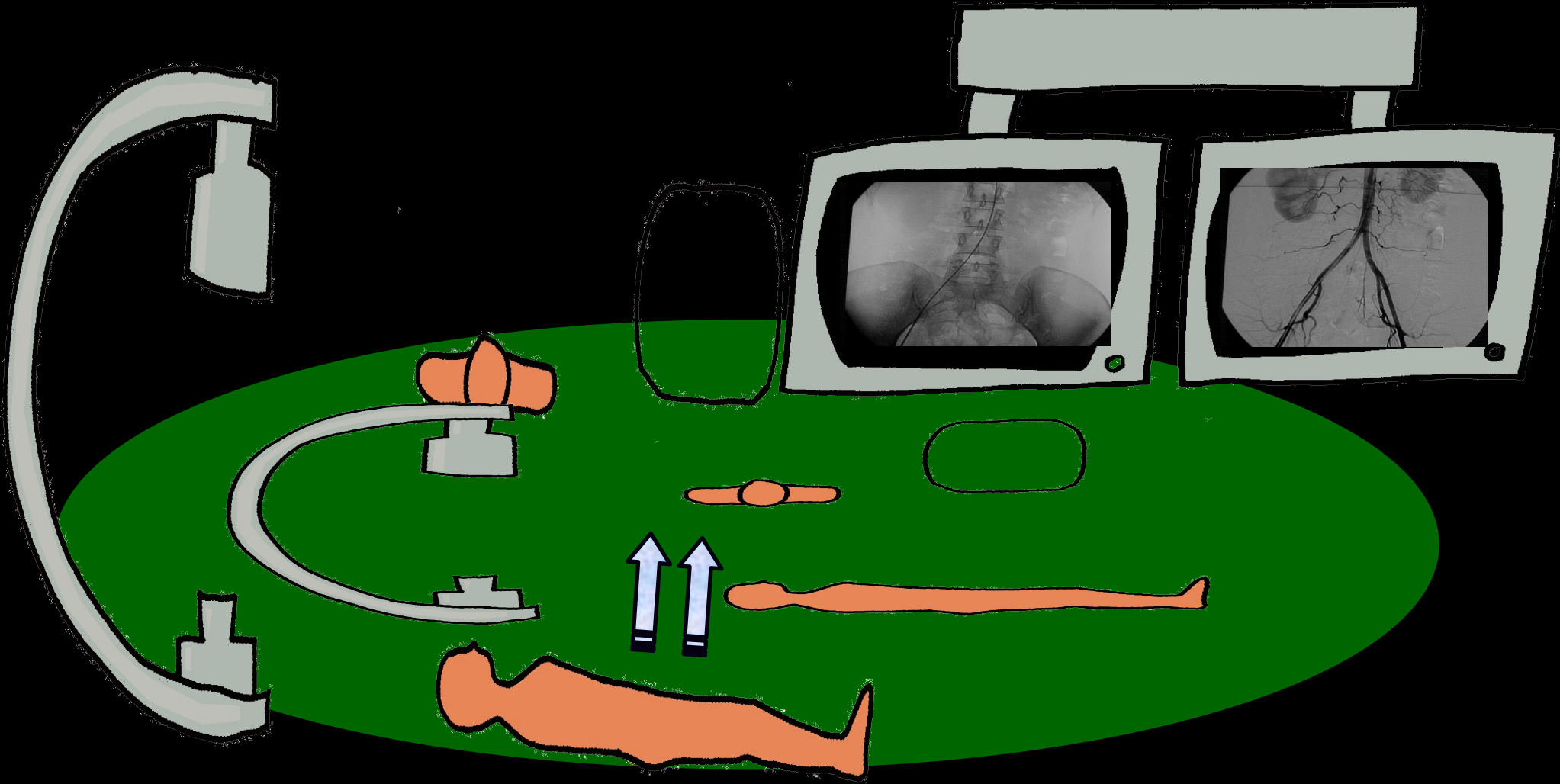
FEMORAL ARTERY ACCESS



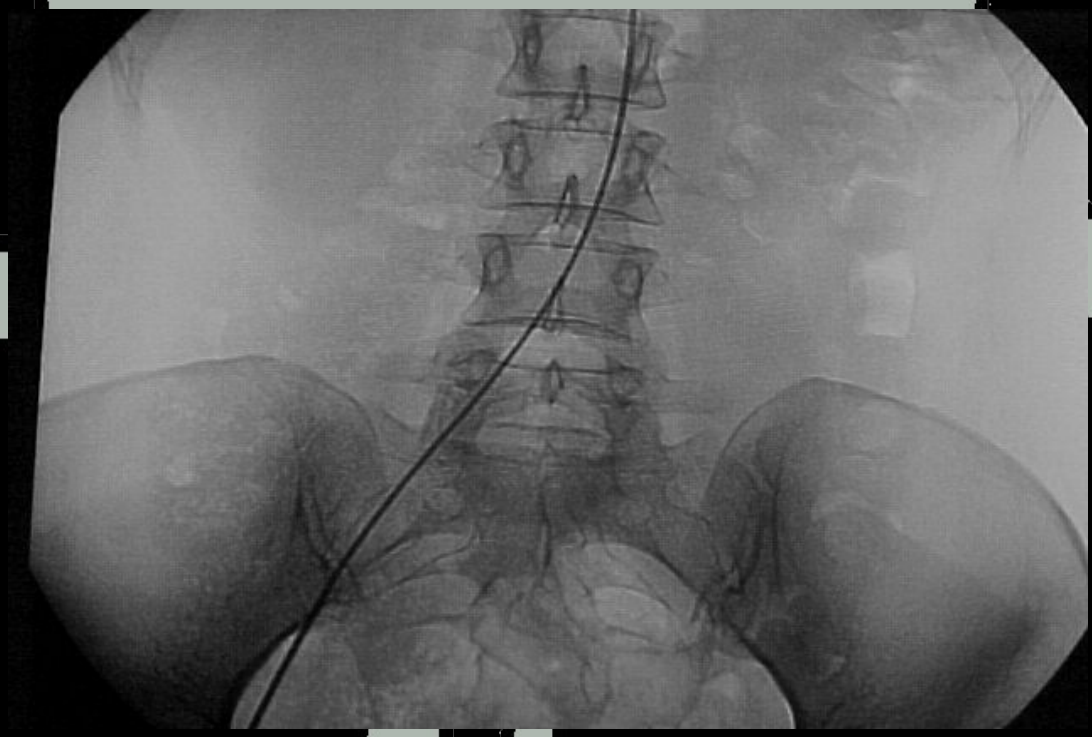
Acessos Arteriais

- **Artéria Femoral Comum**
- **Artéria Braquial**
- **Artéria Radial**
- **Artéria Axilar**
- **Aorta – Punção translombar**

ARTERIOGRAPHY



SEM SUBTRAÇÃO




Os

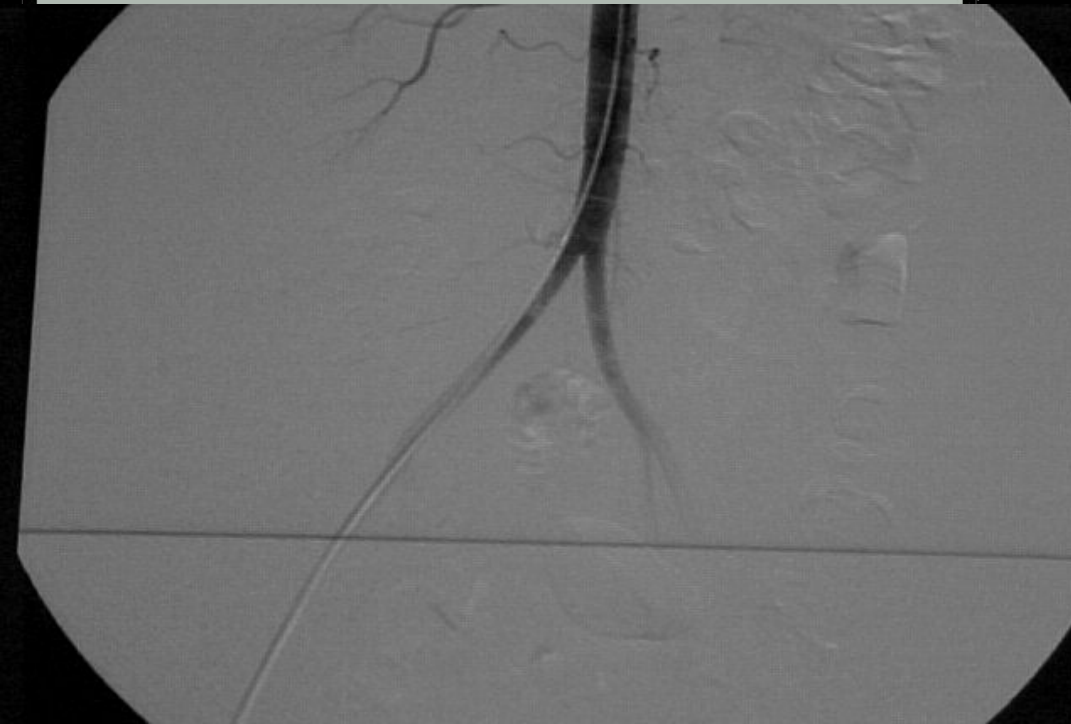


MÁSCARA

1s

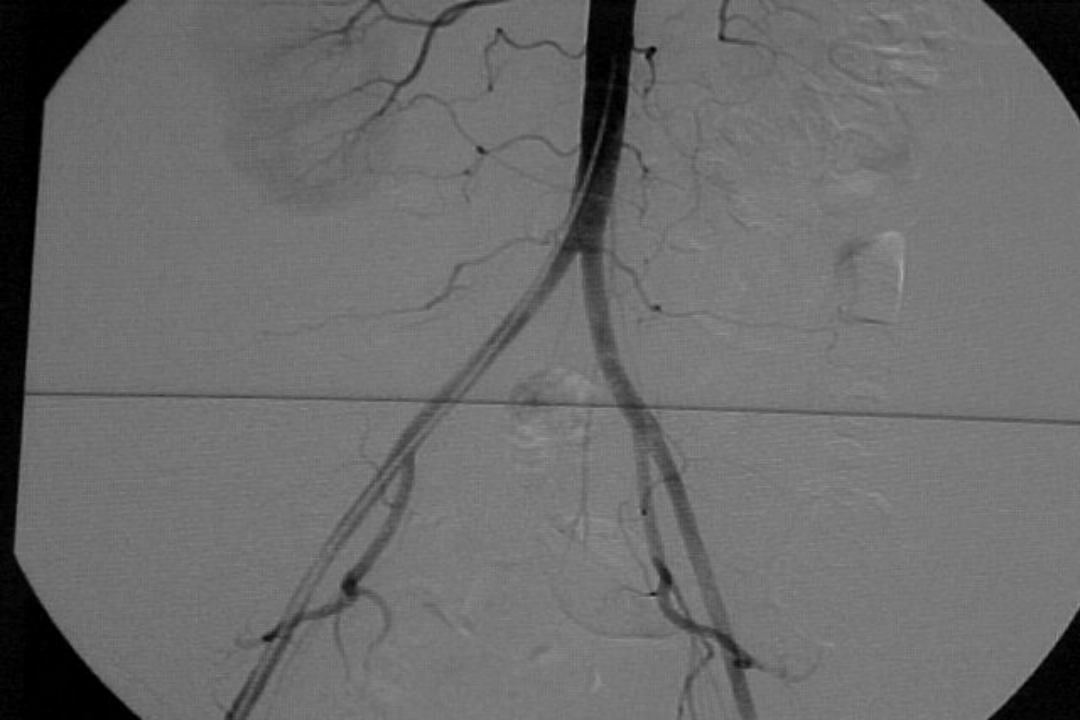

COM SUBTRAÇÃO



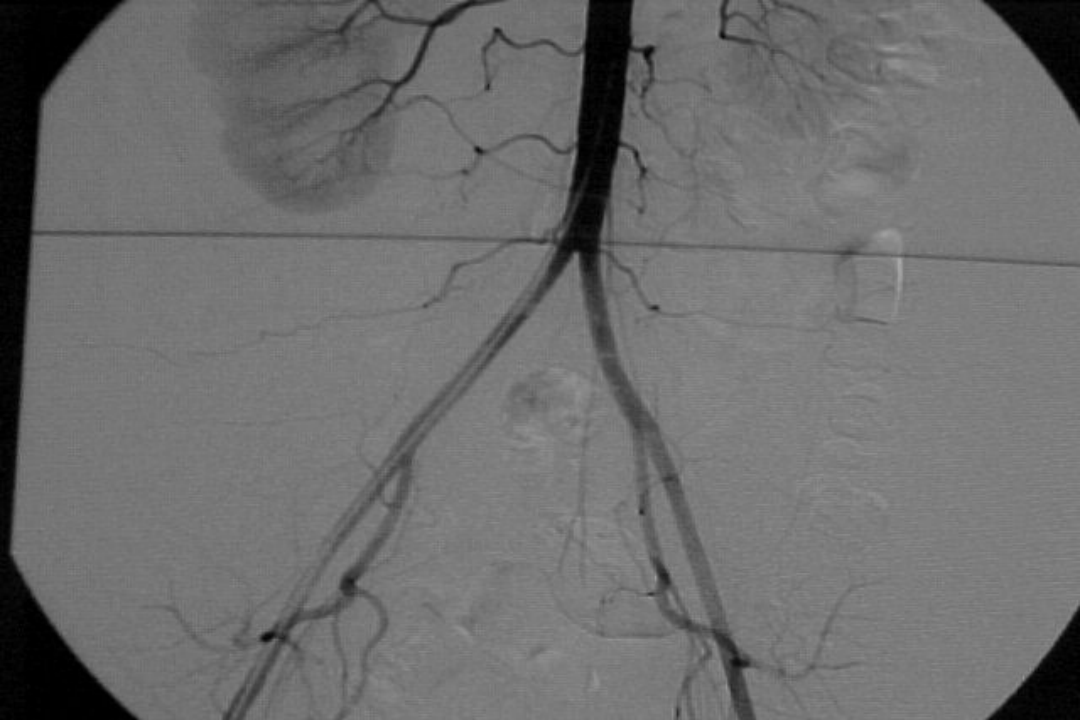2s

[Redacted text]



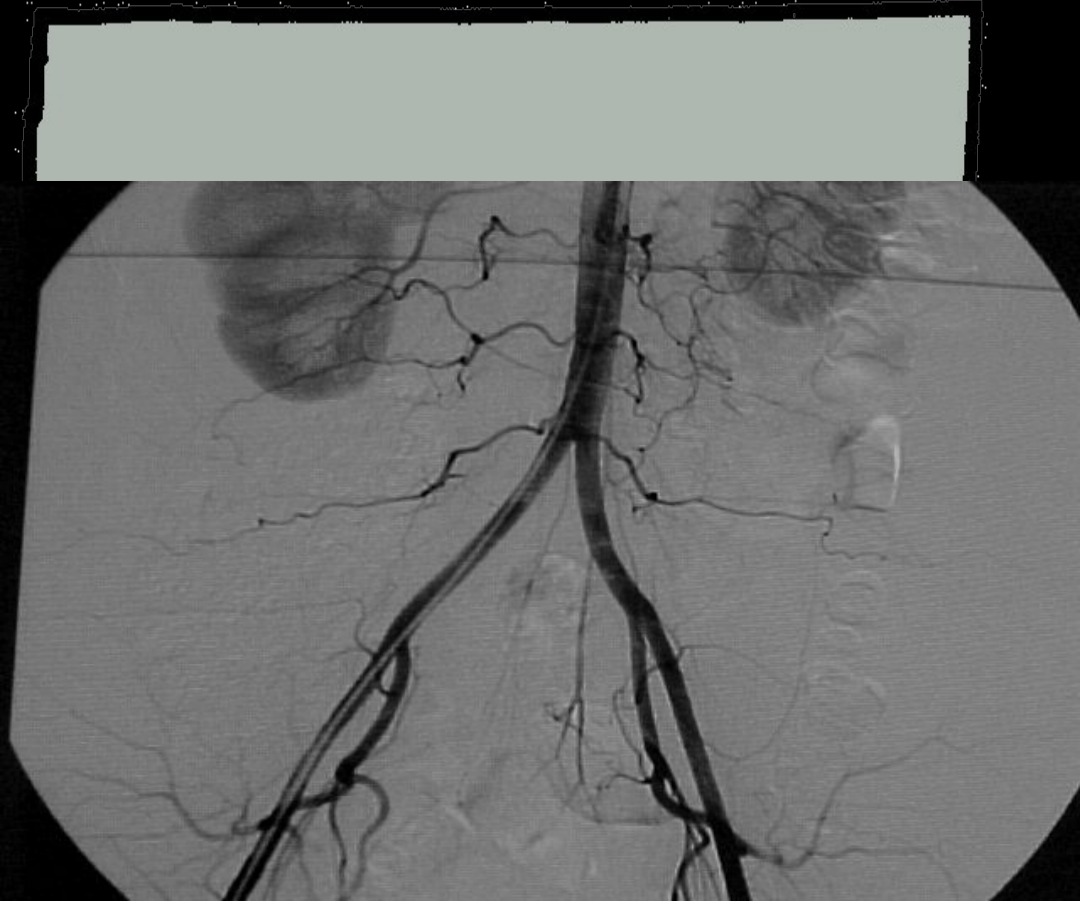3s





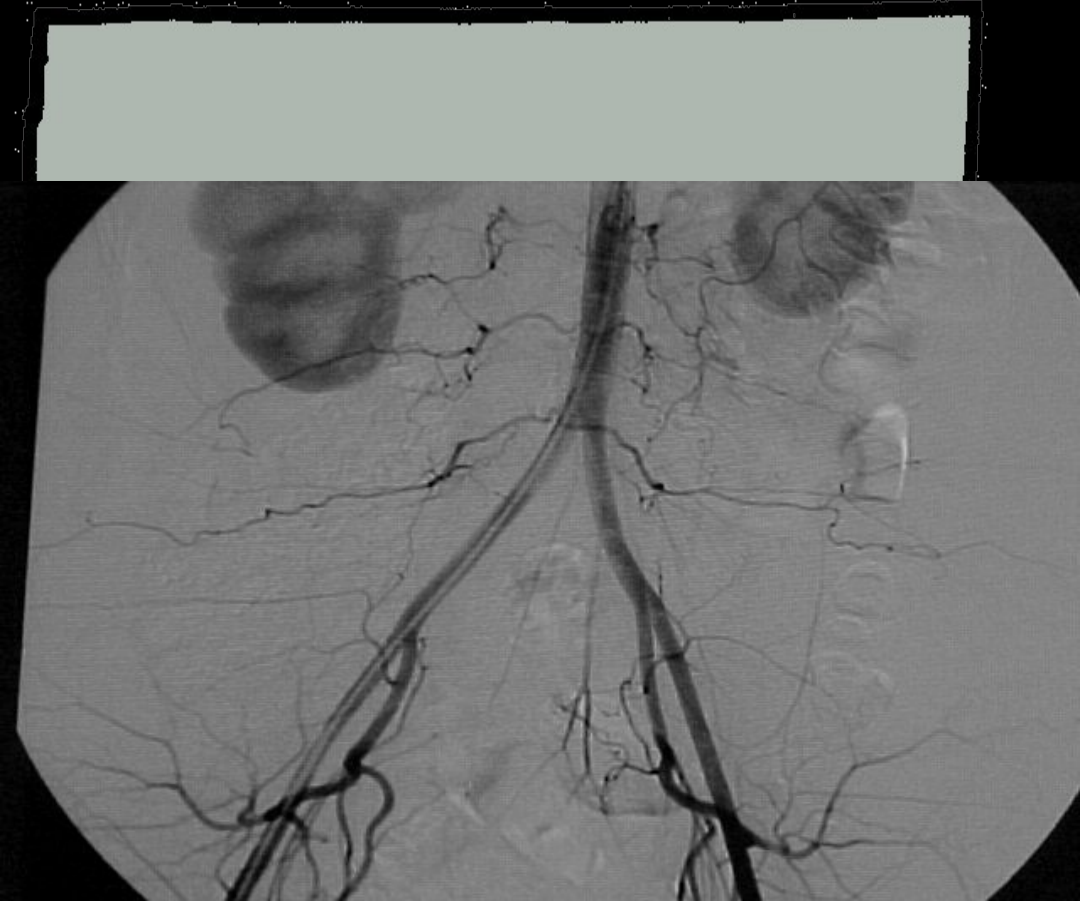4s





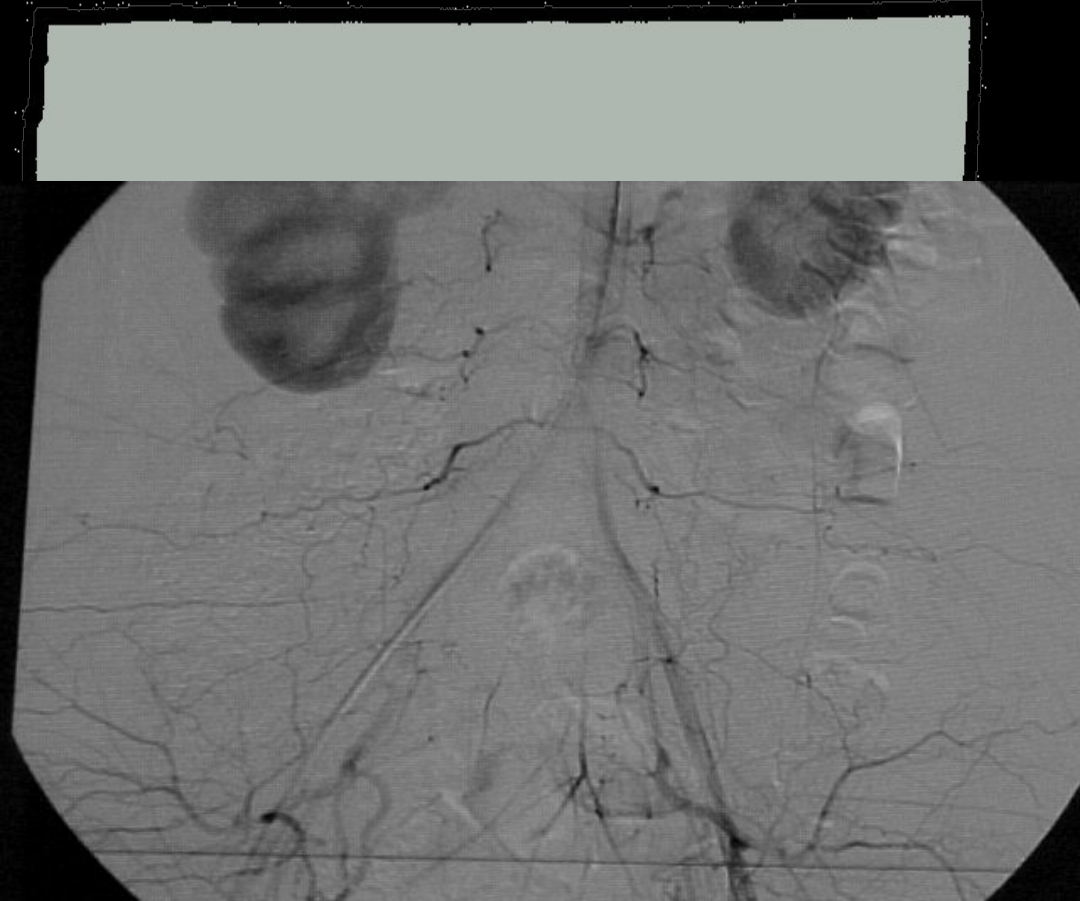5s





6s

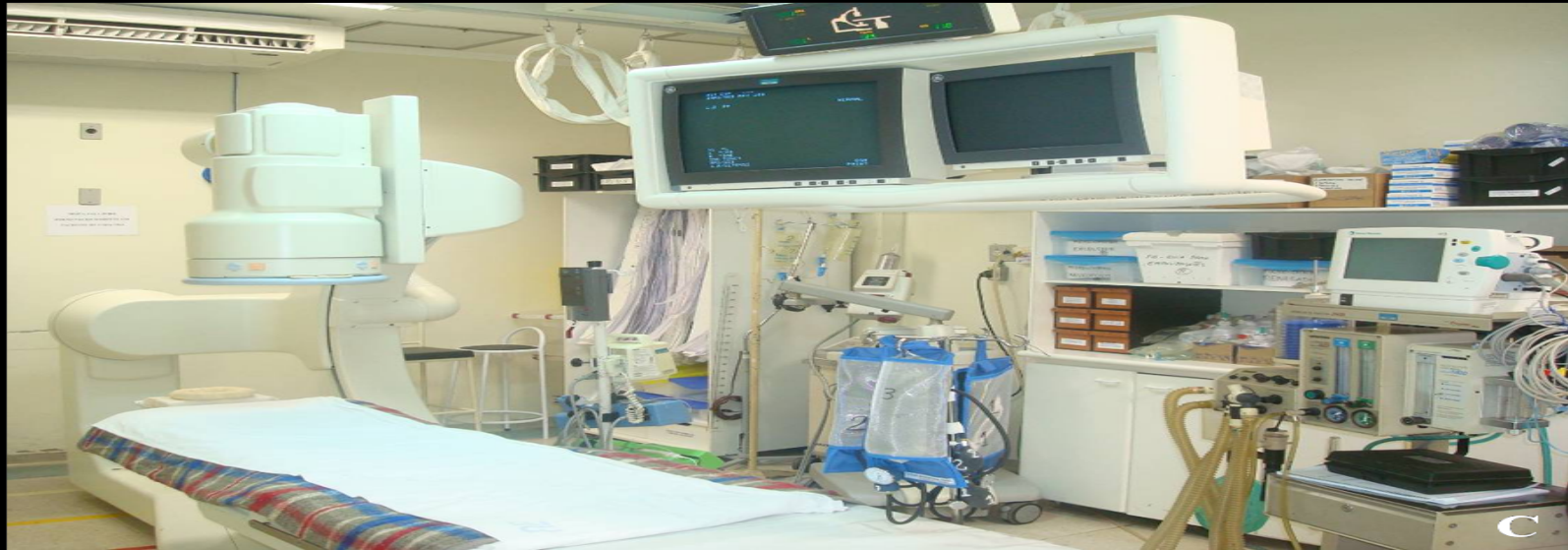


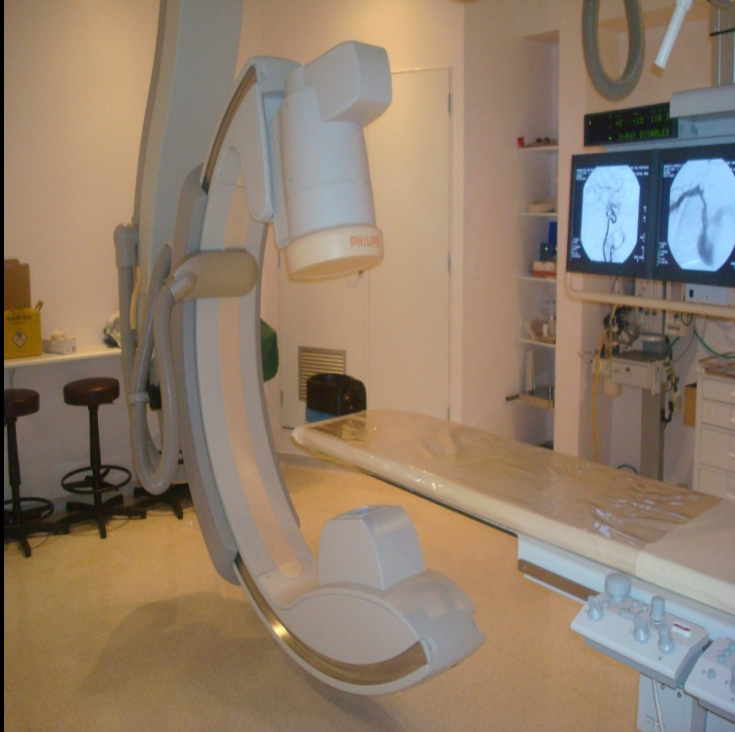
7s

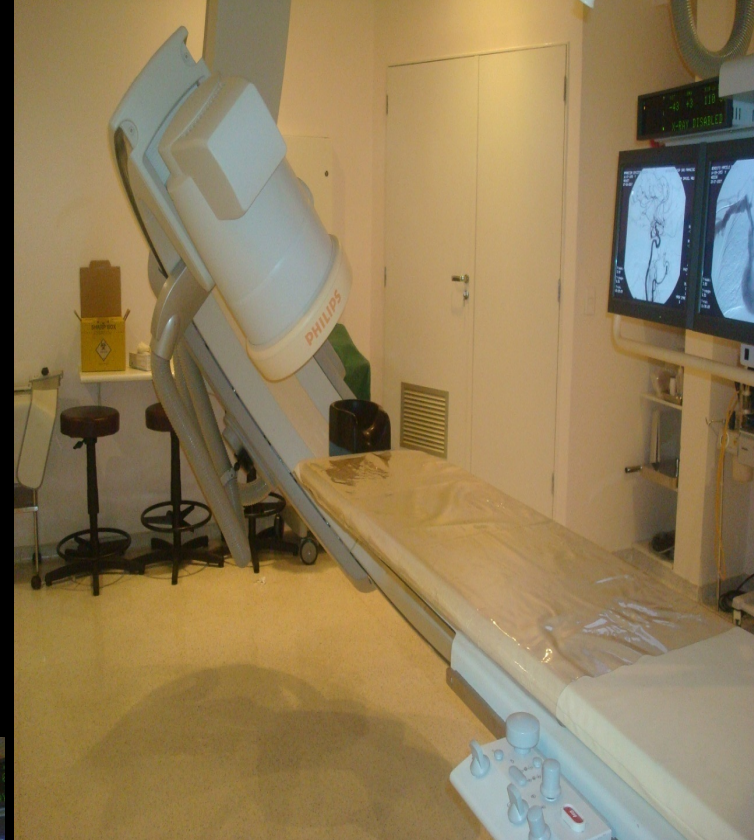

Sala de angiografia HC-UE





AP



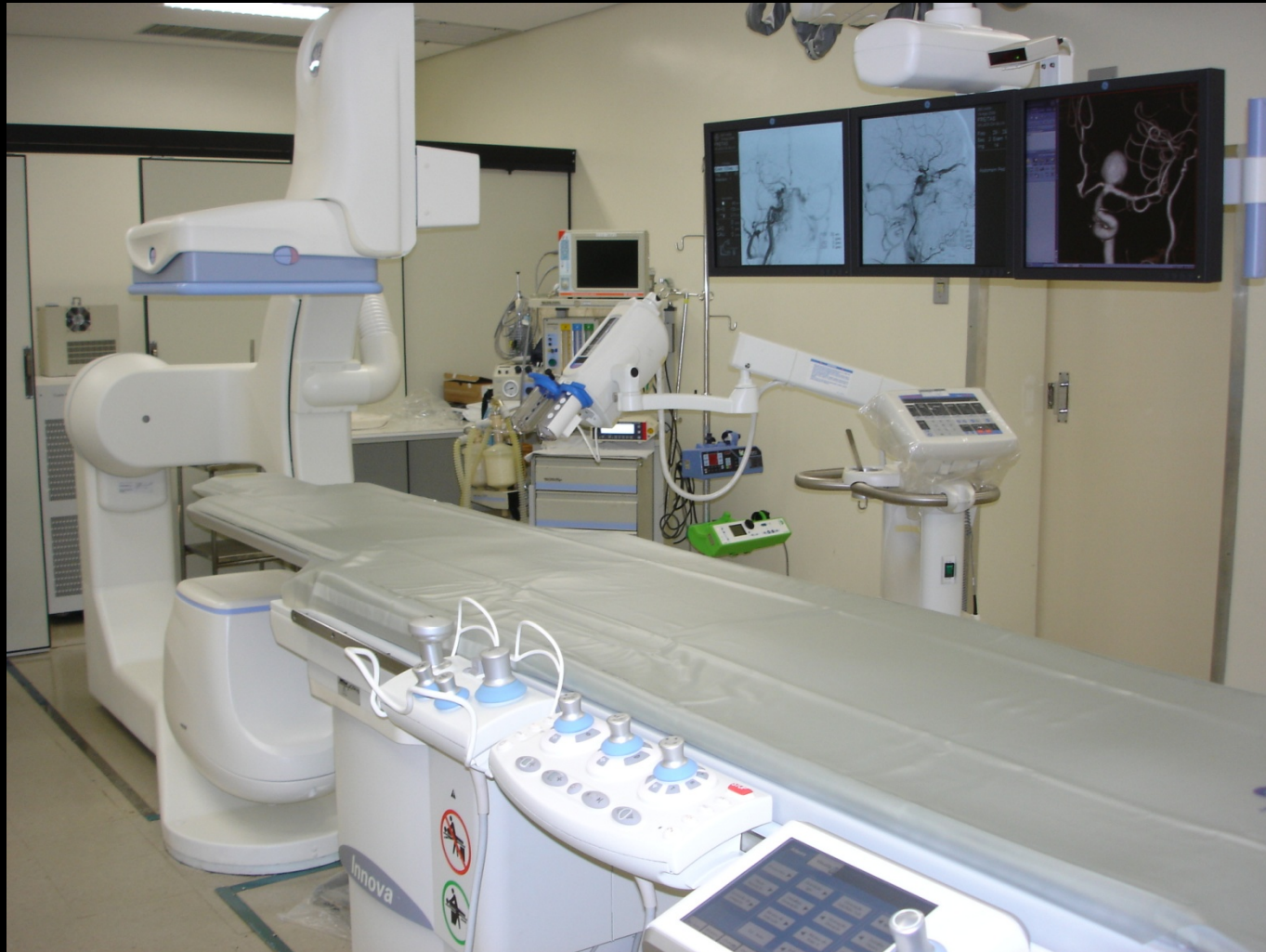OBLÍQUA




PERFIL

HC-FMRP-USP Unidade Campus

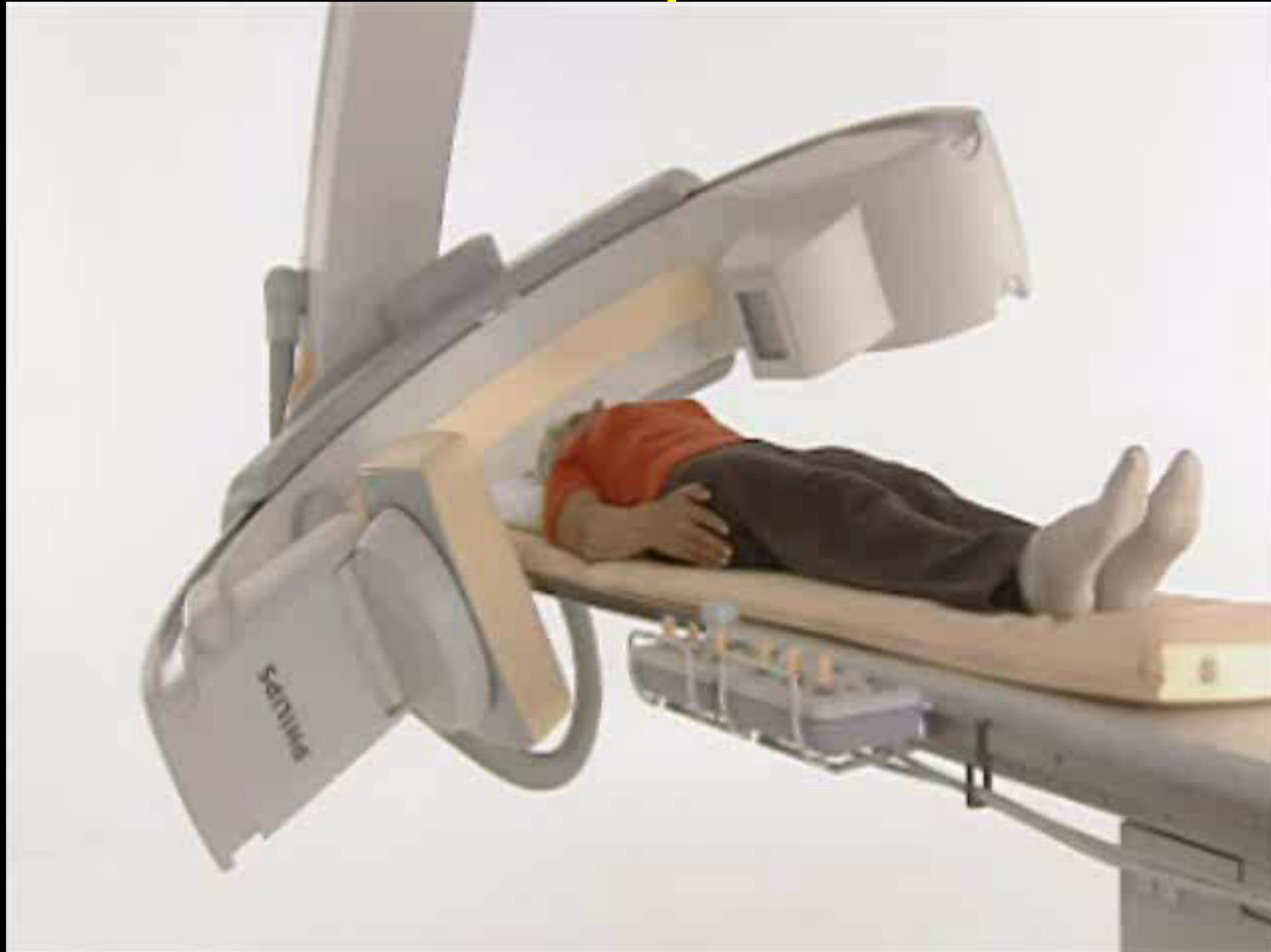Sala de angiografia
Flat Detector



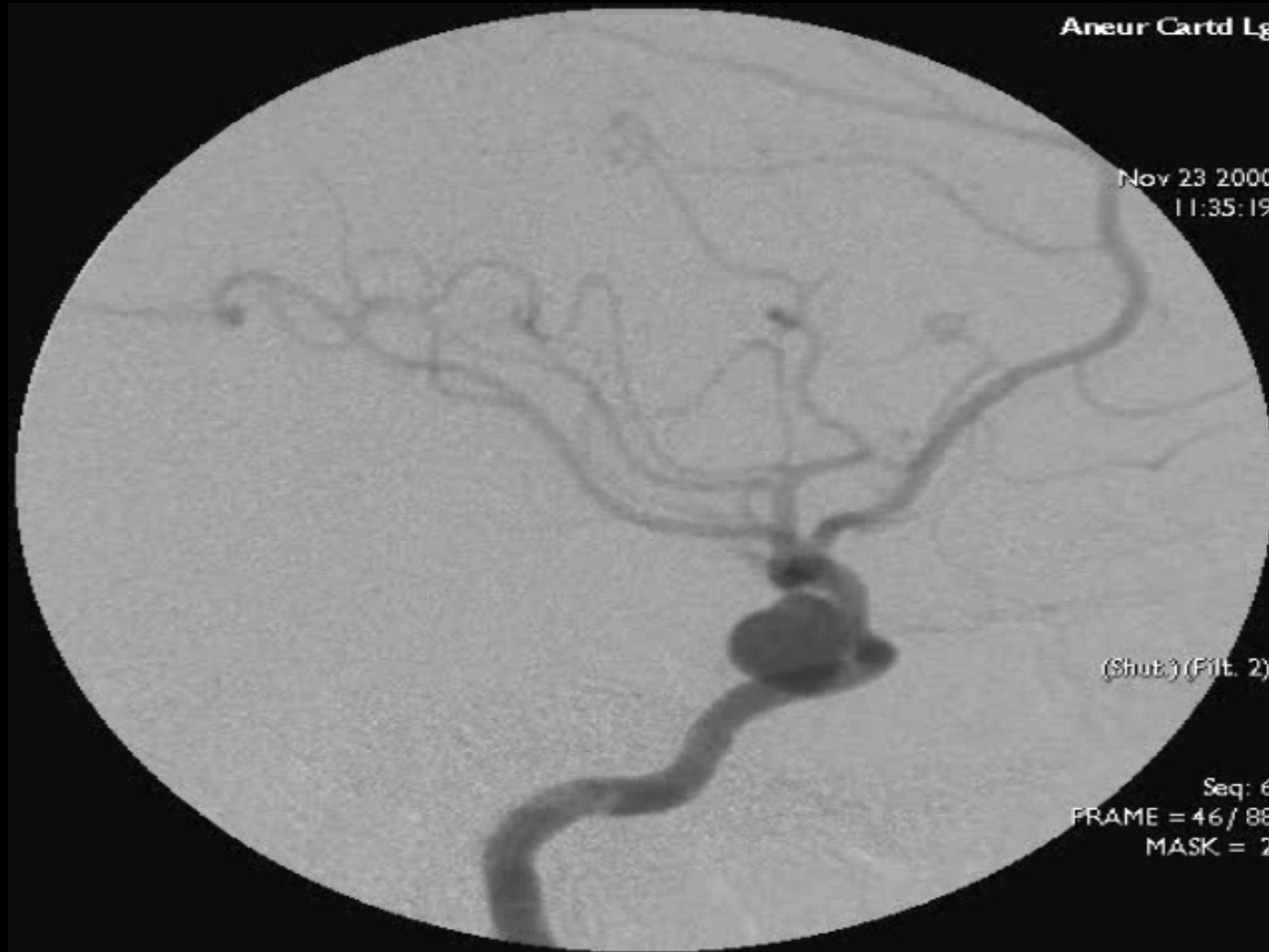Detector convencional x eletrônico digital



Angiografia rotacional com reconstrução 3D



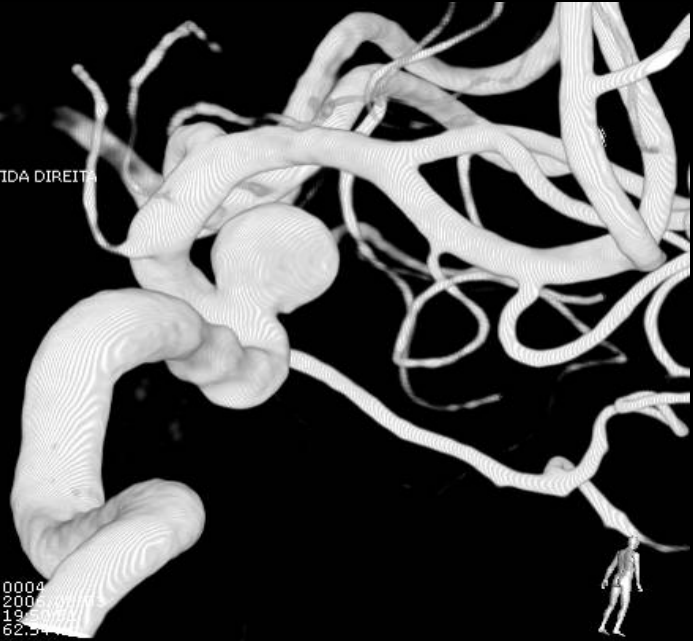Angiografia rotacional com reconstrução 3D



Rot: -135
Ang: 7
Head side

CAROTIDA DIREITA

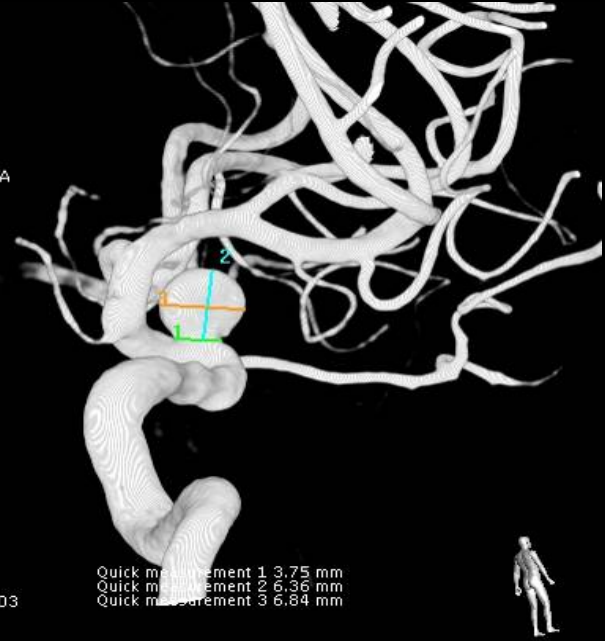
Run number: 0004
Run date: 2006/08/03
Run time: 19:50:51
Cube size: 62.54 mm



Rot: -134
Ang: 6
Head side

CAROTIDA DIREITA

Run number: 0004
Run date: 2006/08/03
Run time: 19:50:51
Cube size: 62.54 mm

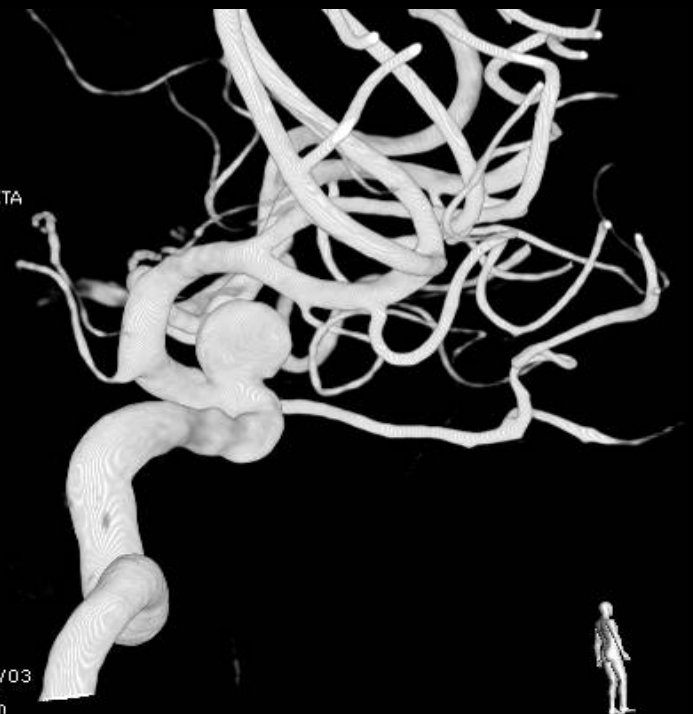

Quick measurement 1 1.375 mm
Quick measurement 2 6.36 mm
Quick measurement 3 6.84 mm

Rot: -119
Ang: 5
Head side

CAROTIDA DIREITA

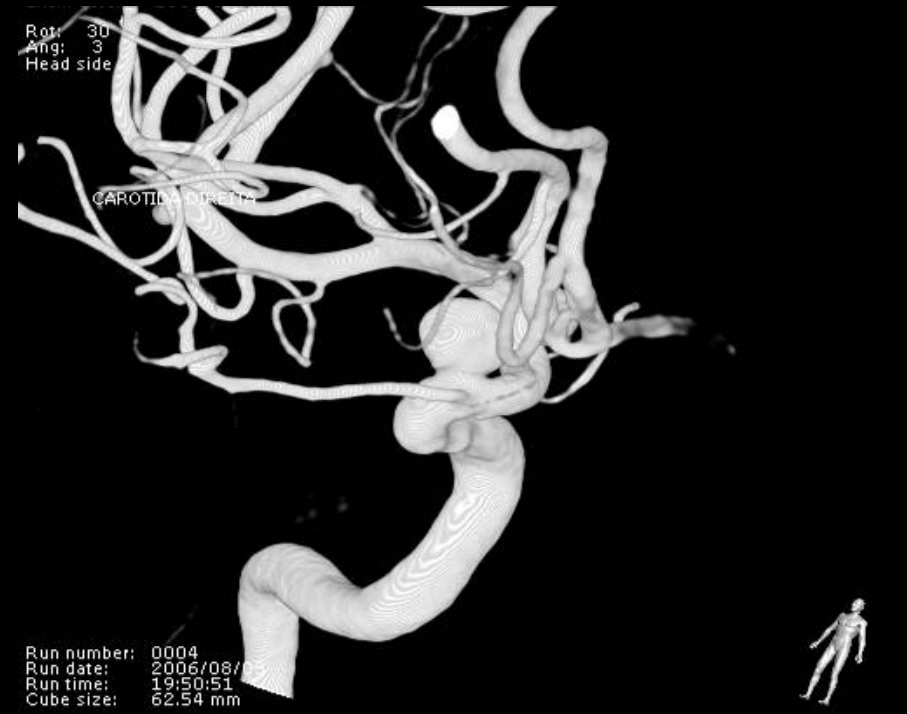Run number: 0004
Run date: 2006/08/03
Run time: 19:50:51
Cube size: 62.54 mm



Rot: 30
Ang: 3
Head side

CAROTIDA DIREITA

Run number: 0004
Run date: 2006/08/03
Run time: 19:50:51
Cube size: 62.54 mm

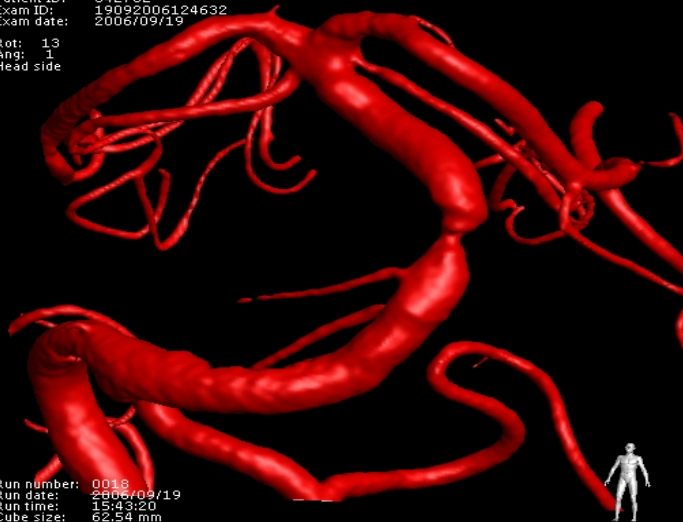


Angiografia rotacional com reconstrução 3D

MANOEL R.P.GUTIERREZ
Date of Birth: 1945/09/26 , Male
Patient ID: 342702
Exam ID: 19092006124632
Exam date: 2006/09/19

DOCUMENTA HOSP SAO FRANCISCO
DR DANIEL ABUD

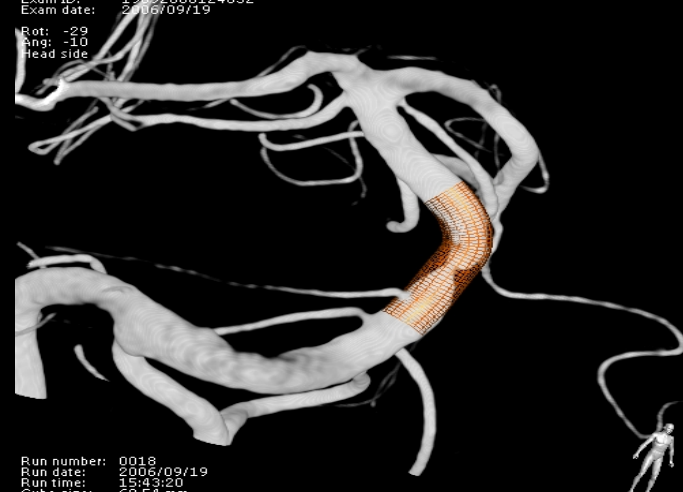Rot: 13
Ang: 1
Head side



MANOEL R.P.GUTIERREZ
Date of Birth: 1945/09/26 , Male
Patient ID: 342702
Exam ID: 19092006124632
Exam date: 2006/09/19

DOCUMENTA HOSP SAO FRANCISCO
DR DANIEL ABUD

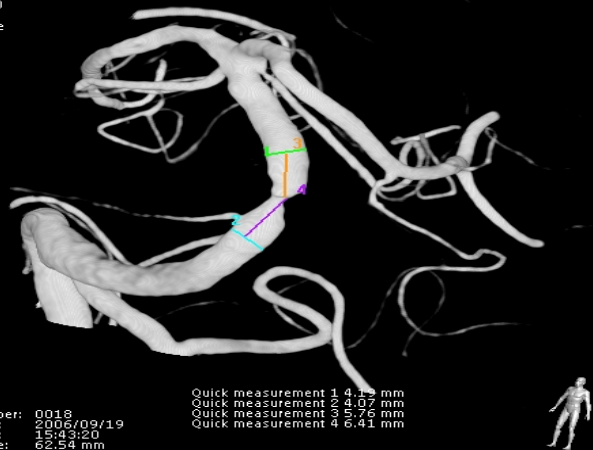Rot: -29
Ang: -10
Head side



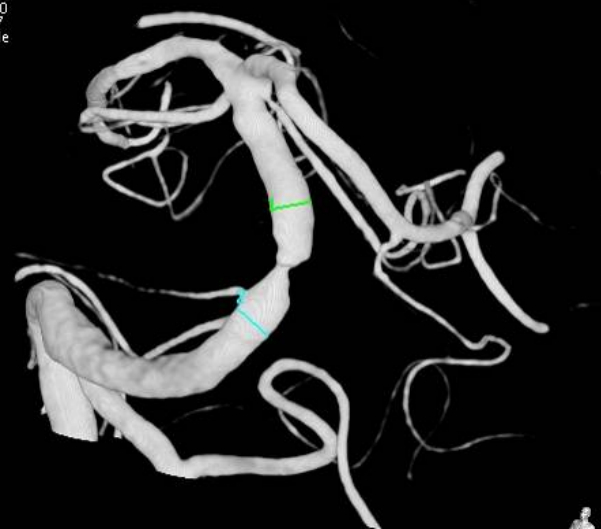MANOEL R.P.GUTIERREZ
Date of Birth: 1945/09/26 , Male
Patient ID: 342702
Exam ID: 19092006124632
Exam date: 2006/09/19

DOCUMENTA HOSP SAO FRANCISCO
DR DANIEL ABUD

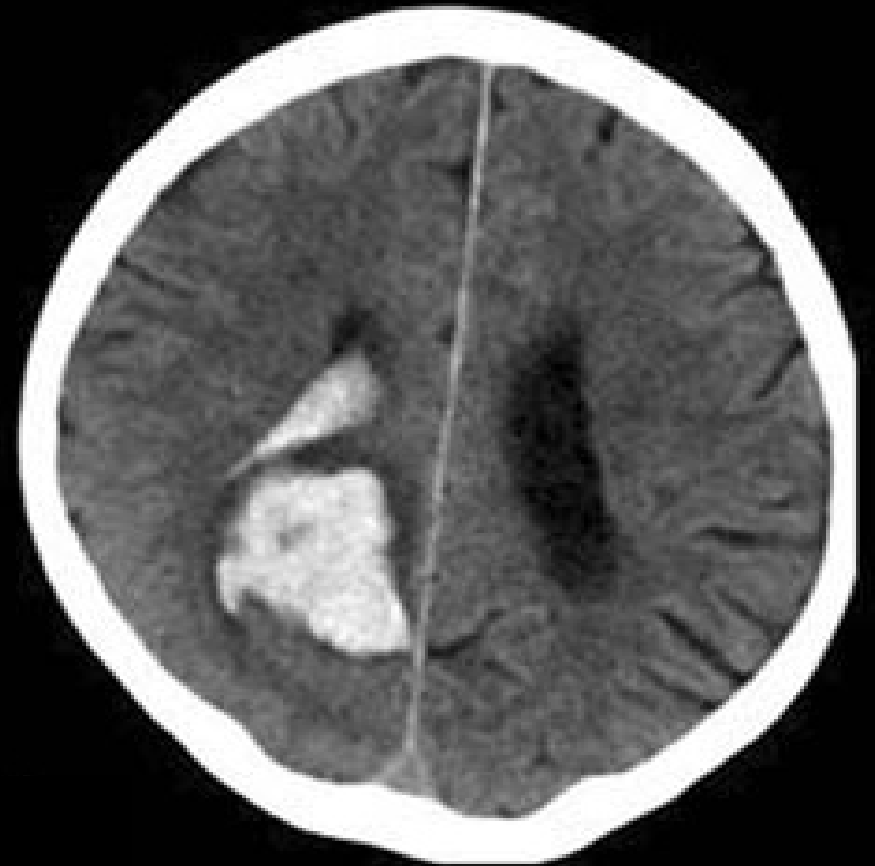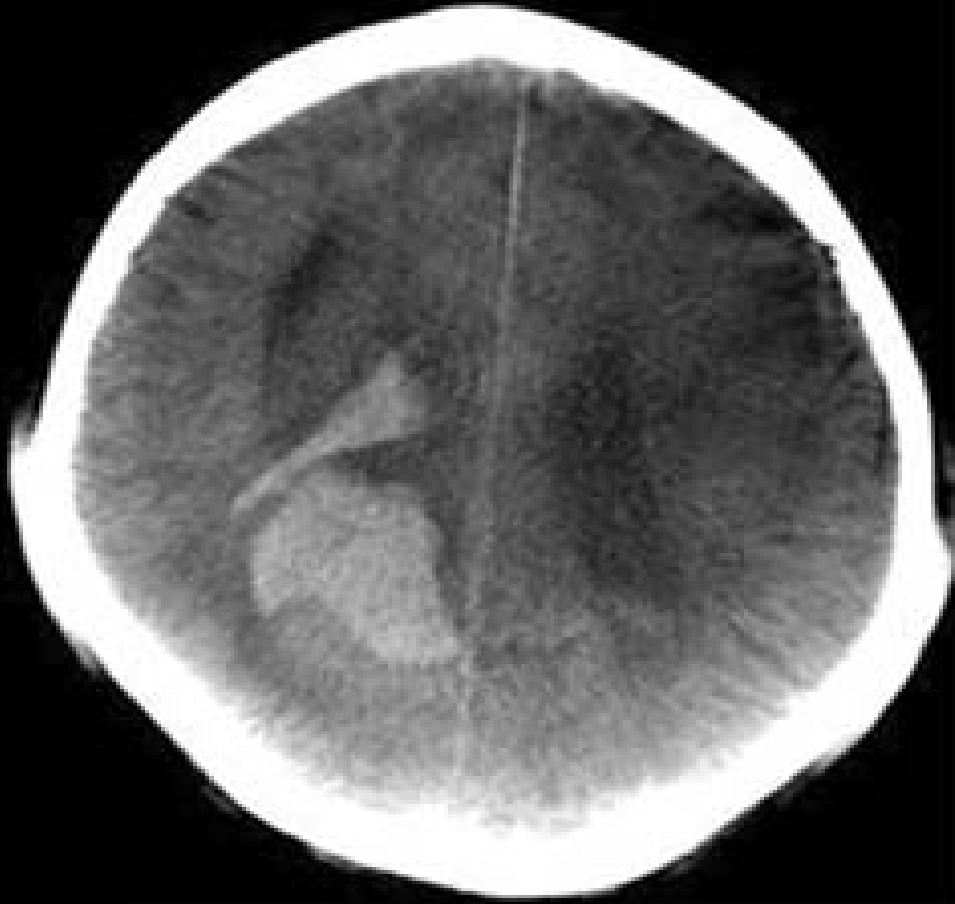Rot: 30
Ang: -7
Head side




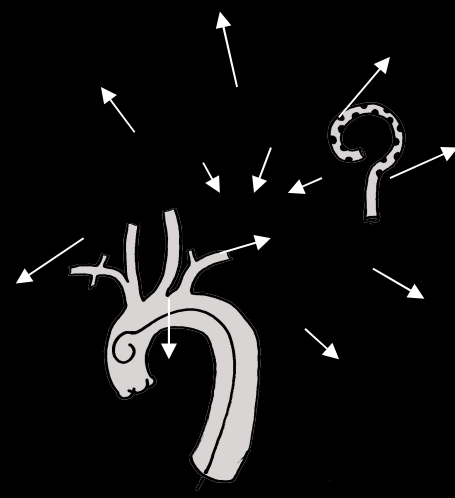
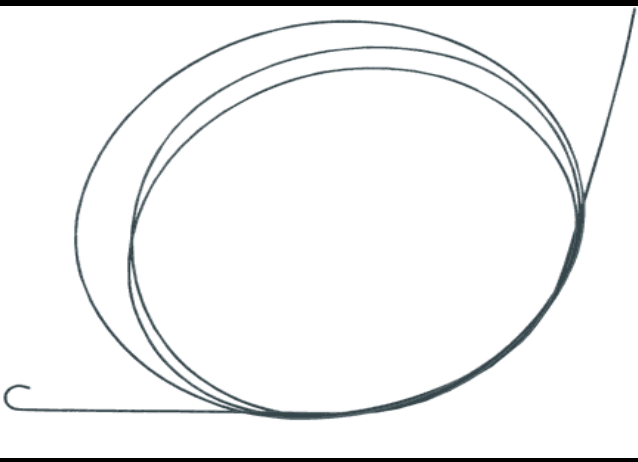



Rot: 30
Ang: -7
Head side




CT Like





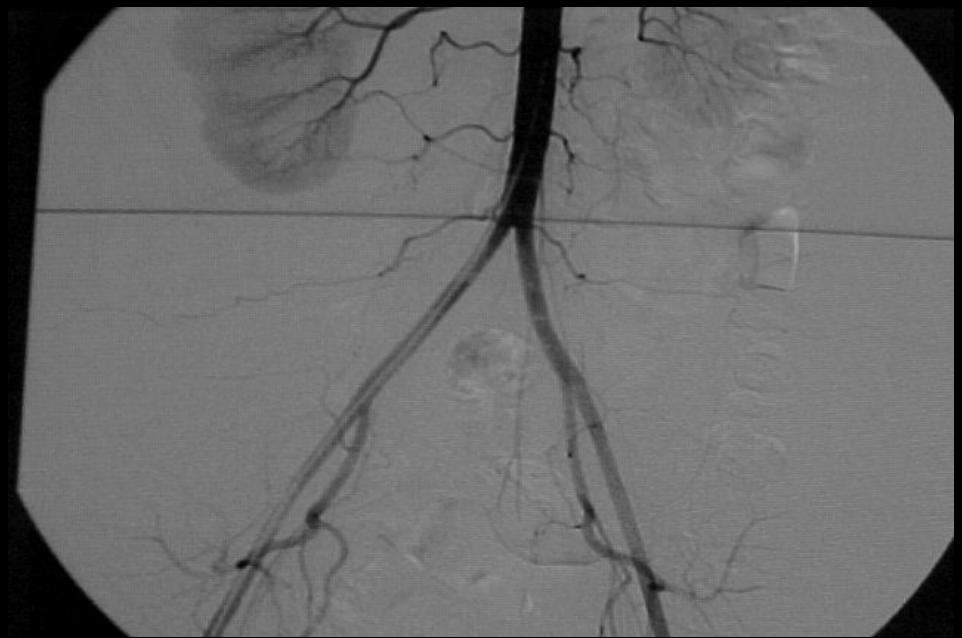
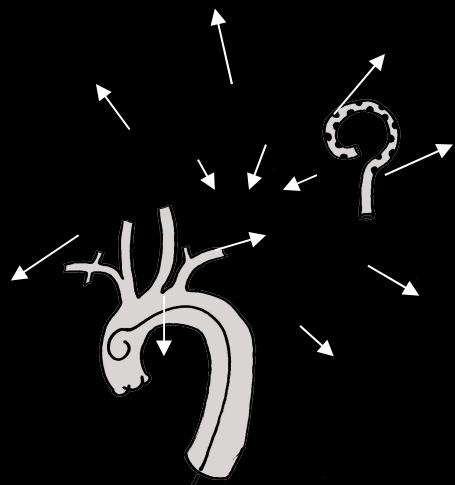
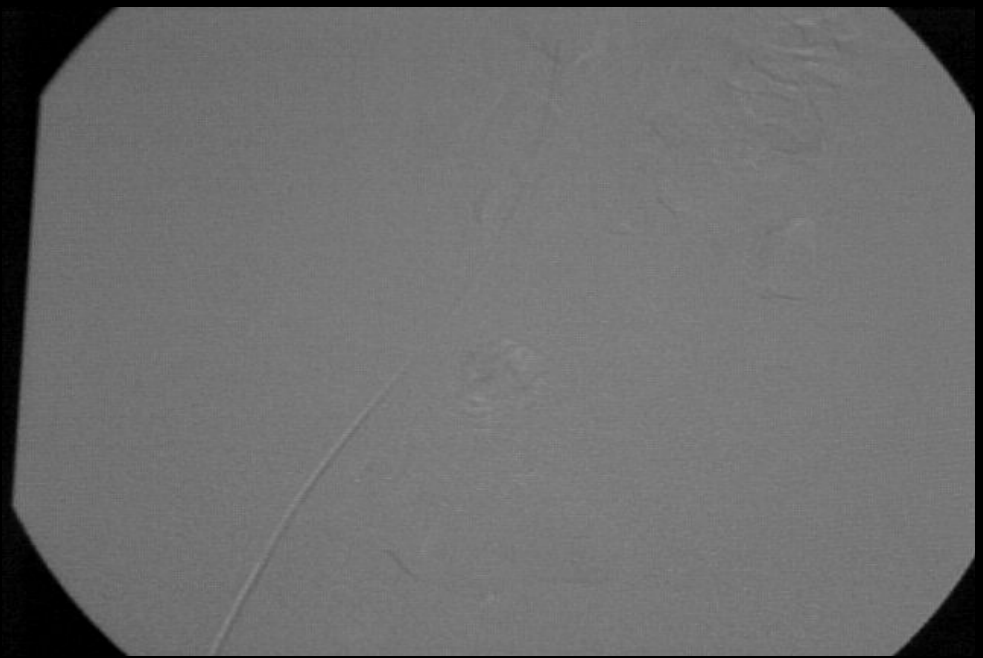
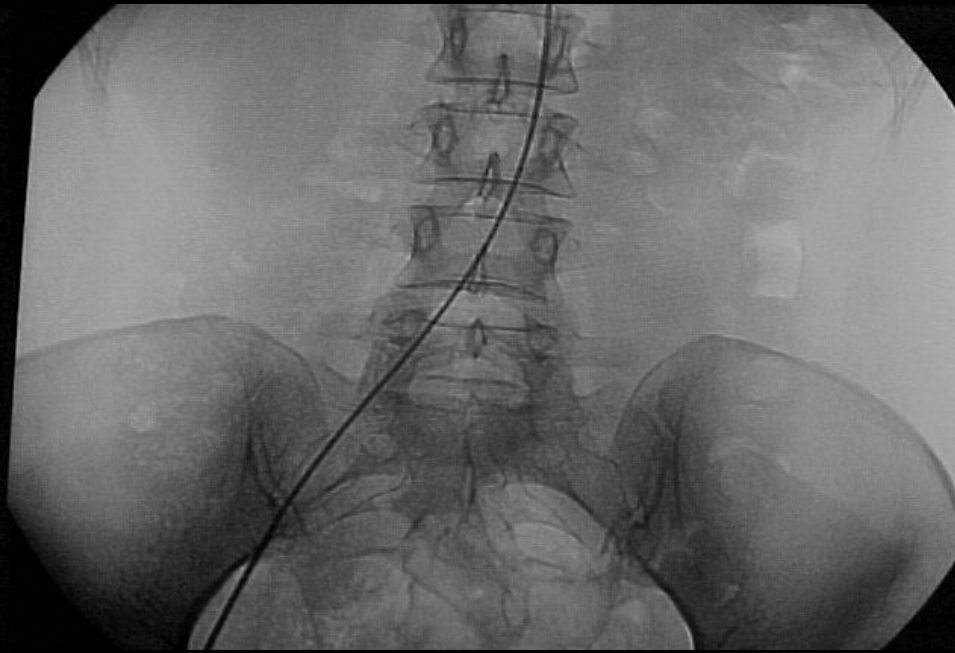


JOGRAPHY
Angiographic Catheters

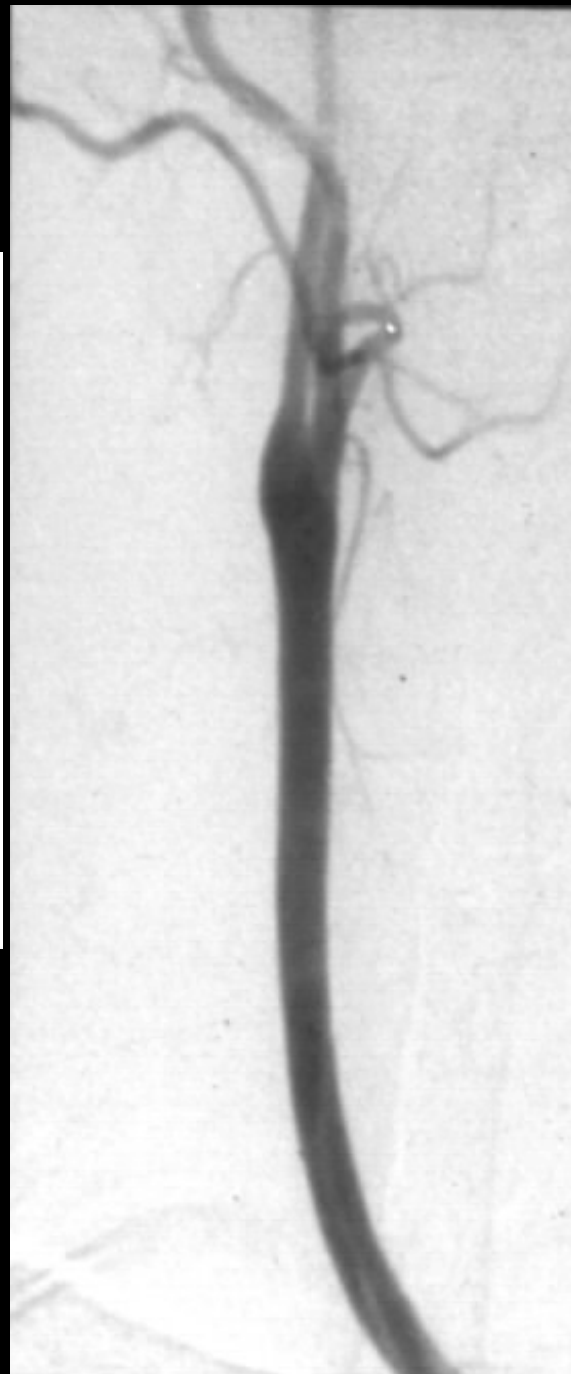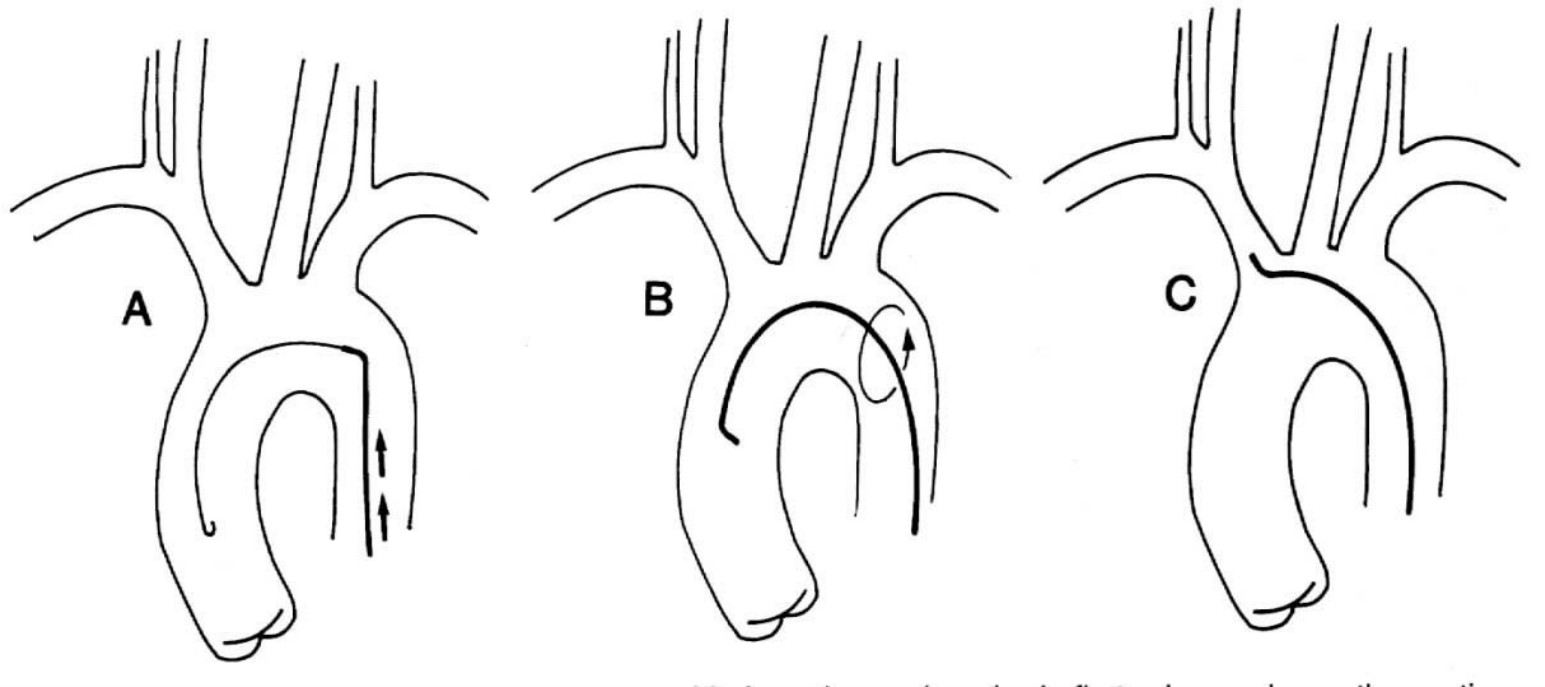


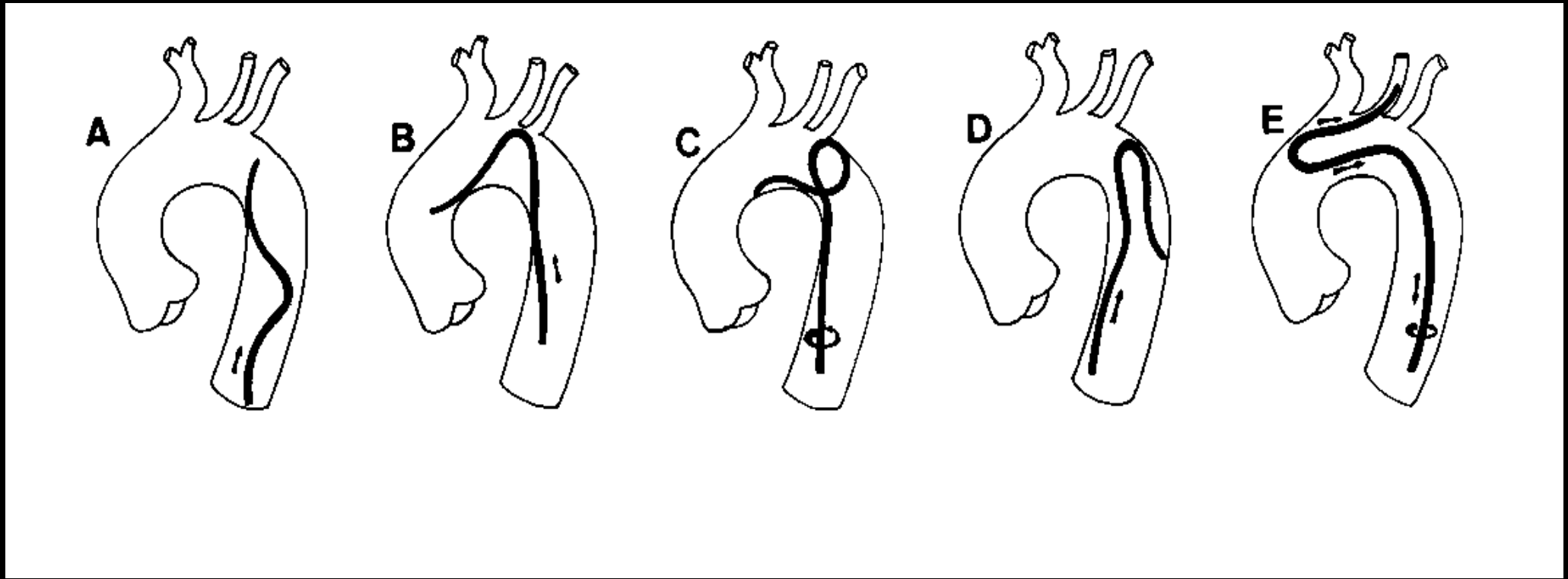
BETTER BY DESIGN

A graphic design for 'JOGRAPHY Angiographic Catheters'. It features a stylized blue catheter tip graphic on the left. The text 'JOGRAPHY' is in a large, light blue font, and 'Angiographic Catheters' is in a smaller, black font below it. At the bottom left, the phrase 'BETTER BY DESIGN' is written in a small, black font.



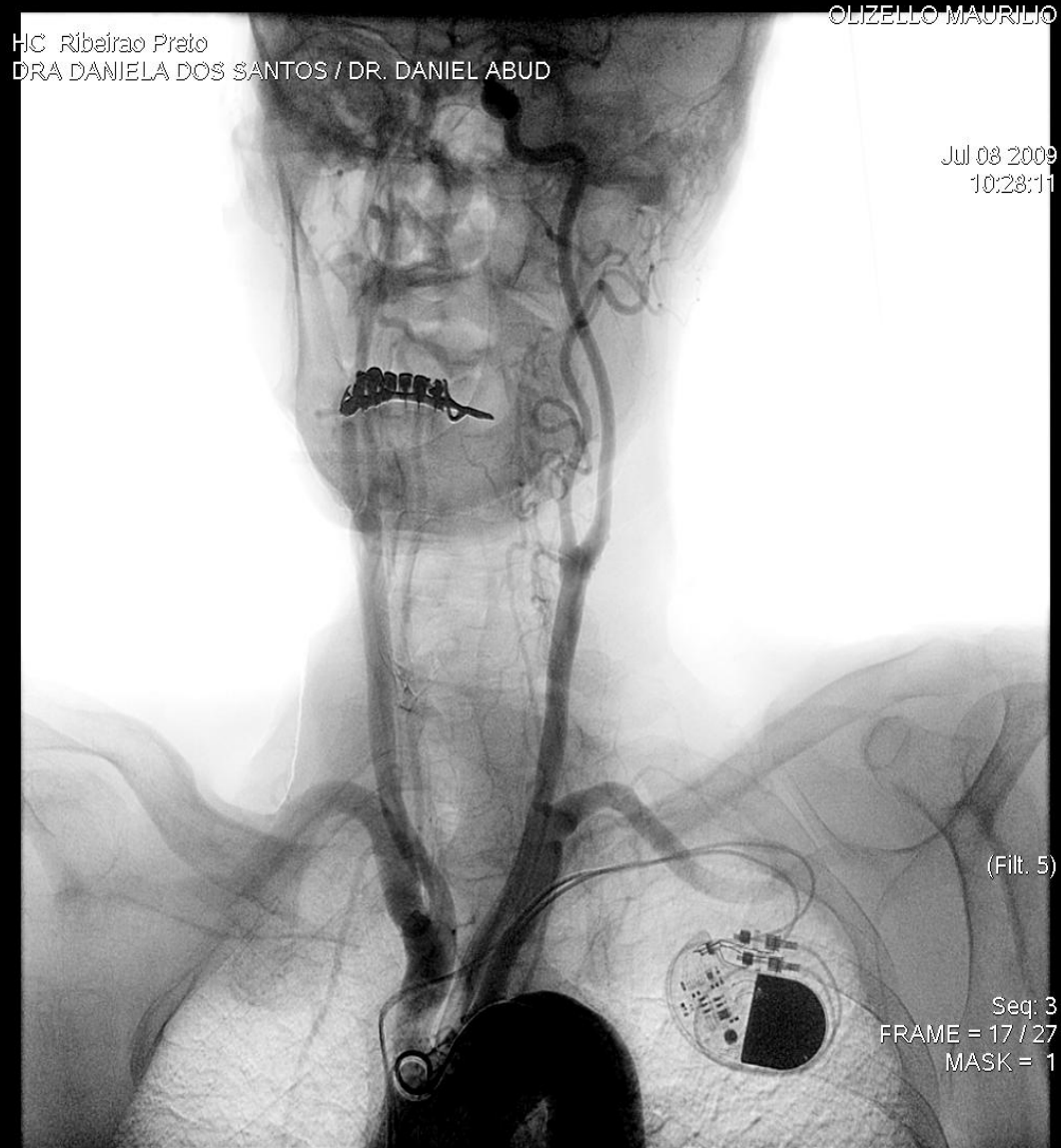
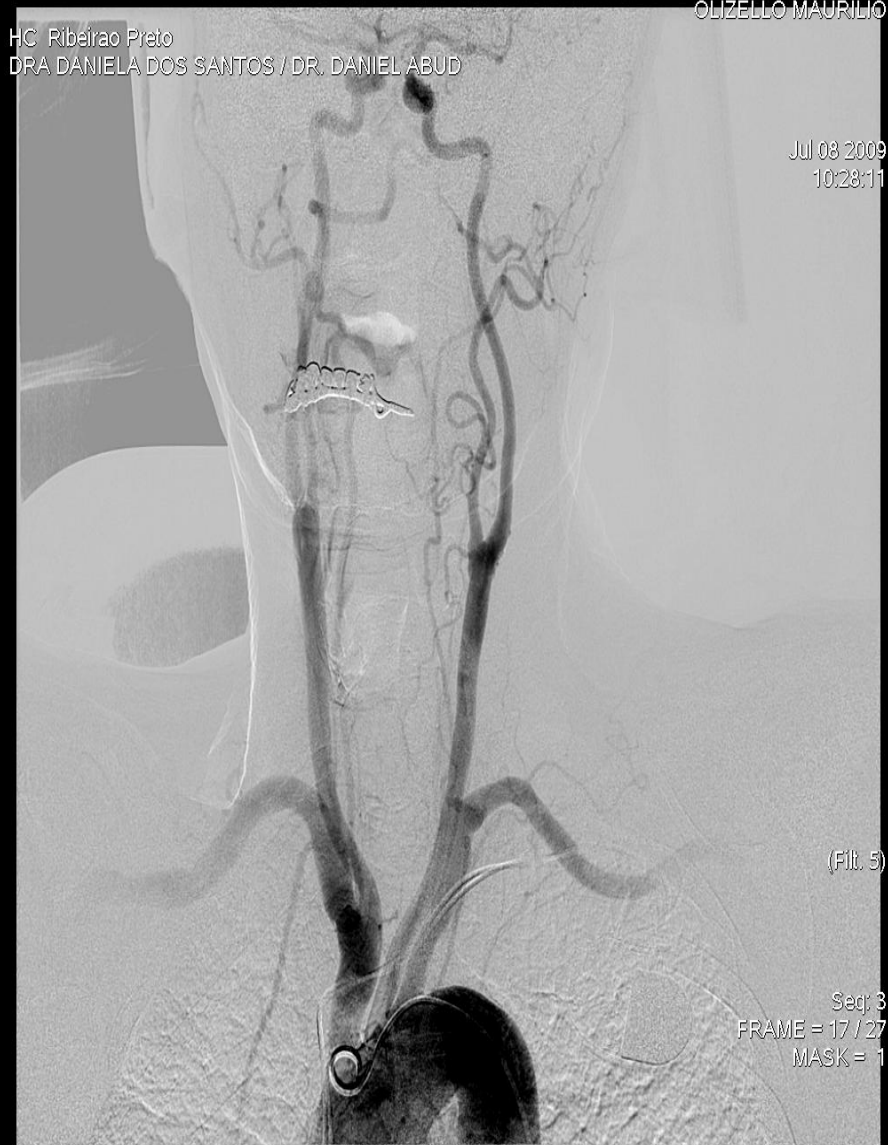Cateterização direta

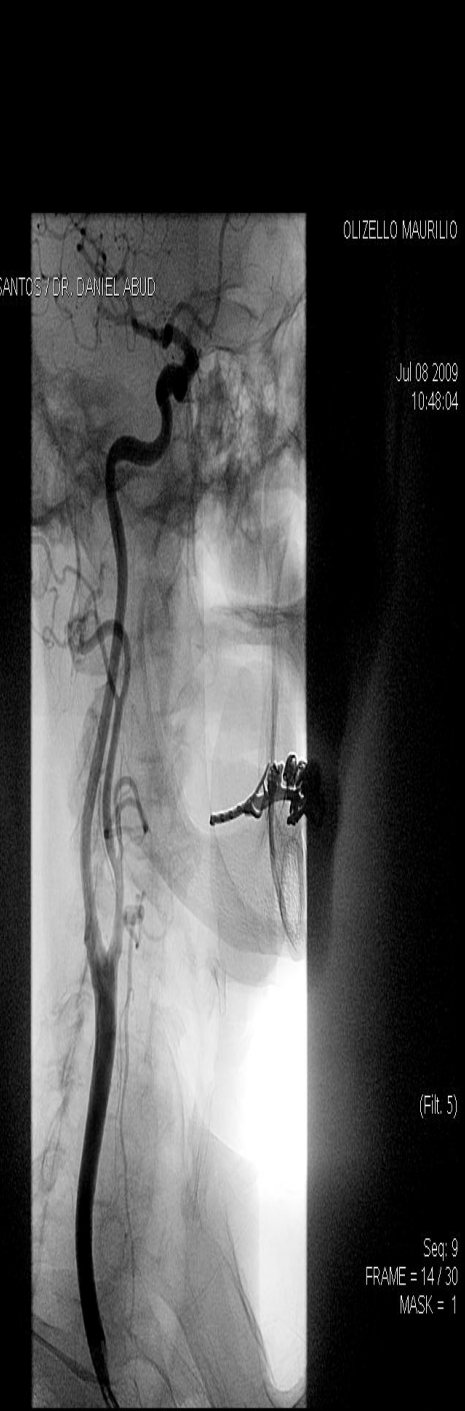
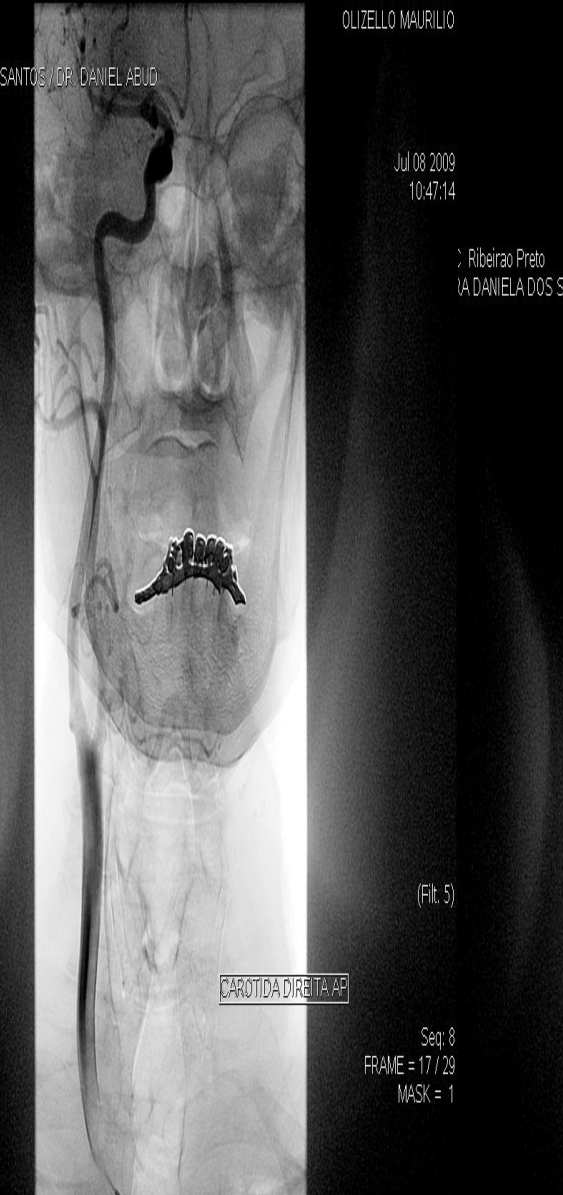
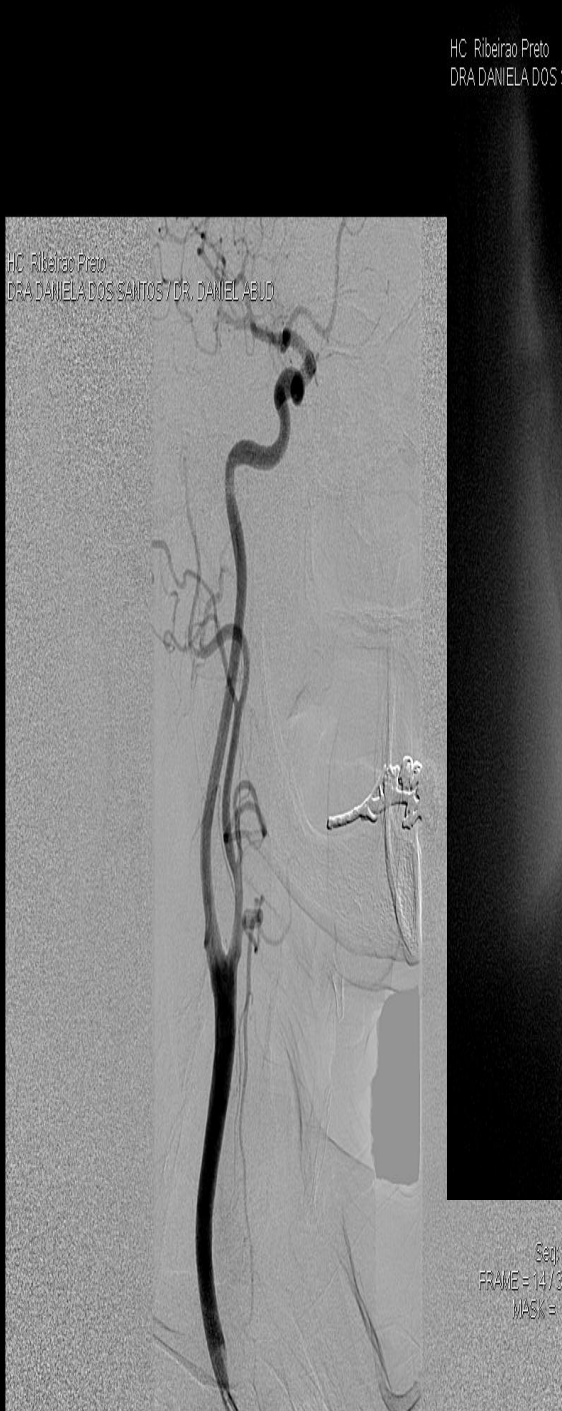
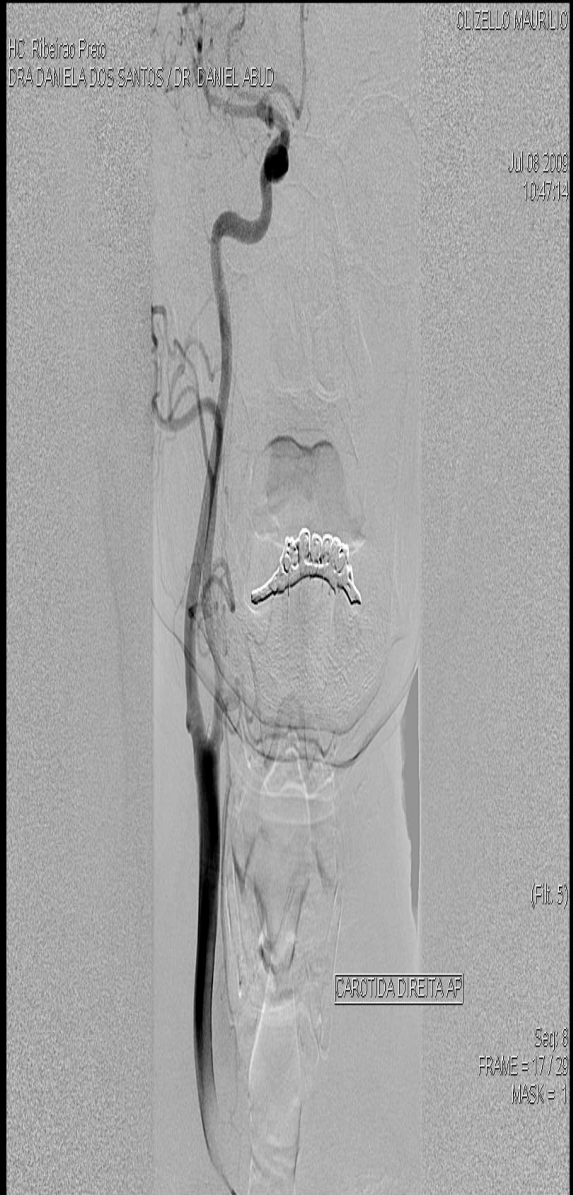
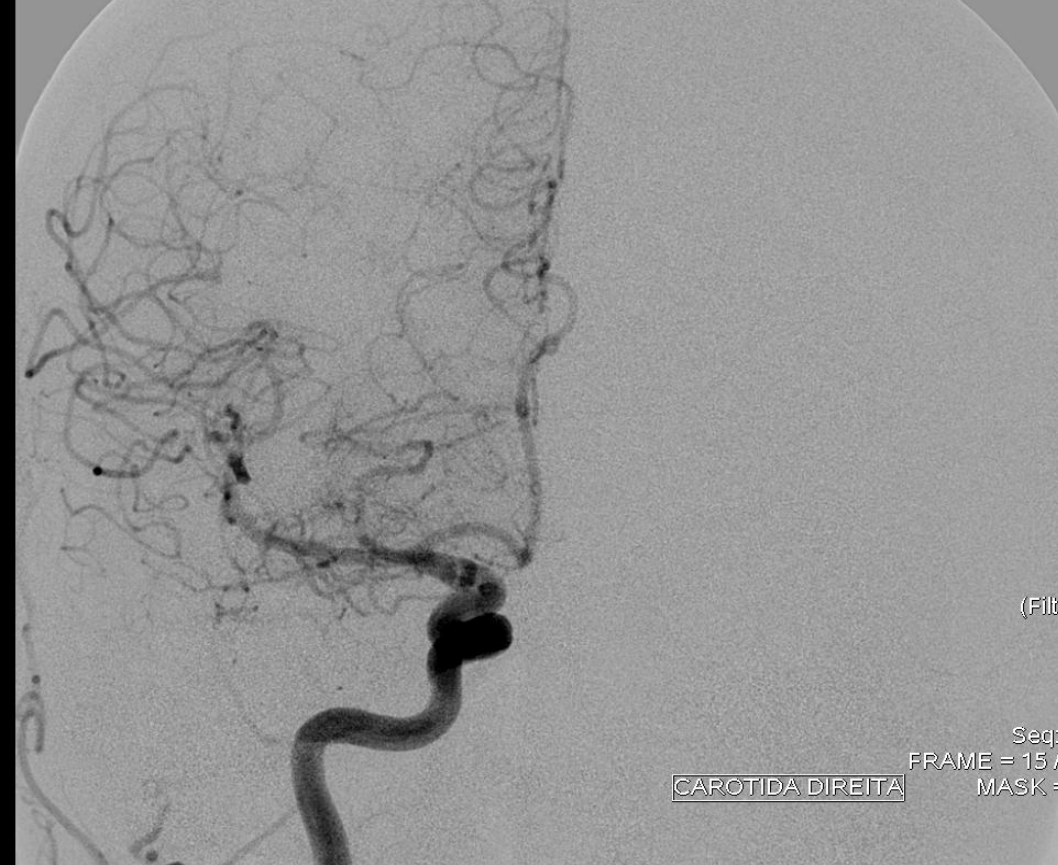
Cateterização indireta: Simmons

Aterosclerose: obstrução arterial crônica





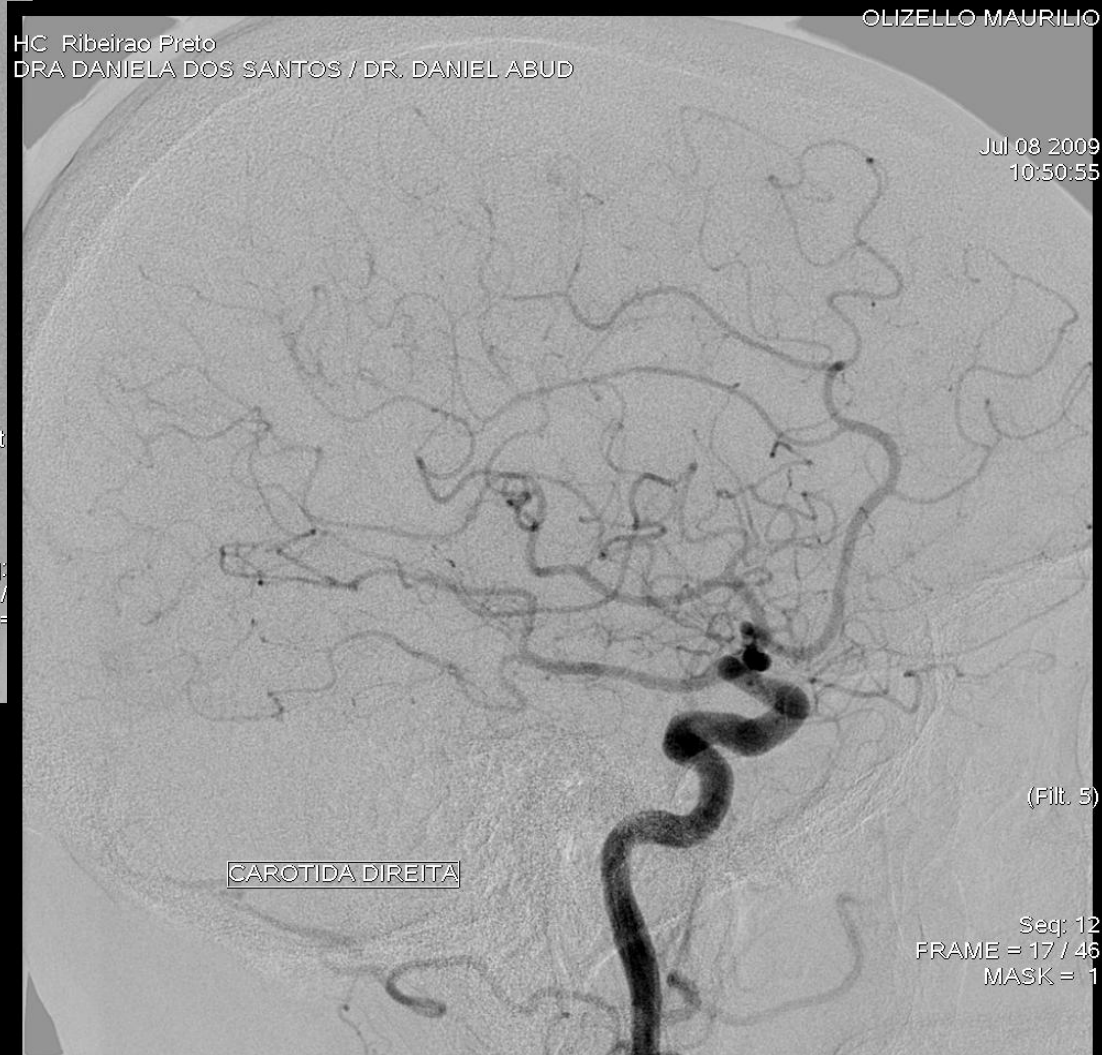Jul 08 2009
10:52:15



(Filt

Seq:
FRAME = 15 /
MASK =

CAROTIDA DIREITA



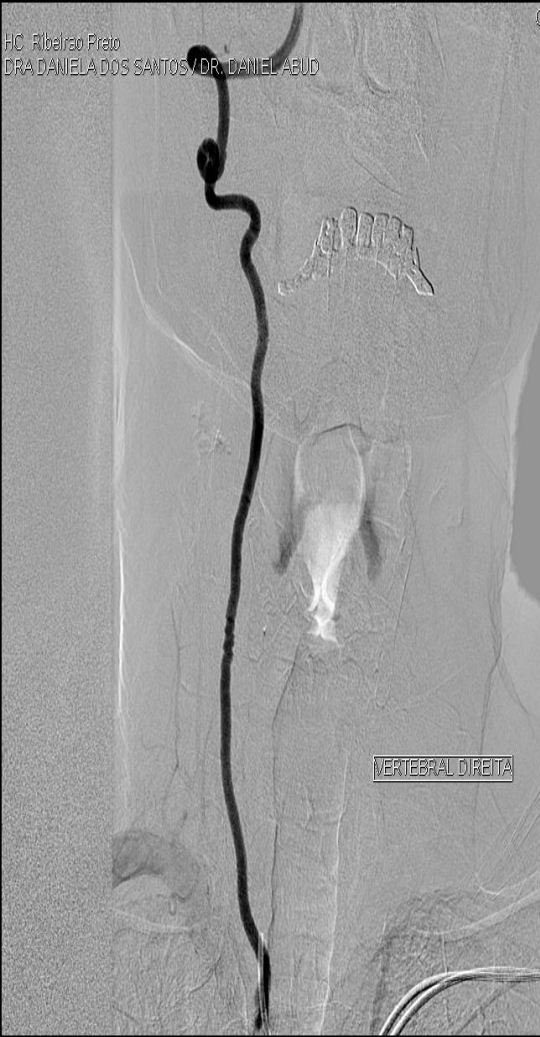Jul 08 2009
10:50:55

(Filt. 5)

Seq: 12
FRAME = 17 / 46
MASK = 1

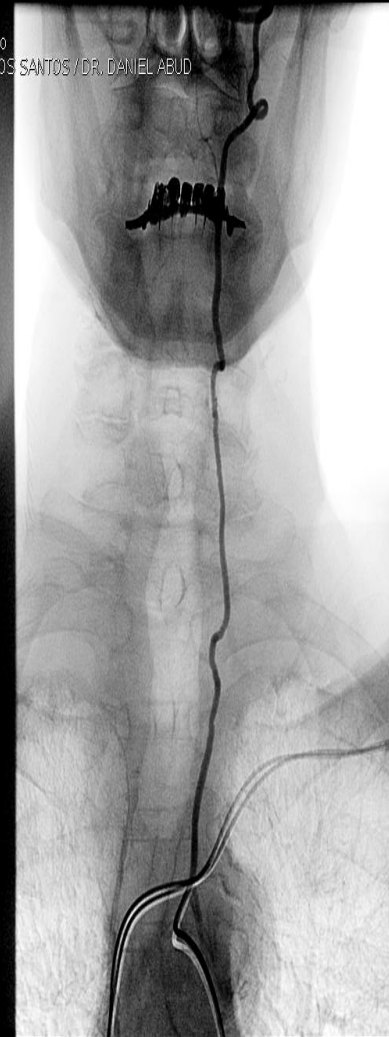
CAROTIDA DIREITA

HC - Ribeirao Preto
DRA DANIELA DOS SANTOS / DR. DANIEL ABUD



VERTEBRAL DIREITA

HC - Ribeirao Preto
DRA DANIELA DOS SANTOS / DR. DANIEL ABUD



OLIZELLO MAURILIO

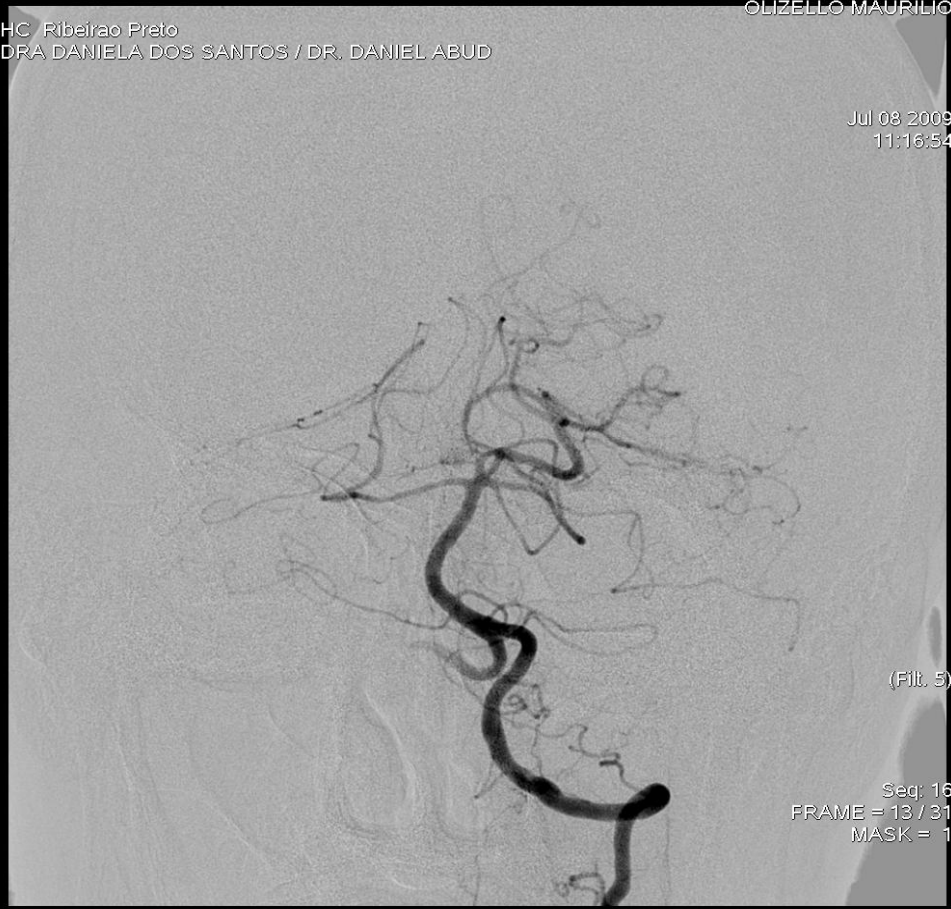
Jul 08 2009
11:16:18

(Fil. 5)

Seq: 15
FRAME = 12 / 16
MASK = 1

OLIZELLO MAURILIO

HC - Ribeirao Preto
DRA DANIELA DOS SANTOS / DR. DANIEL ABUD

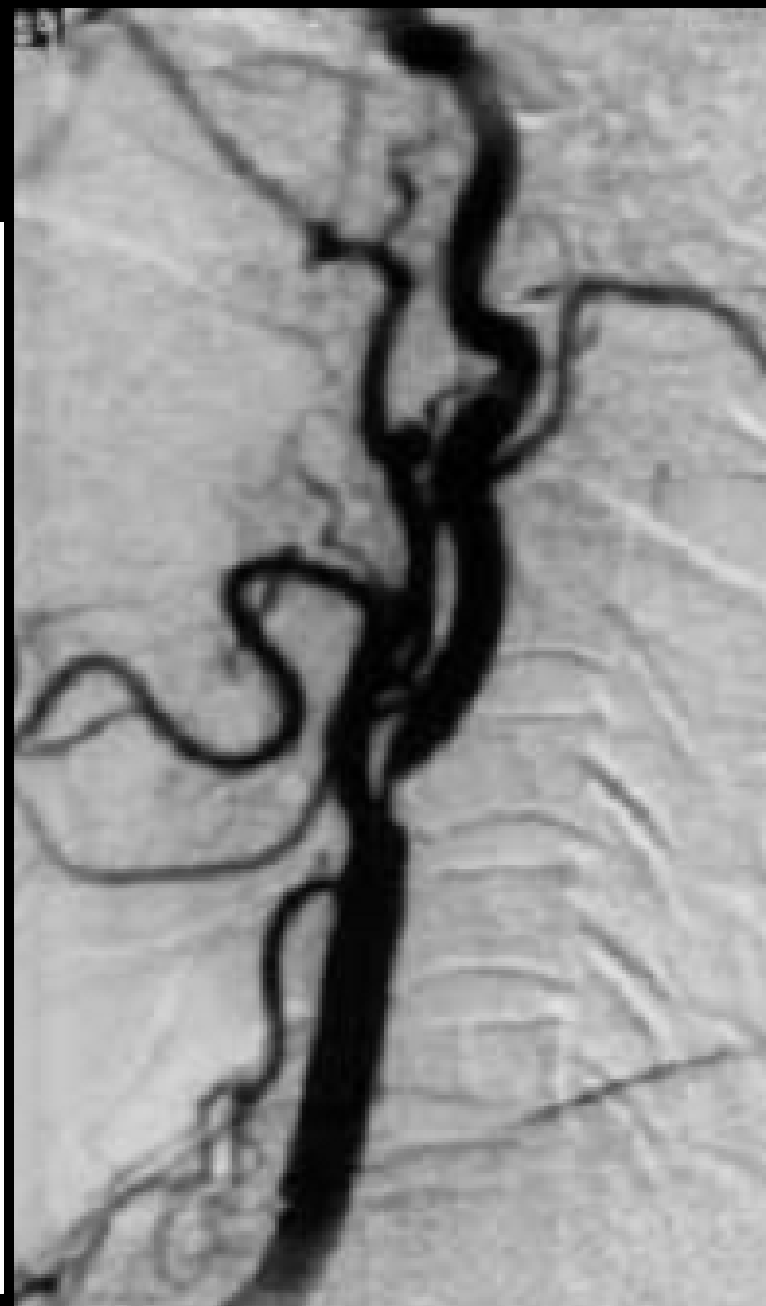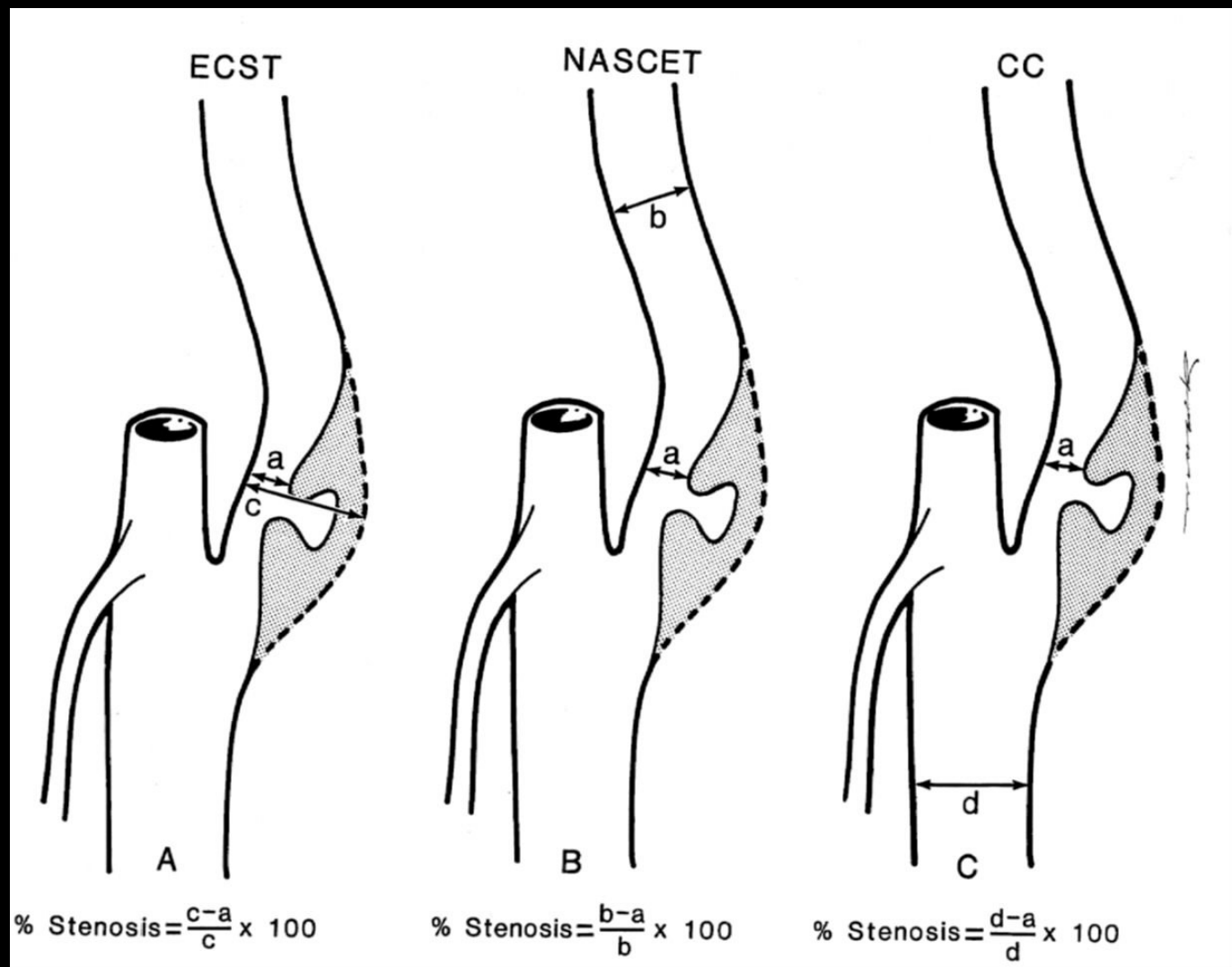


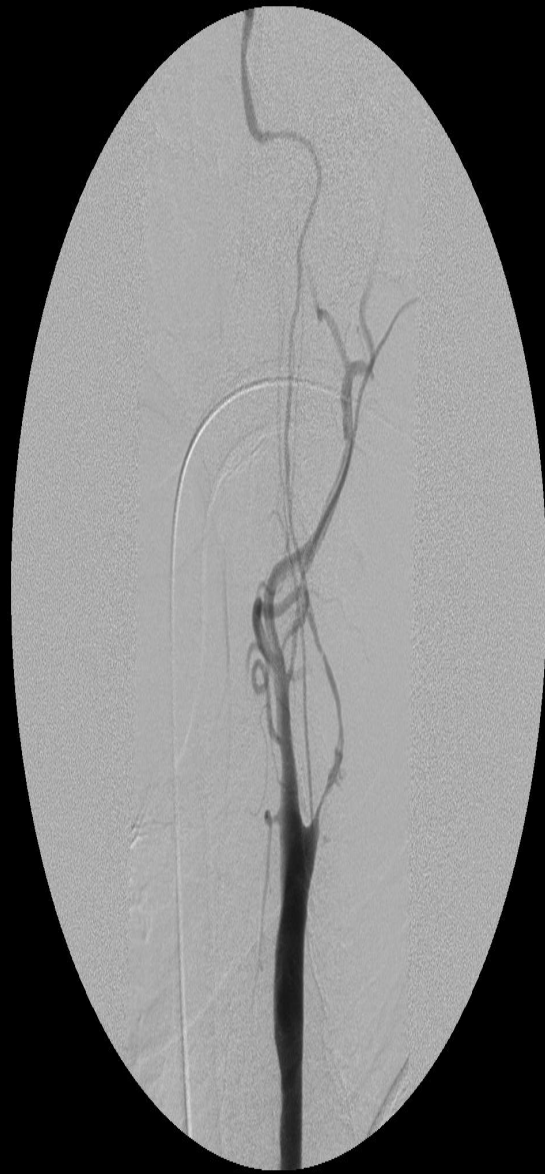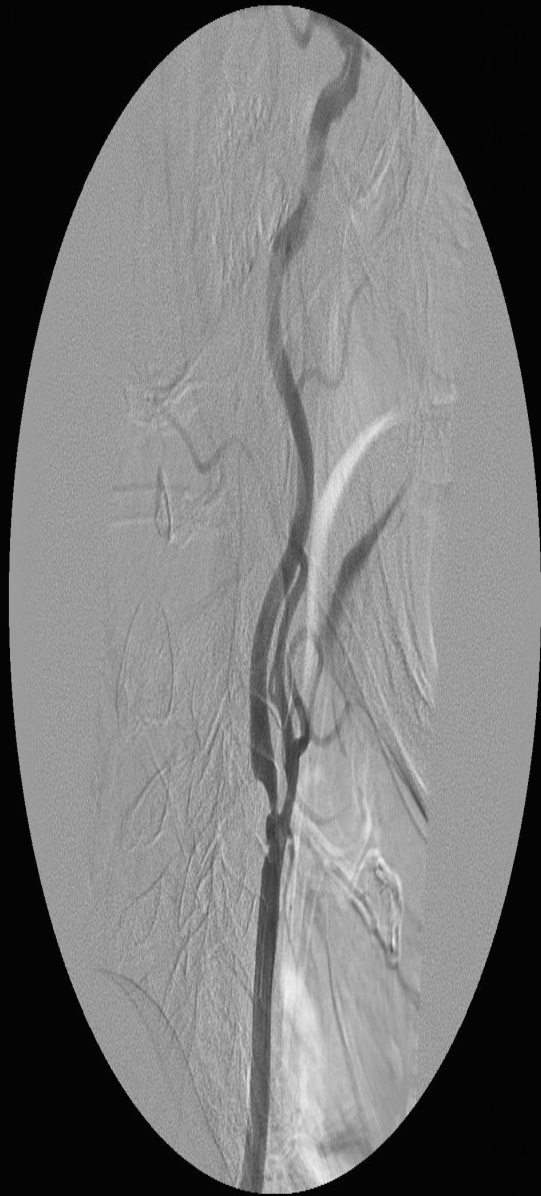Jul 08 2009
11:16:54

(Fil. 5)

Seq: 16
FRAME = 13 / 31
MASK = 1

Quantificação de estenose

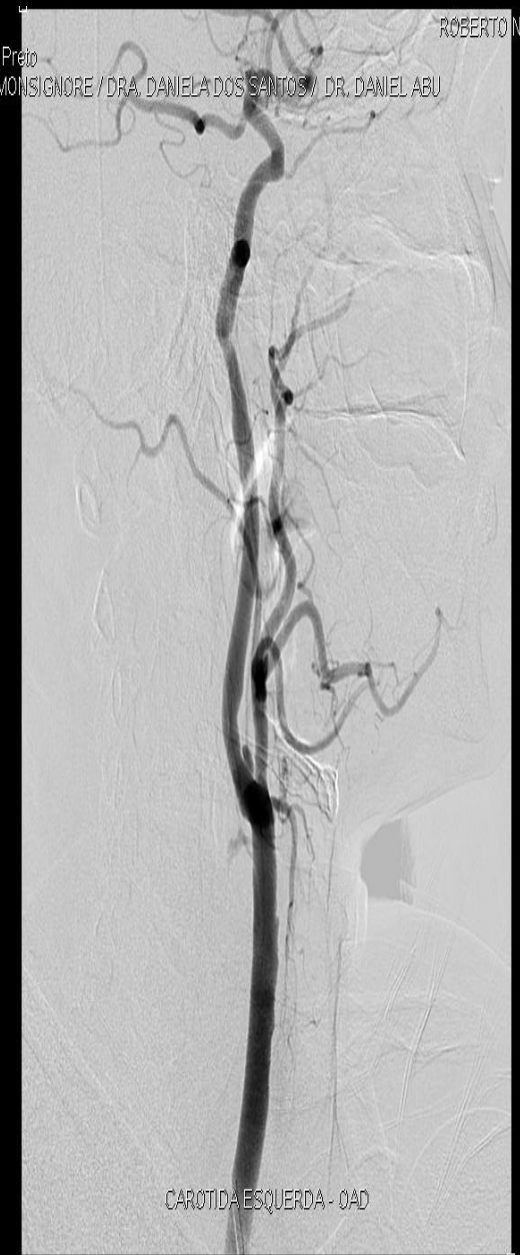



HC Ribeirao Preto
DR. LUCAS MONSIGNORE / DRA. DANIELA DOS SANTOS / DR. DANIEL ABU

ROBERTO NICANOR JOSE

Aug 04 2009
11:44:37



(Filt. 5)
(Shut.)
(Peak Op)

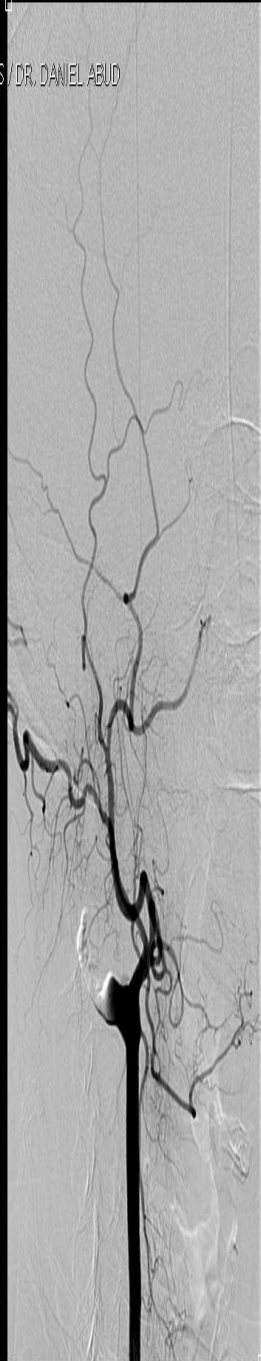
MASK = 1

CAROTIDA ESQUERDA - OAD

HC Ribeirao Preto
DRA DANIELA DOS SANTOS / DR. DANIEL ABUD

DE FARIA MARIA AP.

Aug 14 2009
09:43:14



CAROTIDA DIR. OAD

(Flit. 5)
(Shut.)

Seq: 3
FRAME = 8 / 26
MASK = 1

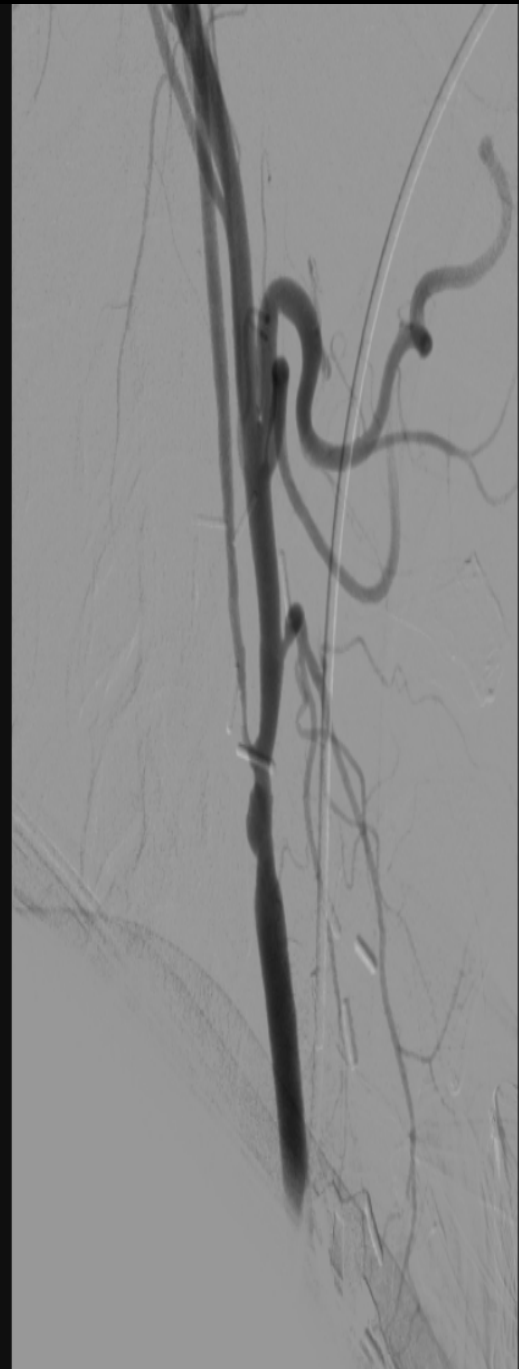

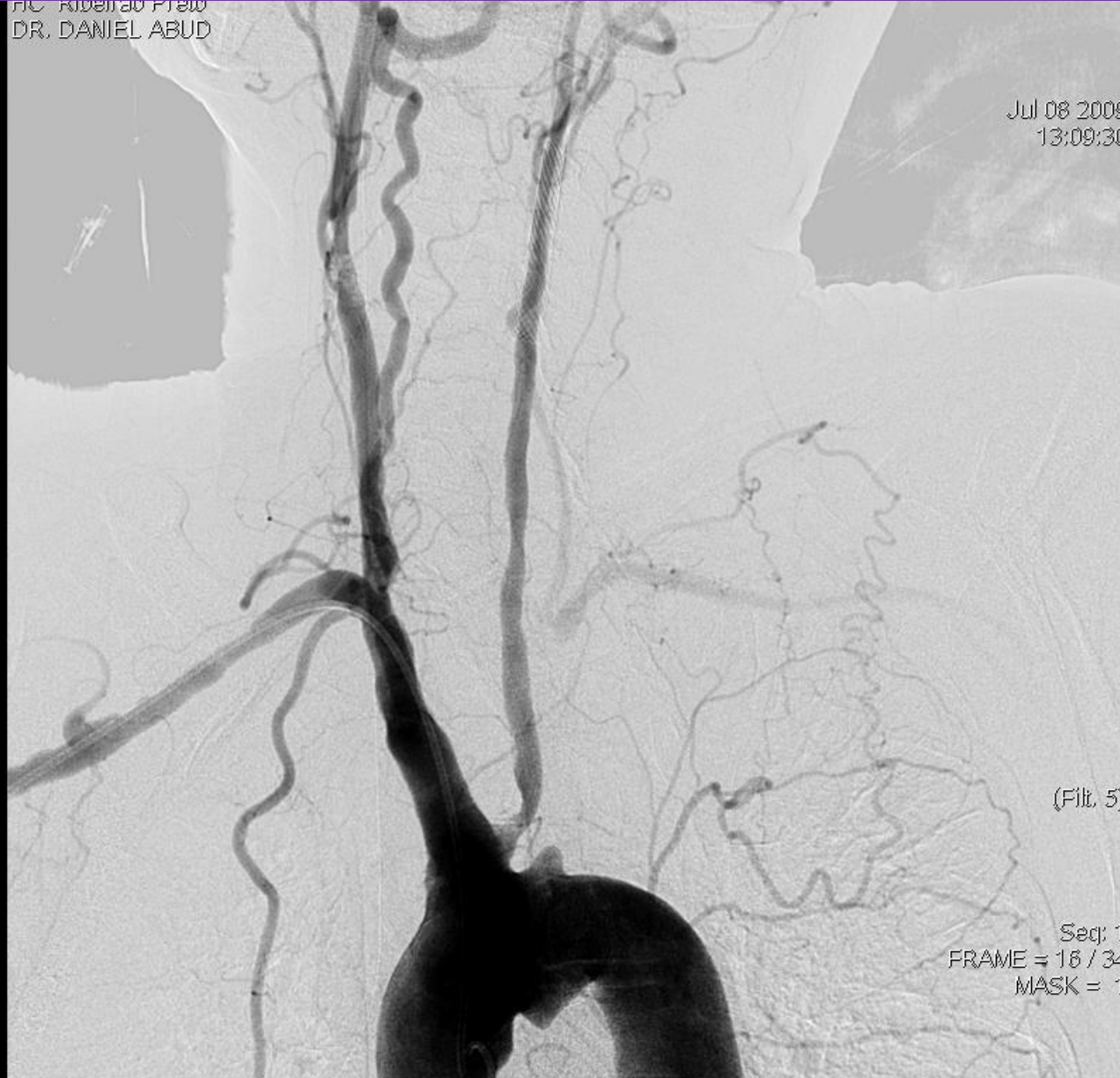Photo 5

4
1-5

Exame dinâmico com radiografias seriadas

RICARDO FERREIRA
DR. DANIEL ABUD

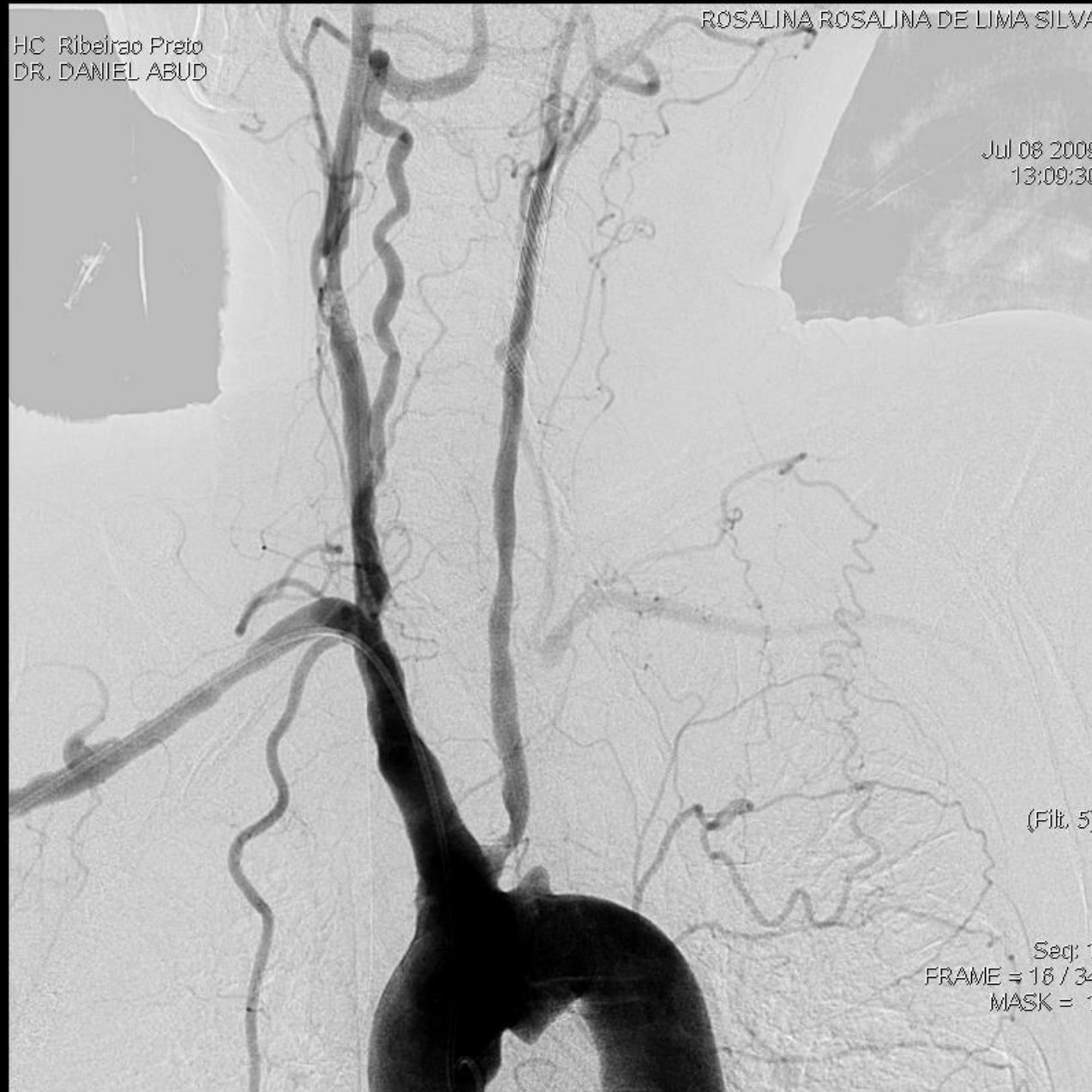
Jul 08 2009
13:09:30



(Filt. 5)

Seq: 1
FRAME = 16 / 34
MASK = 1

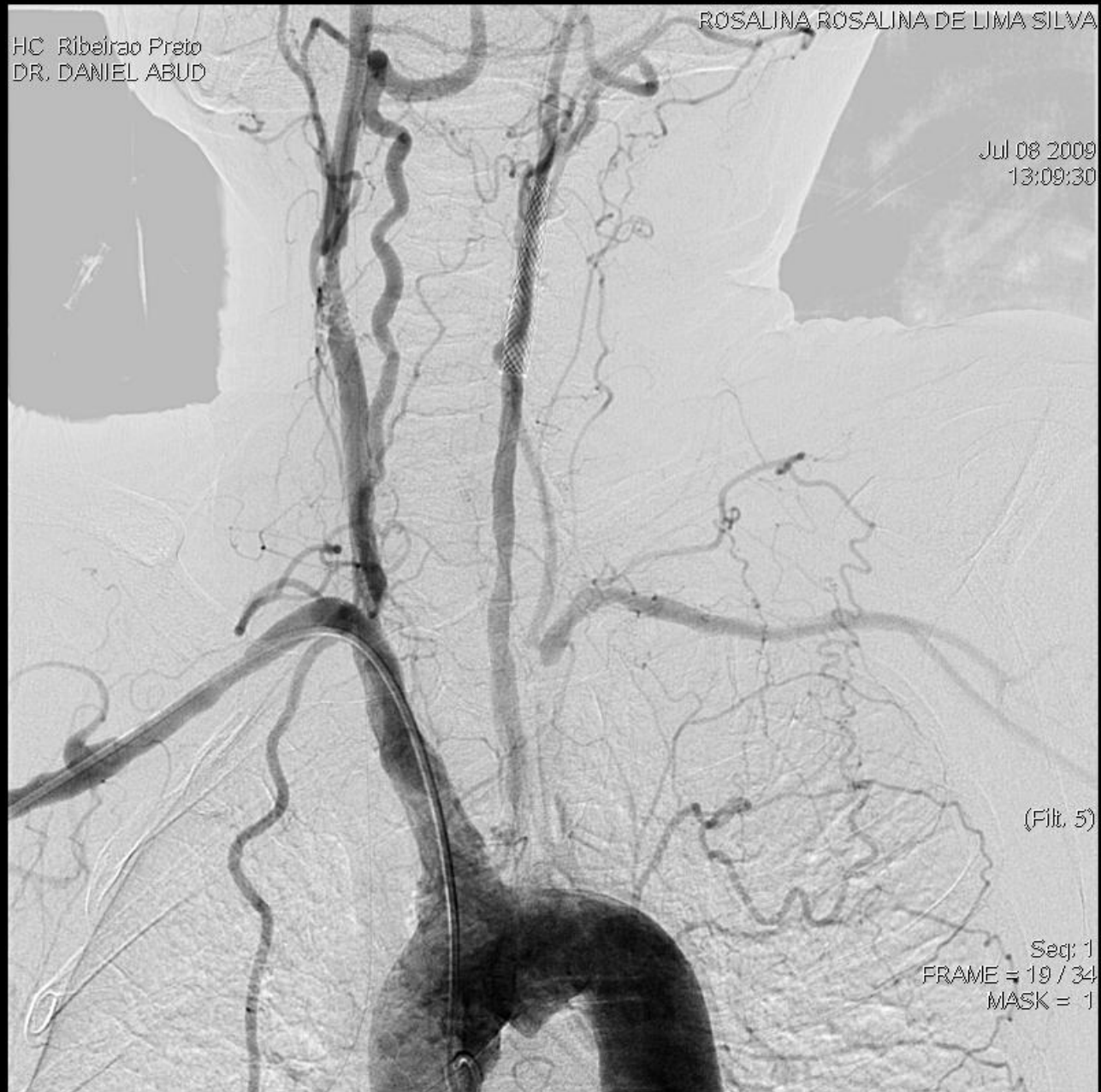
Síndrome do Roubo da Subclávia



HC Ribeirão Preto
DR. DANIEL ABUD

ROSALINA ROSALINA DE LIMA SILVA

Jul 08 2009
13:09:30



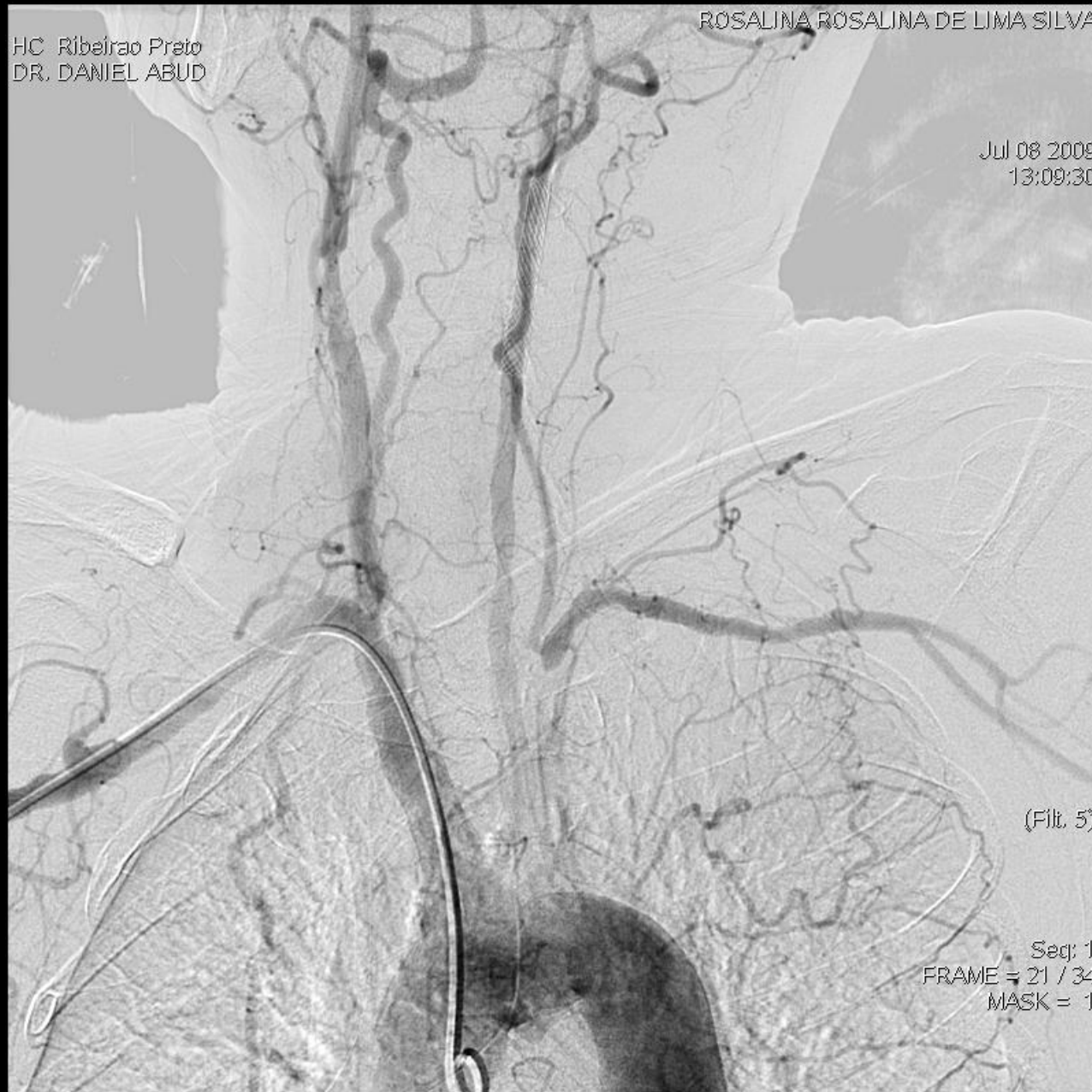(Filt. 5)

Seq: 1
FRAME = 19 / 34
MASK = 1

HC Ribeirão Preto
DR. DANIEL ABUD

ROSALINA ROSALINA DE LIMA SILVA

Jul 08 2009
13:09:30



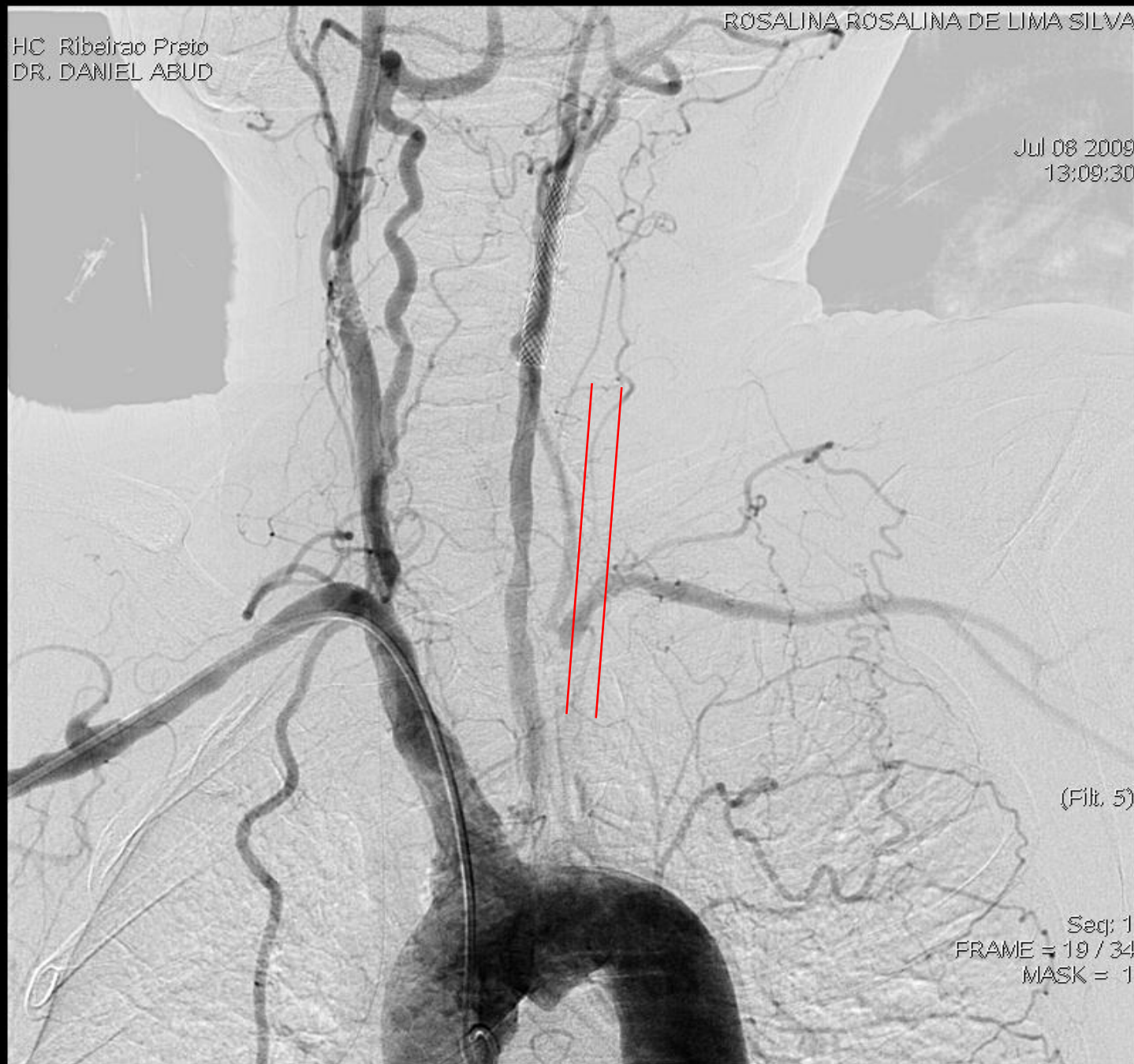(Filt. 5)

Seq: 1
FRAME = 21 / 34
MASK = 1

HC. Riberão Preto
DR. DANIEL ABUD

ROSALINA ROSALINA DE LIMA SILVA

Jul 08 2009
13:09:30



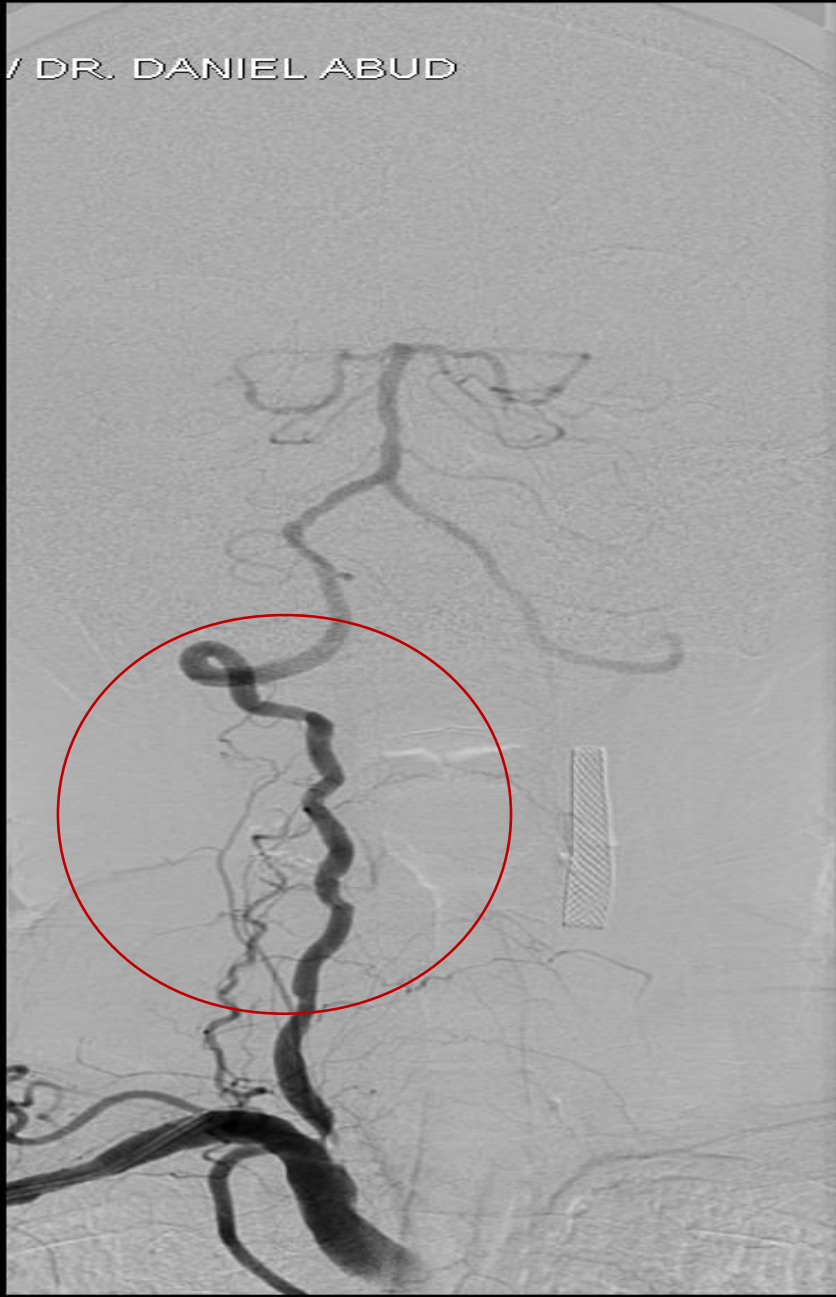(Filt. 5)

Seq: 1
FRAME = 19 / 34
MASK = 1

HC Ribeirao Preto
DRA DANIELA DOS SANTOS / DR. DANIEL ABUD

SILVA ROSALINA DE LIMA

Jul 01 2009
13:22:20



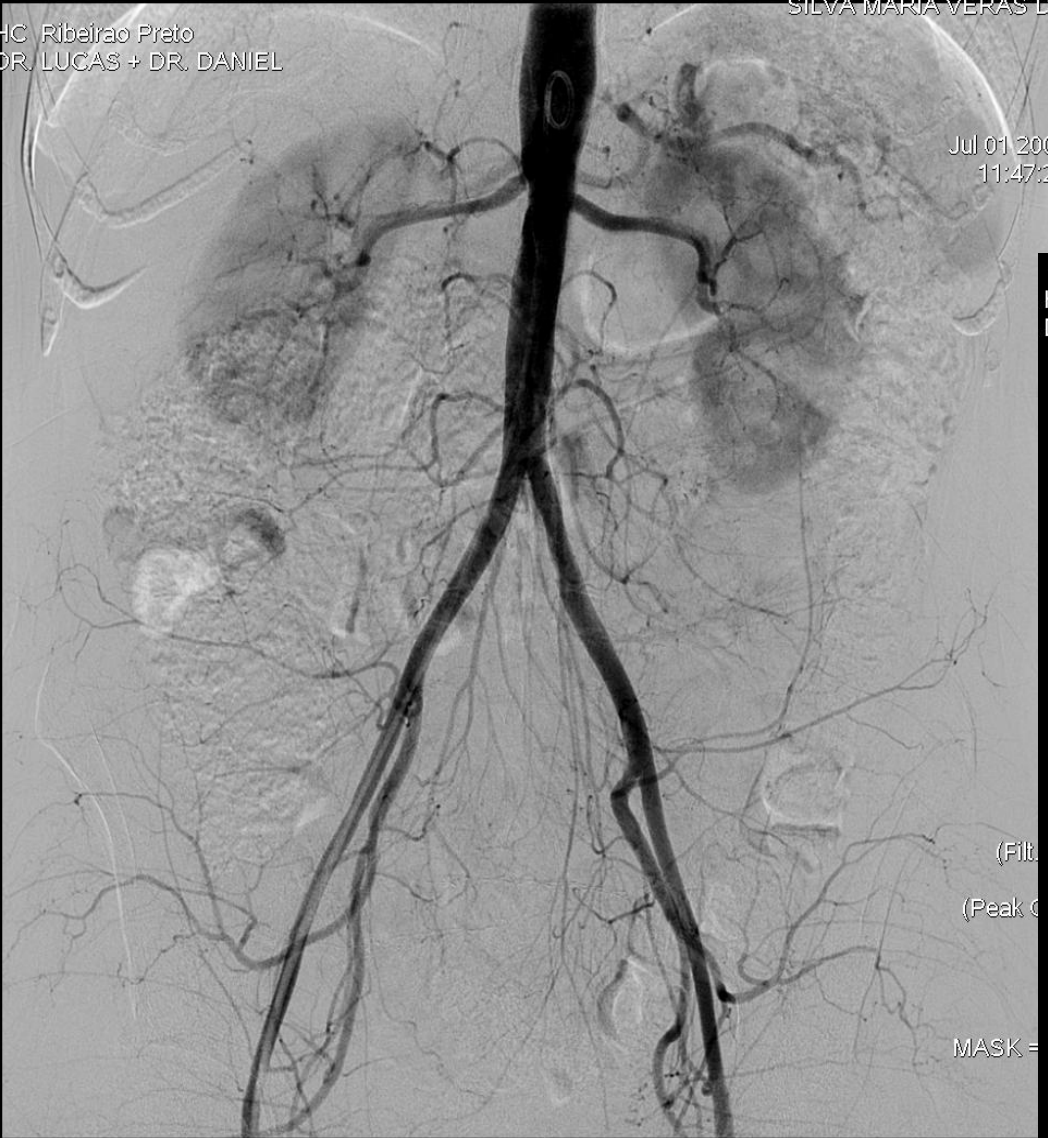
(Filt. 5
(Shut.

Seq: 7
FRAME = 12 / 3
MASK = 1

SILVA MARIA VERAS DA

HC Ribeirão Preto
DR. LUCAS + DR. DANIEL

Jul 01 2009
11:47:20

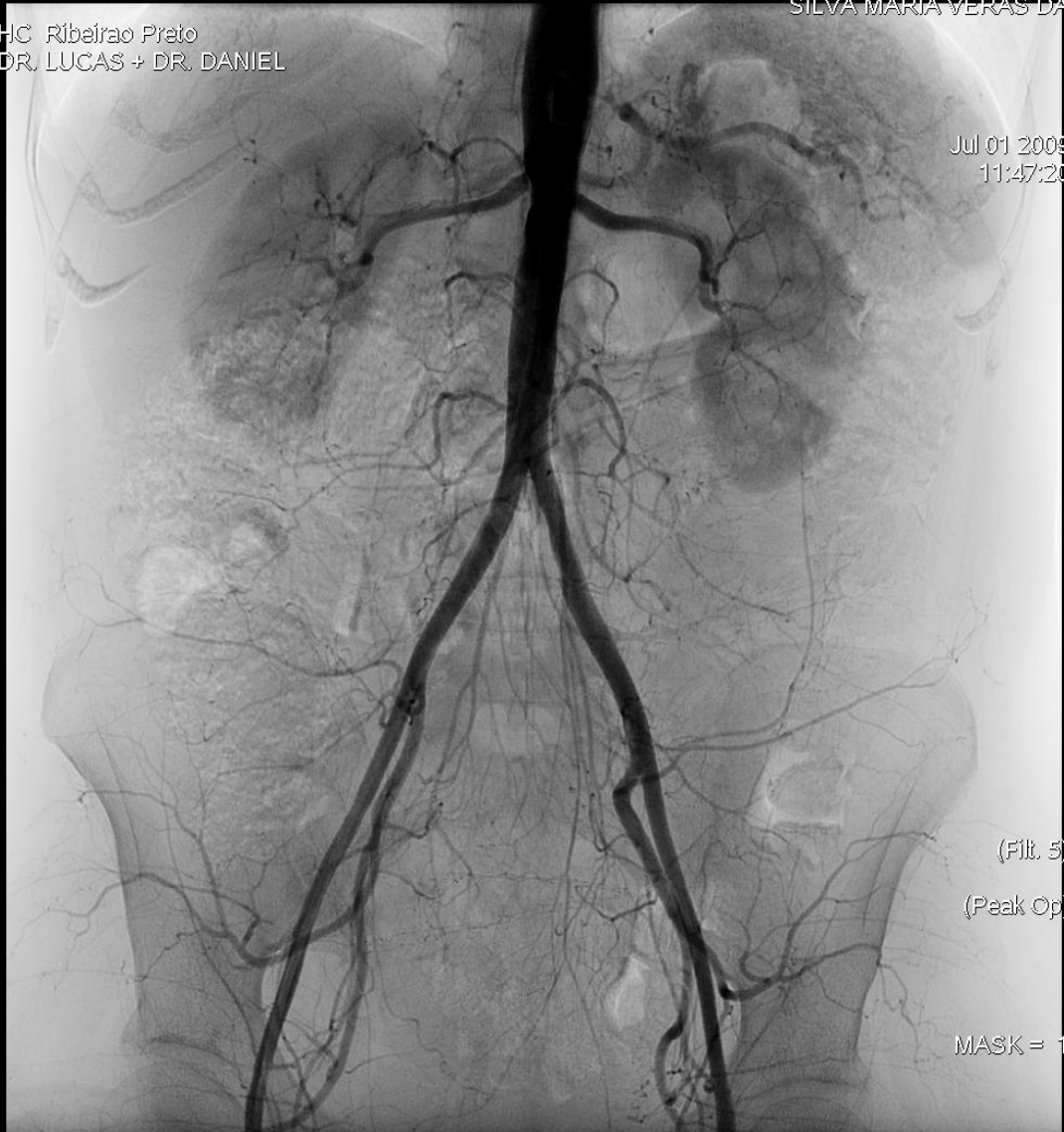


(Filt.
(Peak C
MASK =

SILVA MARIA VERAS DA

HC Ribeirão Preto
DR. LUCAS + DR. DANIEL

Jul 01 2009
11:47:20

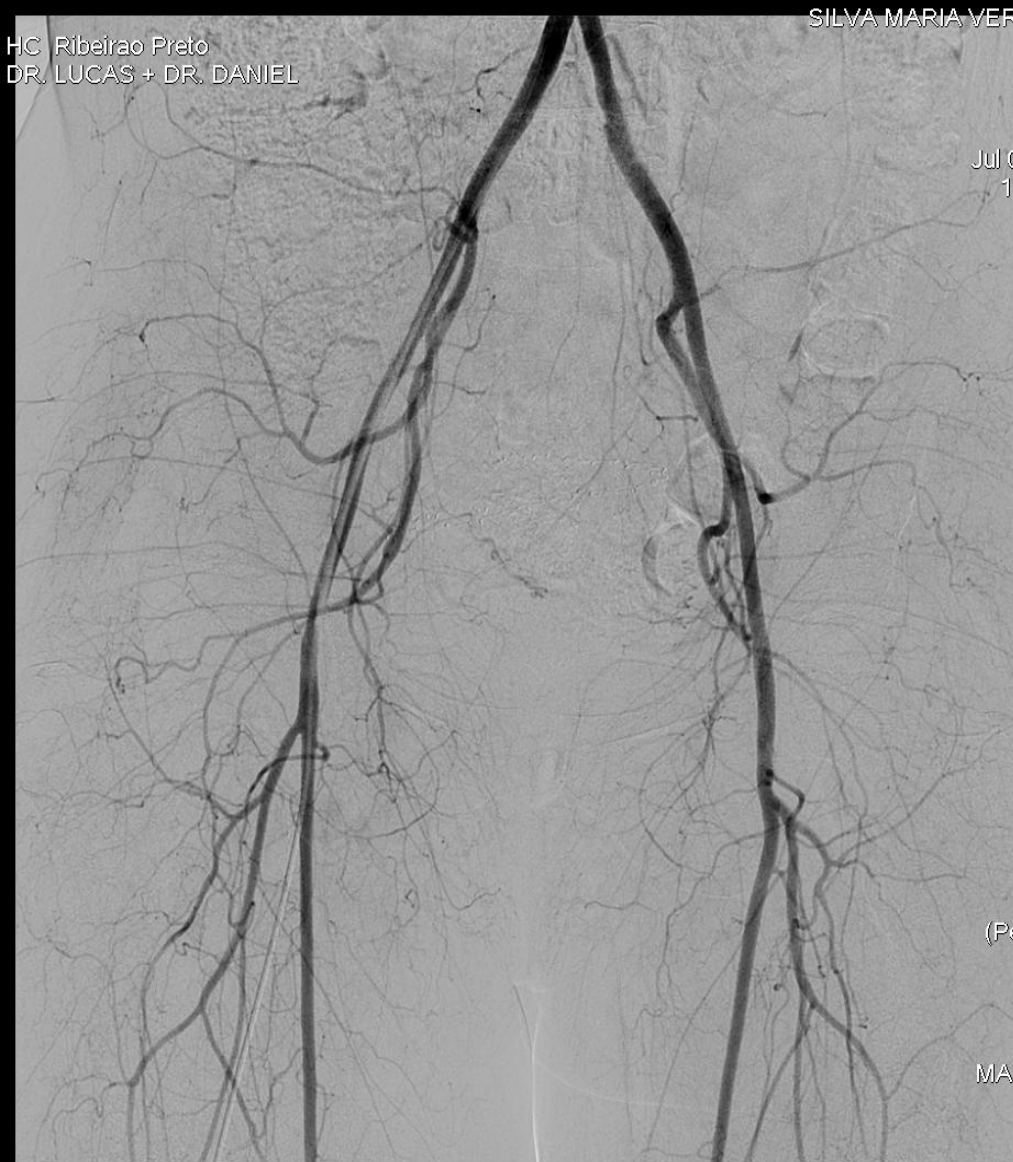

(Filt. 5)
(Peak Op)
MASK = 1

HC - Ribeirao Preto
DR. LUCAS + DR. DANIEL

SILVA MARIA VERAS DA

Jul 01 2009
11:48:57



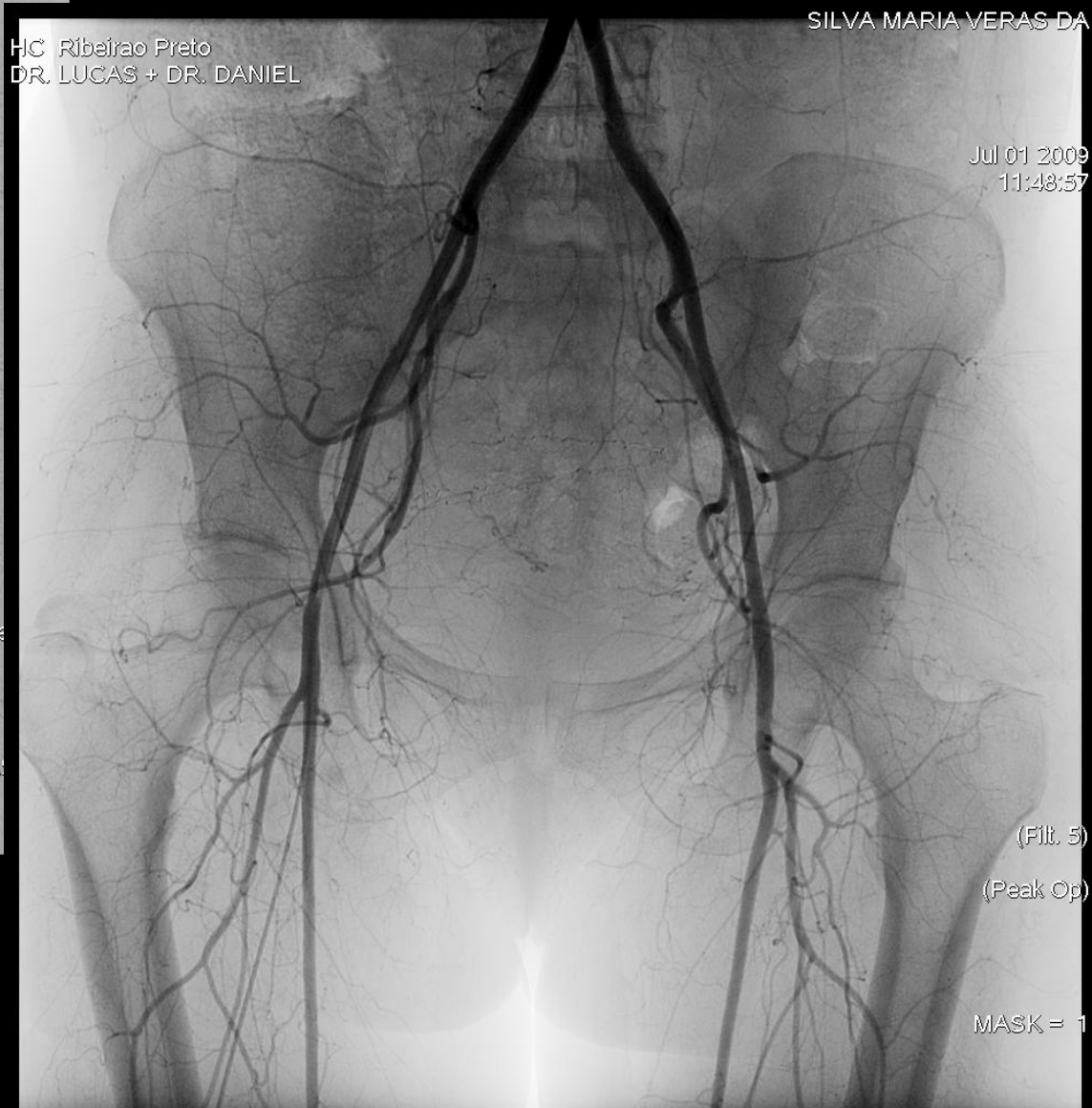(Pe

MA

SILVA MARIA VERAS DA

HC - Ribeirao Preto
DR. LUCAS + DR. DANIEL

Jul 01 2009
11:48:57



(Filt. 5)

(Peak Op)

MASK = 1

HC Ribeirao Preto
DR. LUCAS + DR. DANIEL

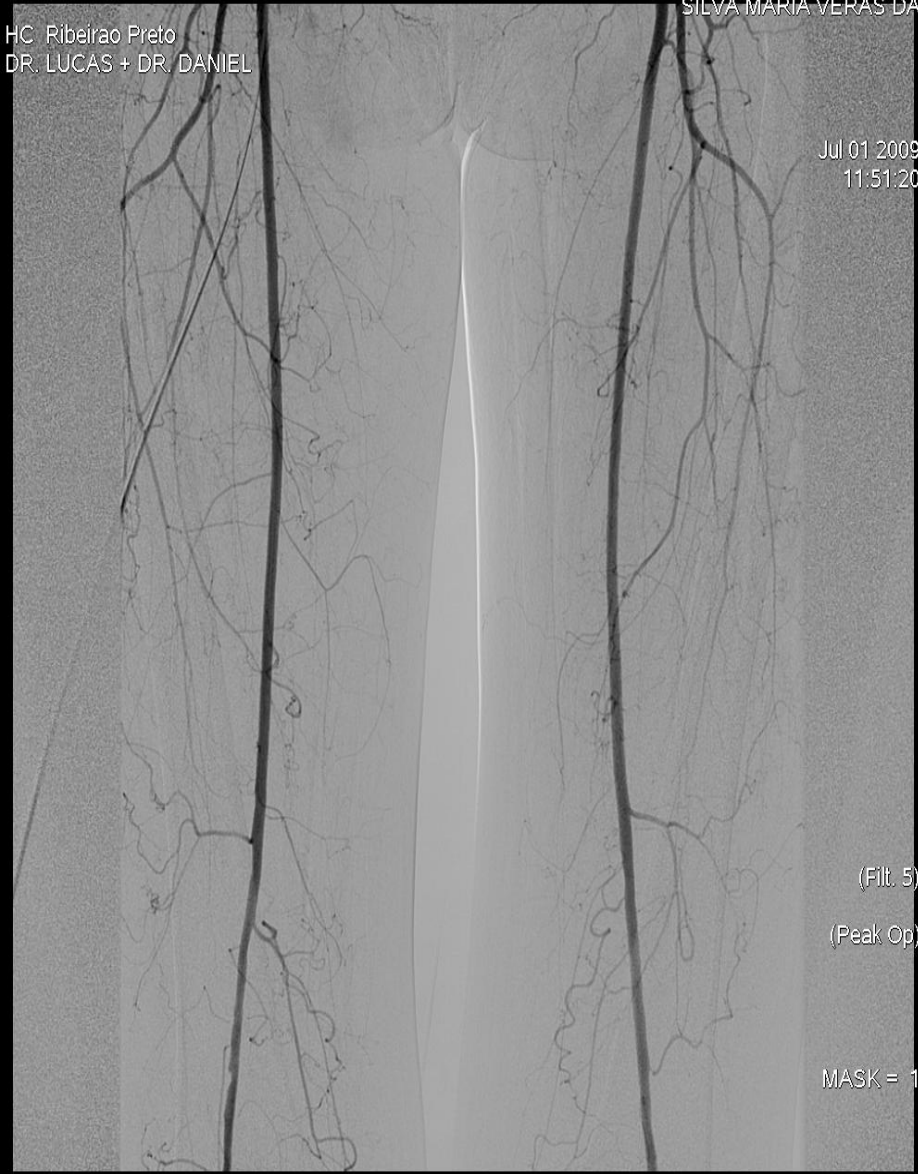
SILVA MARIA VERAS DA

Jul 01 2009
11:51:20

(Filt. 5)

(Peak Op)

MASK = 1



HC Ribeirao Preto
DR. LUCAS + DR. DANIEL

SILVA MARIA VERAS DA

Jul 01 2009
11:51:20

(Filt. 5)

(Peak Op)

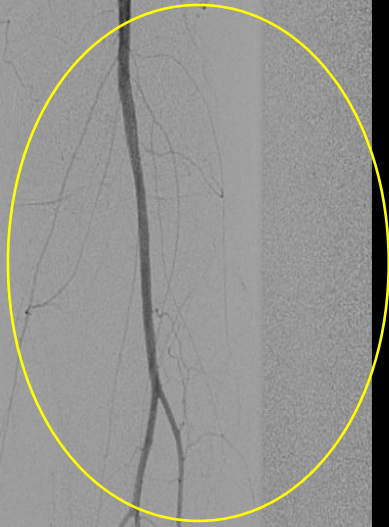
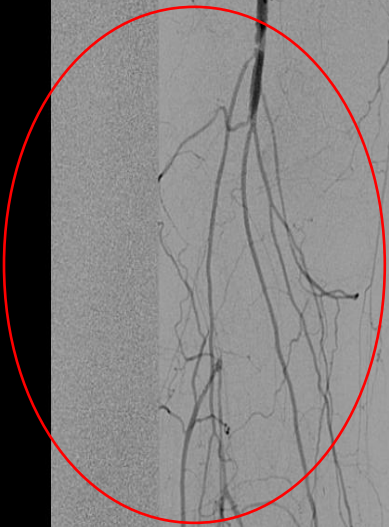MASK = 1



SILVA MARIA VERAS DA

HC Ribeirao Preto
DR. LUCAS + DR. DANIEL

Jul 01 2009
11:53:05

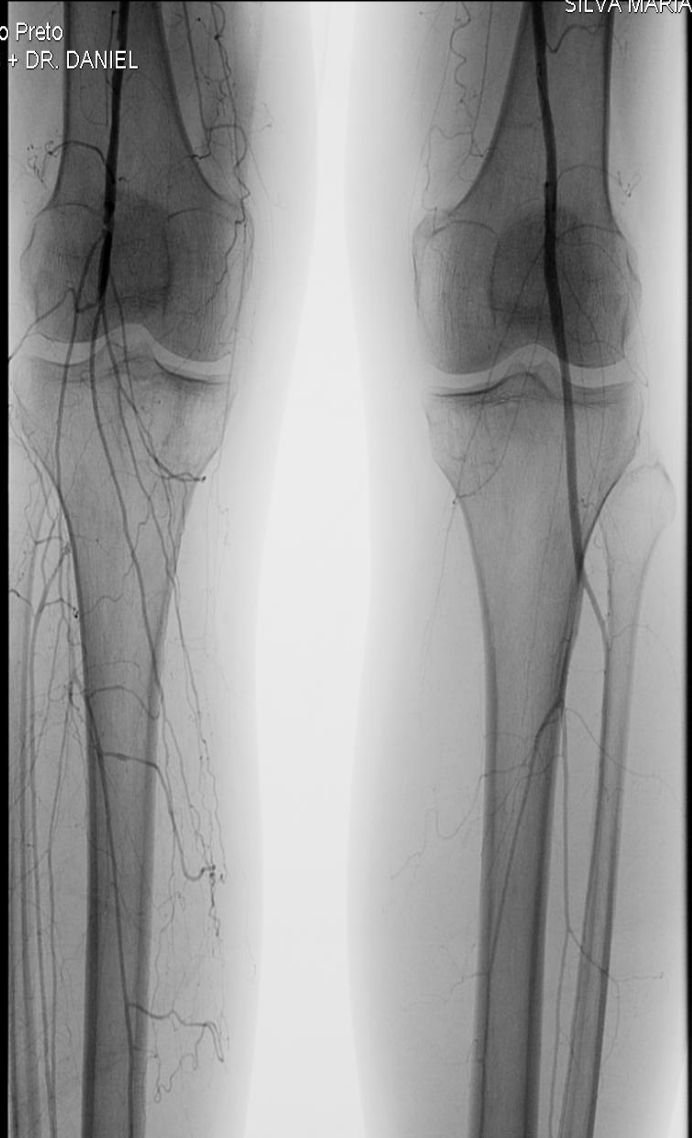

(Filt. 5)
(Peak Op)
MASK = 1

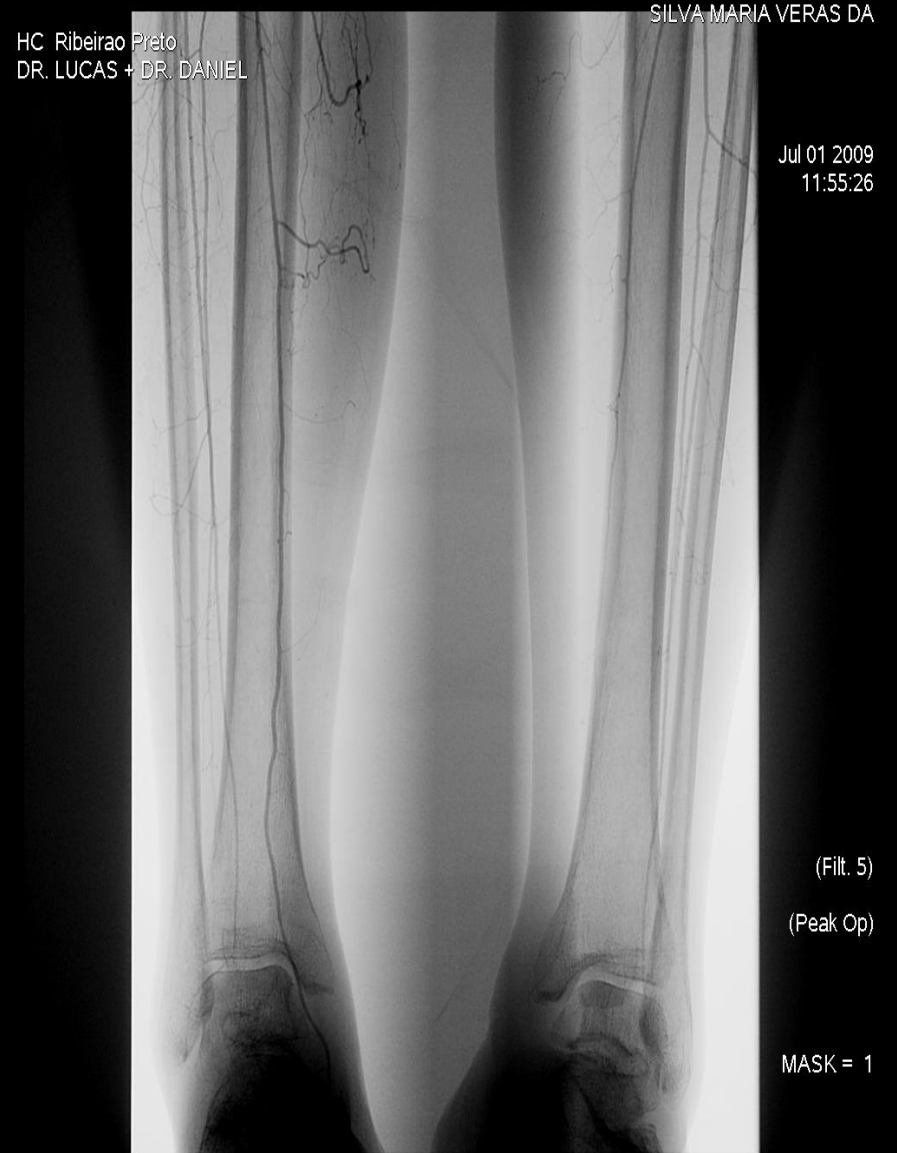
SILVA MARIA VERAS DA

HC Ribeirao Preto
DR. LUCAS + DR. DANIEL

Jul 01 2009
11:53:05



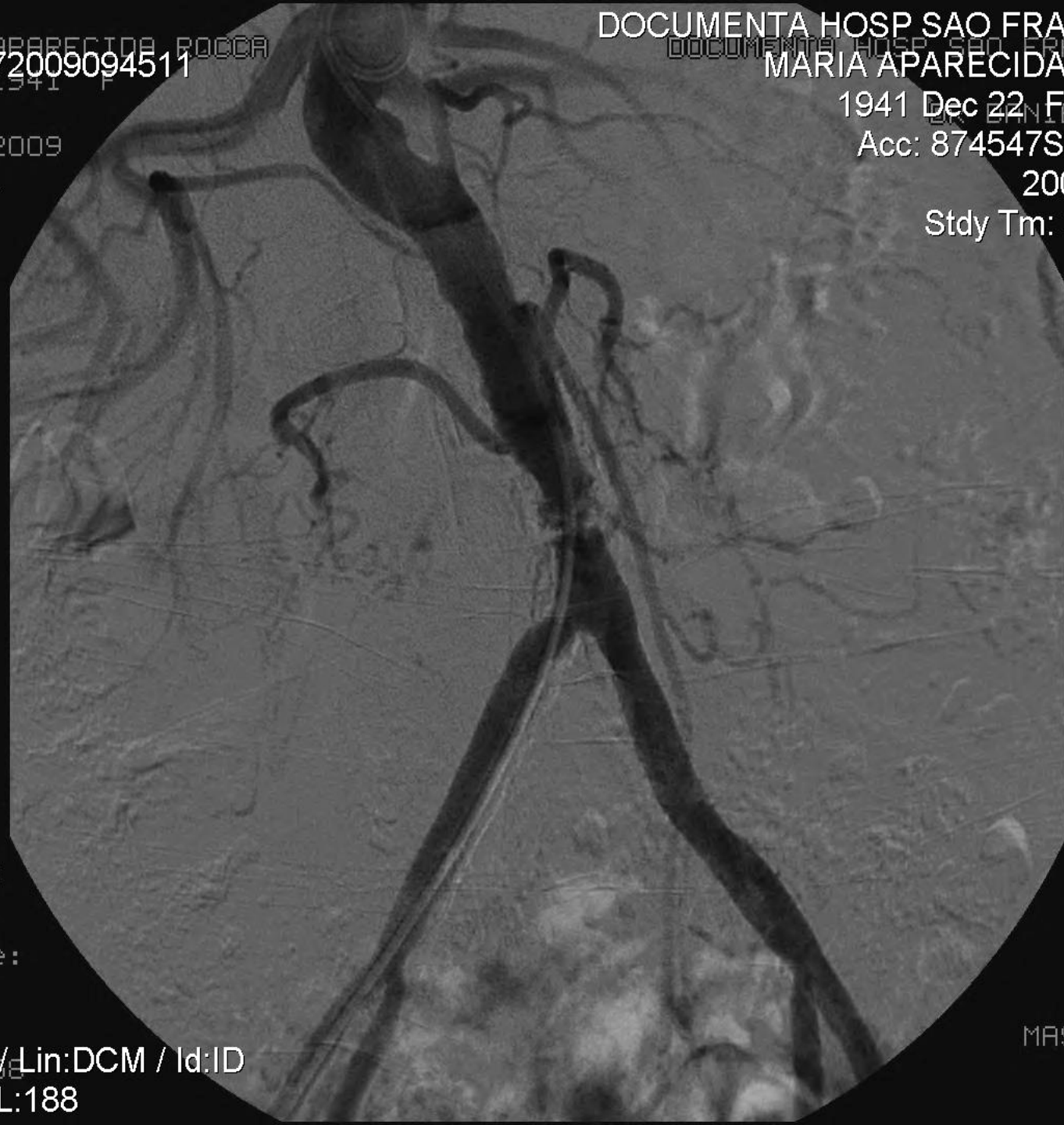(Filt. 5)
(Peak Op)
MASK = 1



VISUB
MARIA APARECIDA ROCCA
Ex: 21072009094511
22-12-1941 F
645574
Se: 1/5 2009
Im: 5/24

DOCUMENTA HOSP SAO FRANCISCO
DOCUMENTA HOSP SAO FRANCISCO
MARIA APARECIDA ROCCA
1941 Dec 22 F 645574
Acc: 874547S1135494
2009 Jul 21
StdY Tm: 09:45:11

LOSSY



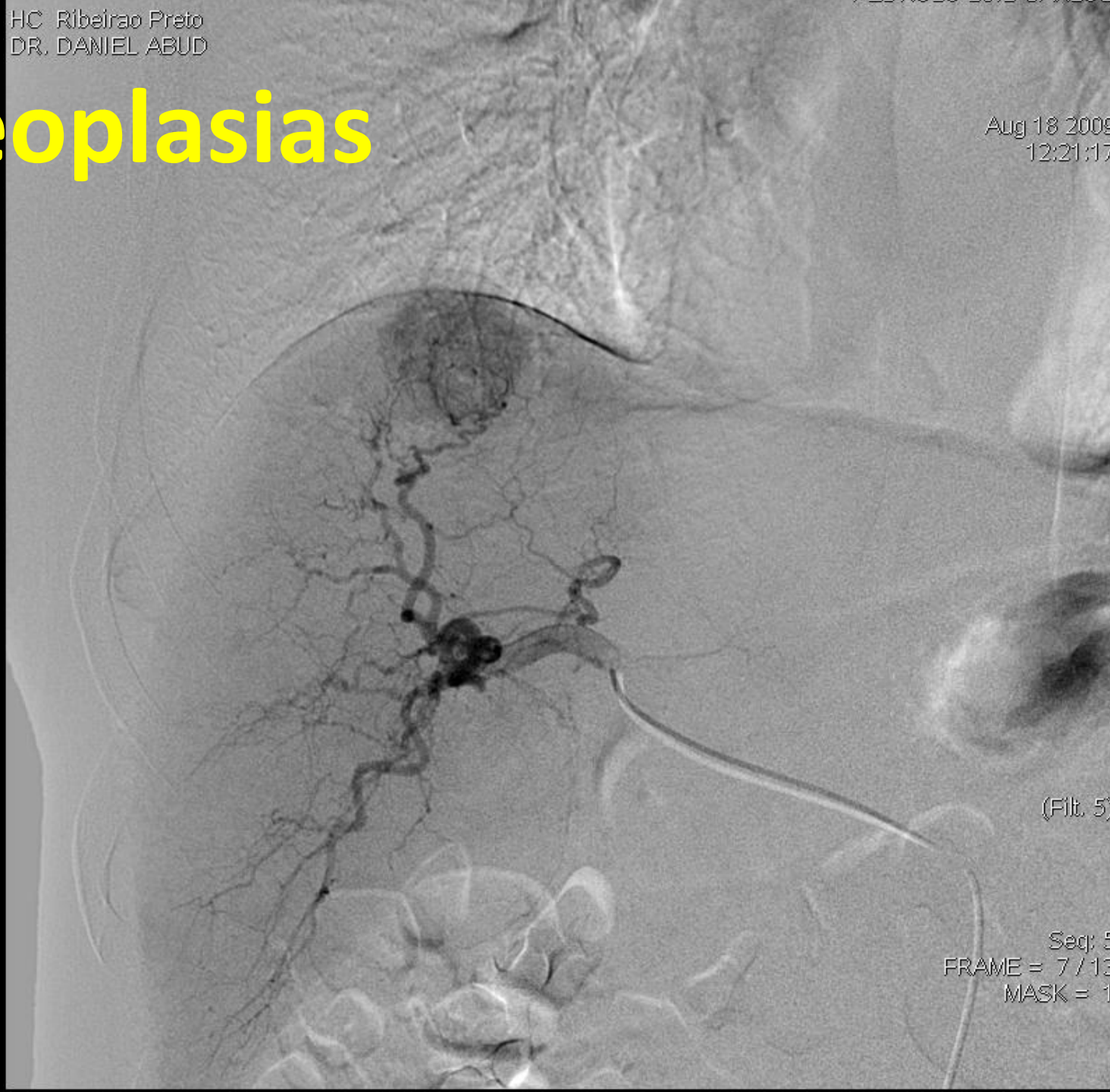
ROT
0
ANG
0

T-mask:
0.33
T-image:
2.33
T-pun:
10.10.58
Id:DCM / Lin:DCM / Id:ID
W:464 L:188

RUN
2
21
MASK IMAGE
2 8

Neoplasias

Aug 18 2009
12:21:17



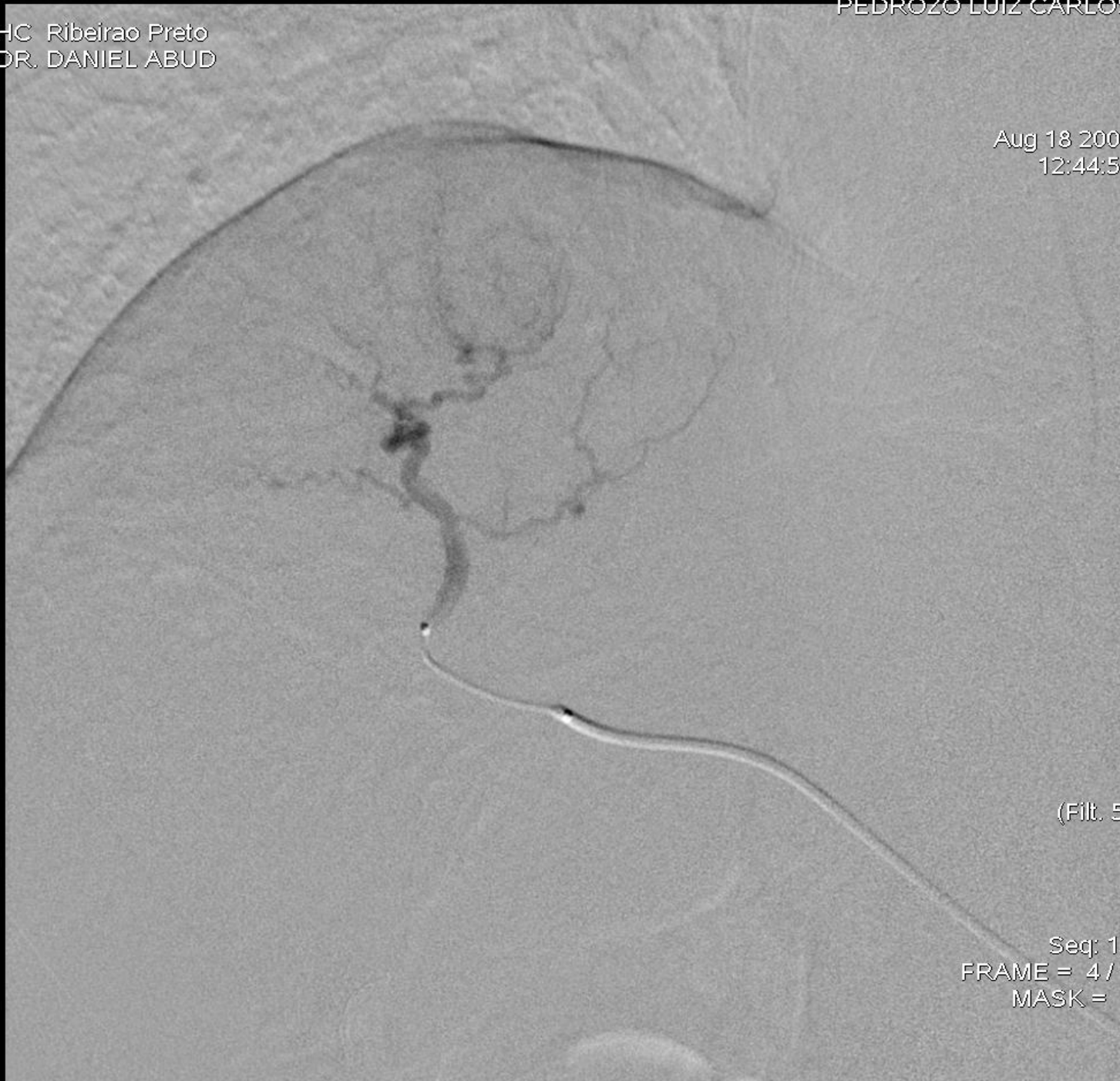(Filt. 5)

Seq: 5
FRAME = 7 / 13
MASK = 1

HC Ribeirao Preto
DR. DANIEL ABUD

PEDROZO LUIZ CARLOS

Aug 18 2009
12:44:58



(Filt. 5)

Seq: 15
FRAME = 4 / 9
MASK = 1

Complicações Neurológicas

exames seletivos de carótidas e vertebrais

- déficit neurológico transitório ou permanente
- amnésia global transitória
- distúrbio de consciência
 - menor que 0,5% em hospitais com equipe treinada

Complicações Locais

- **Trombose ou espasmo**
- **Sangramento prolongado**
- **Hematoma**
- **Fístula A-V**
- **Aneurisma e pseudoaneurisma**
- **Dor acentuada pós exame**



Diagnóstico por imagem no sistema vascular

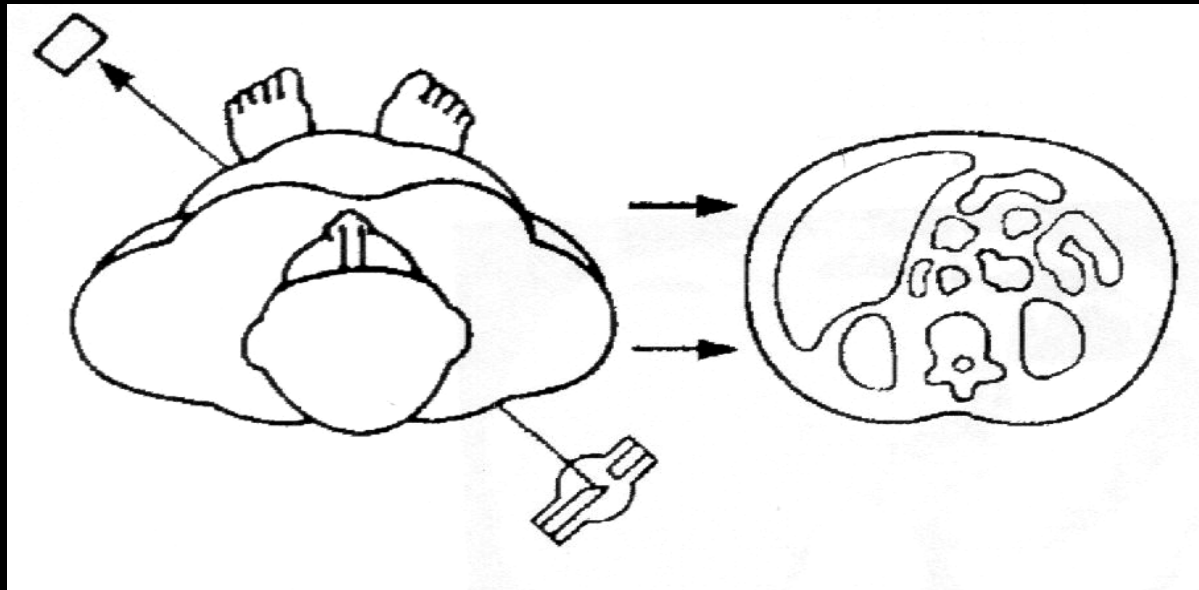
1. **Angiografia por Subtração Digital**
2. **Angiografia por Tomografia Computadorizada**
3. **Angiografia por Ressonância Magnética**

Angiografia por CT (angio-CT)

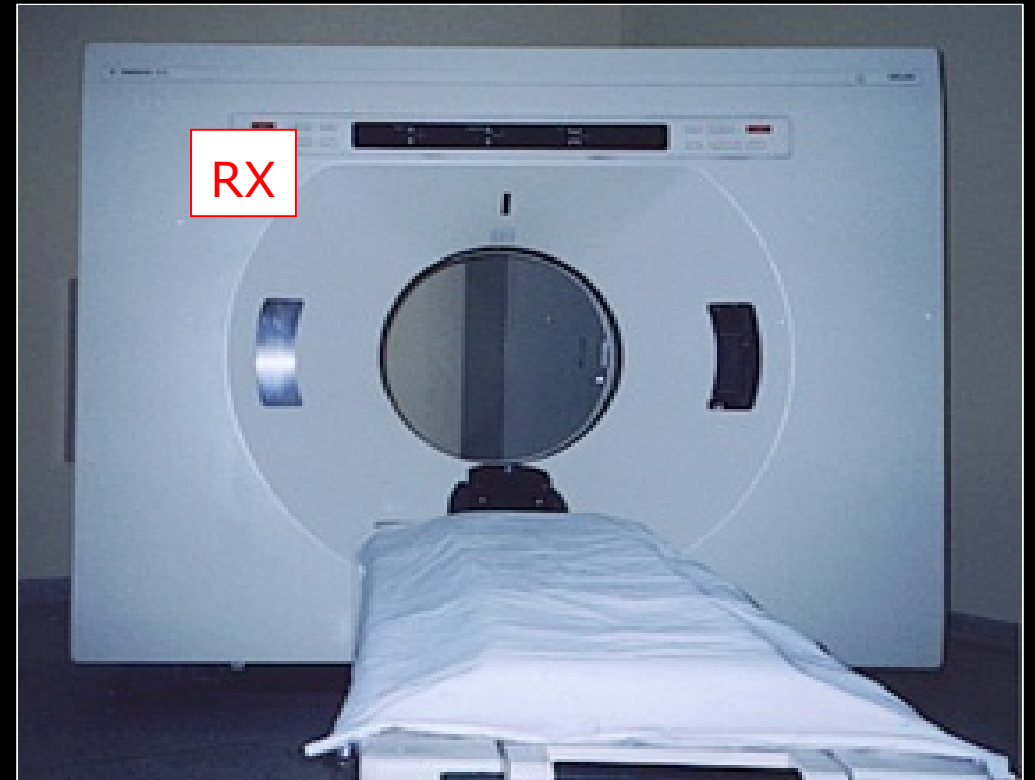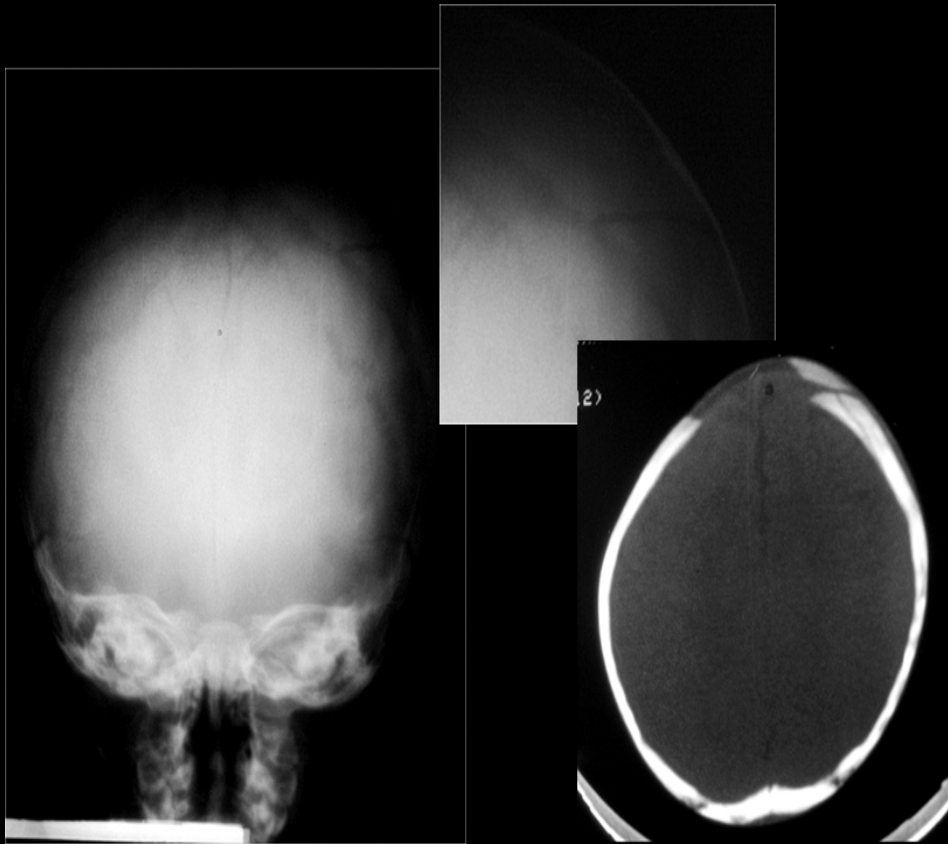
- **Não necessita cateterismo arterial**
- **Usa contraste iodado e radiação (RX)**
- **Menor resolução que ADS**
- **Permite medir densidade**
 - **Ver a parede do vaso, calcificações**
 - **Demonstra estruturas ósseas e pontos de referência**

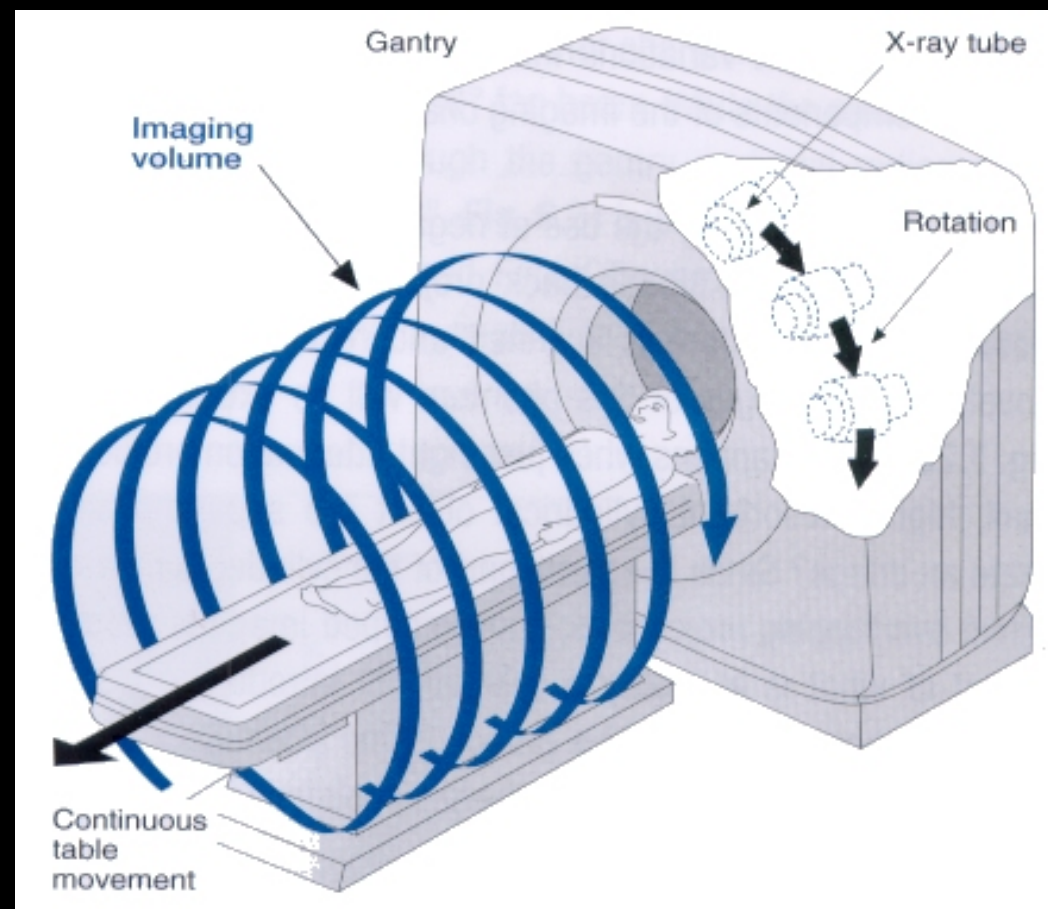
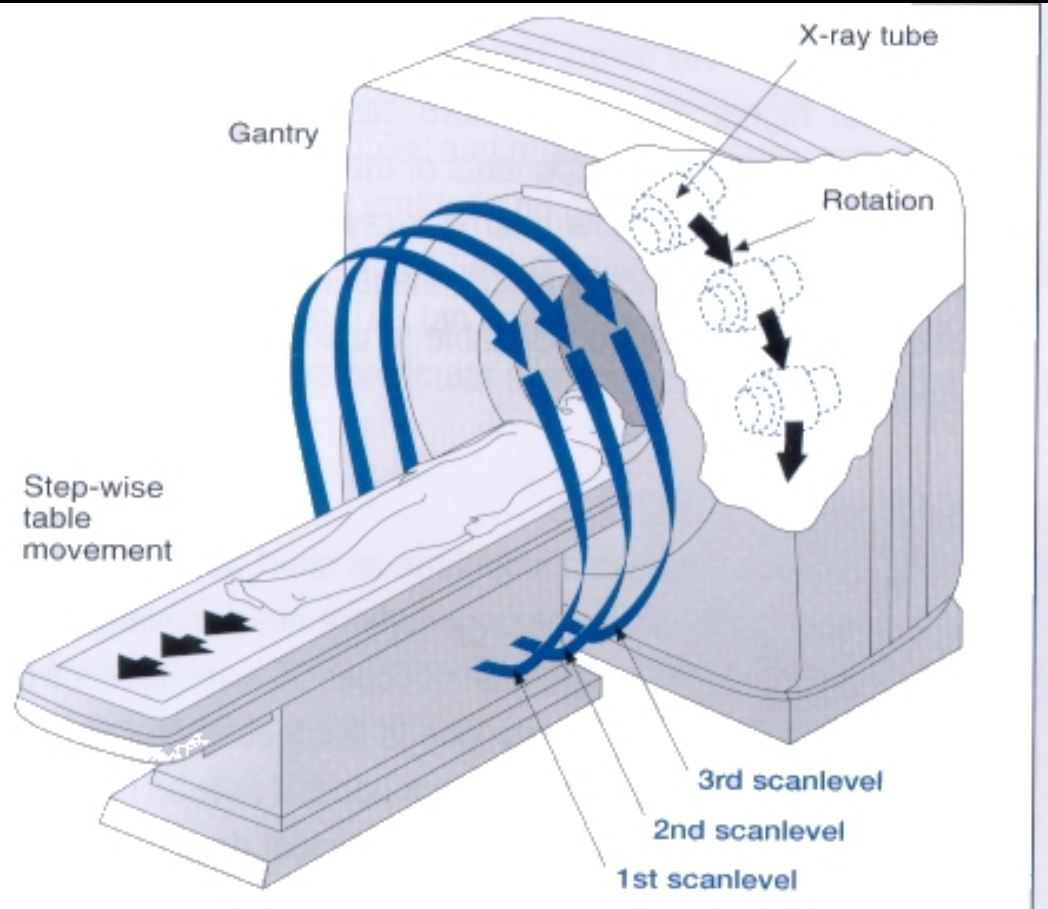
Princípio Tomográfico

- Obtenção de uma fatia fina do corpo, através da varredura feita por um feixe de Raio-x colimado, para se obter várias projeções medidas pelos detectores.



Tomografía computadorizada

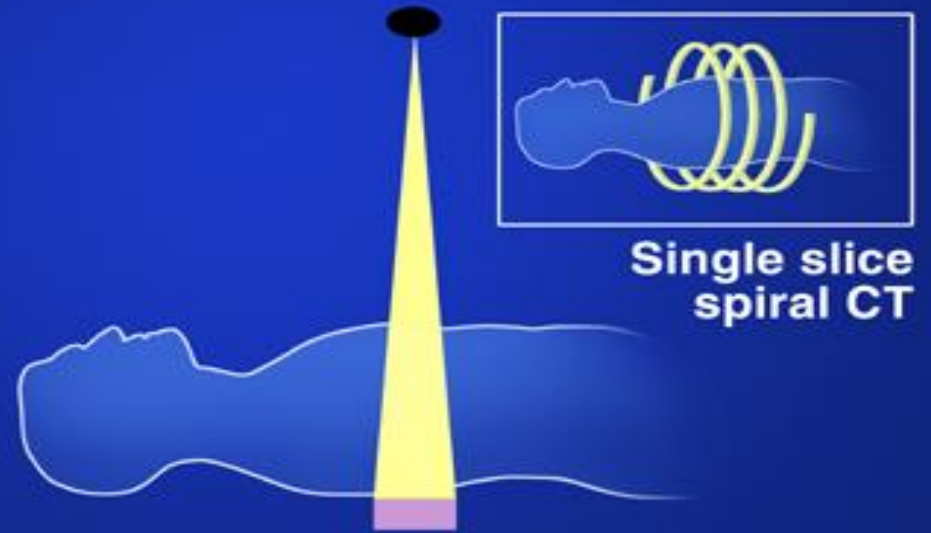
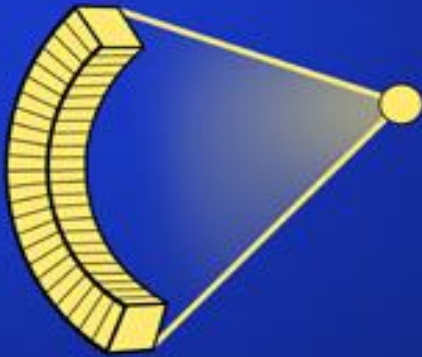




Single Slice

- Fileira única de receptores

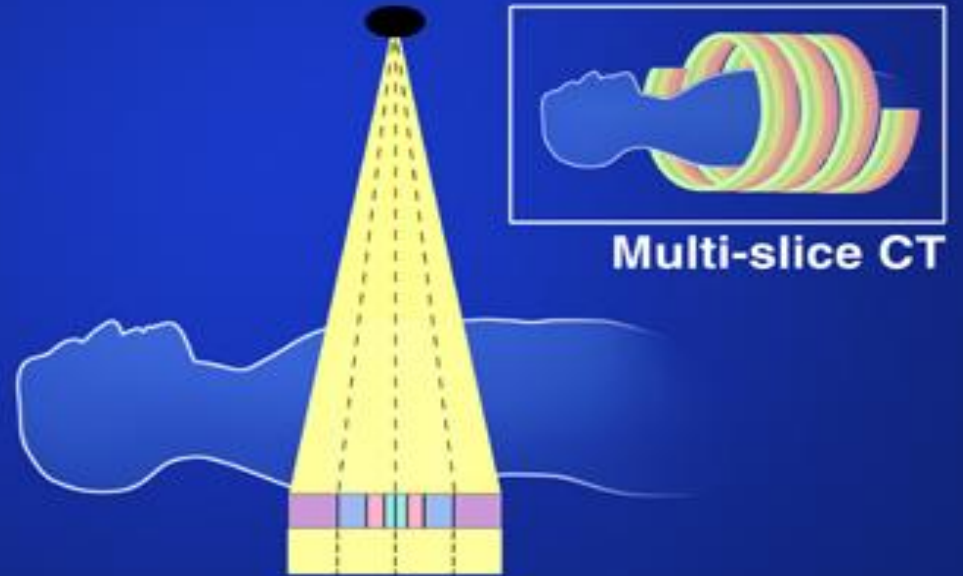
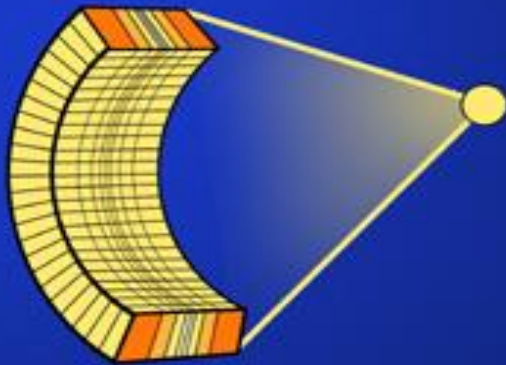
SDCT


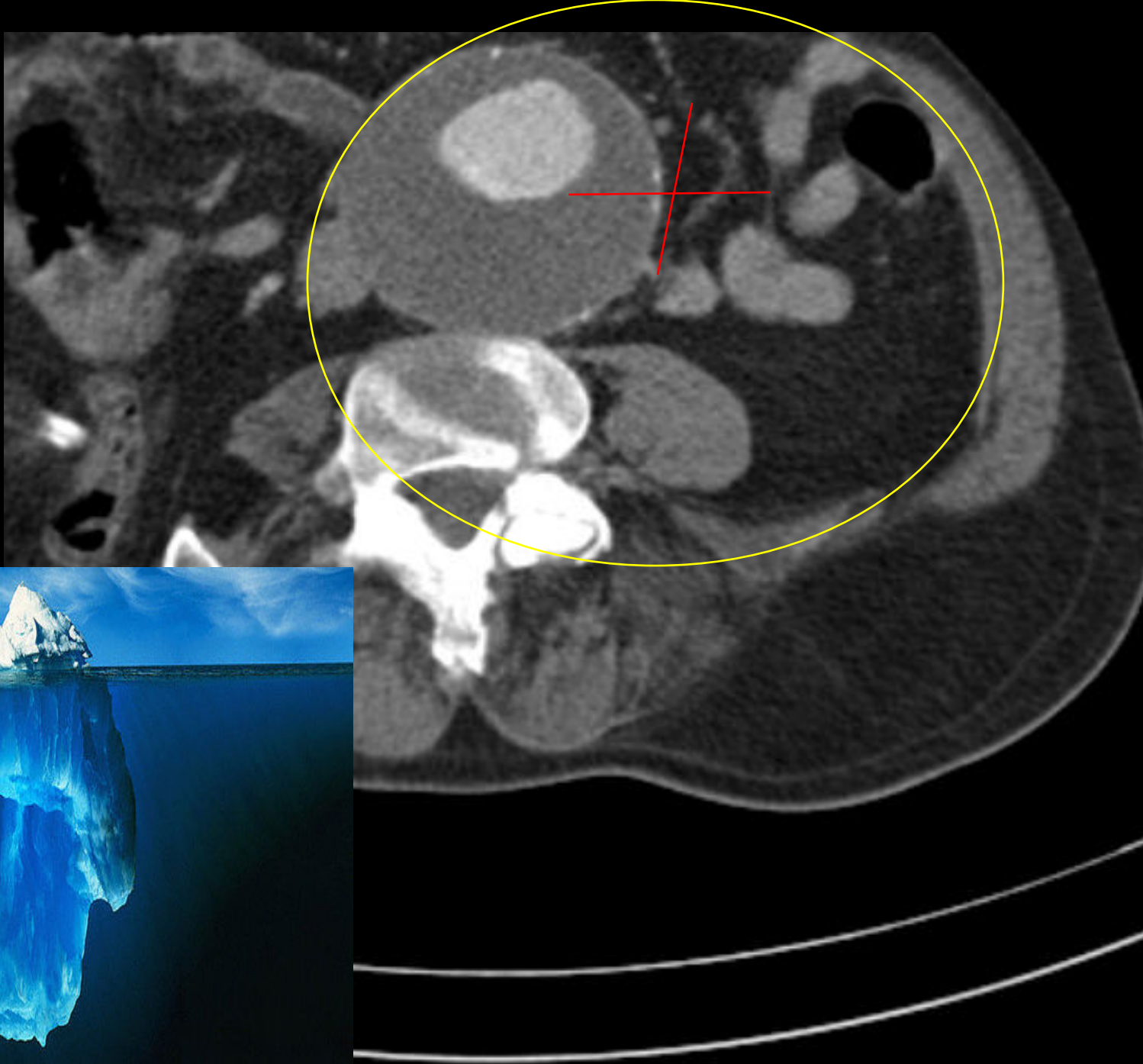

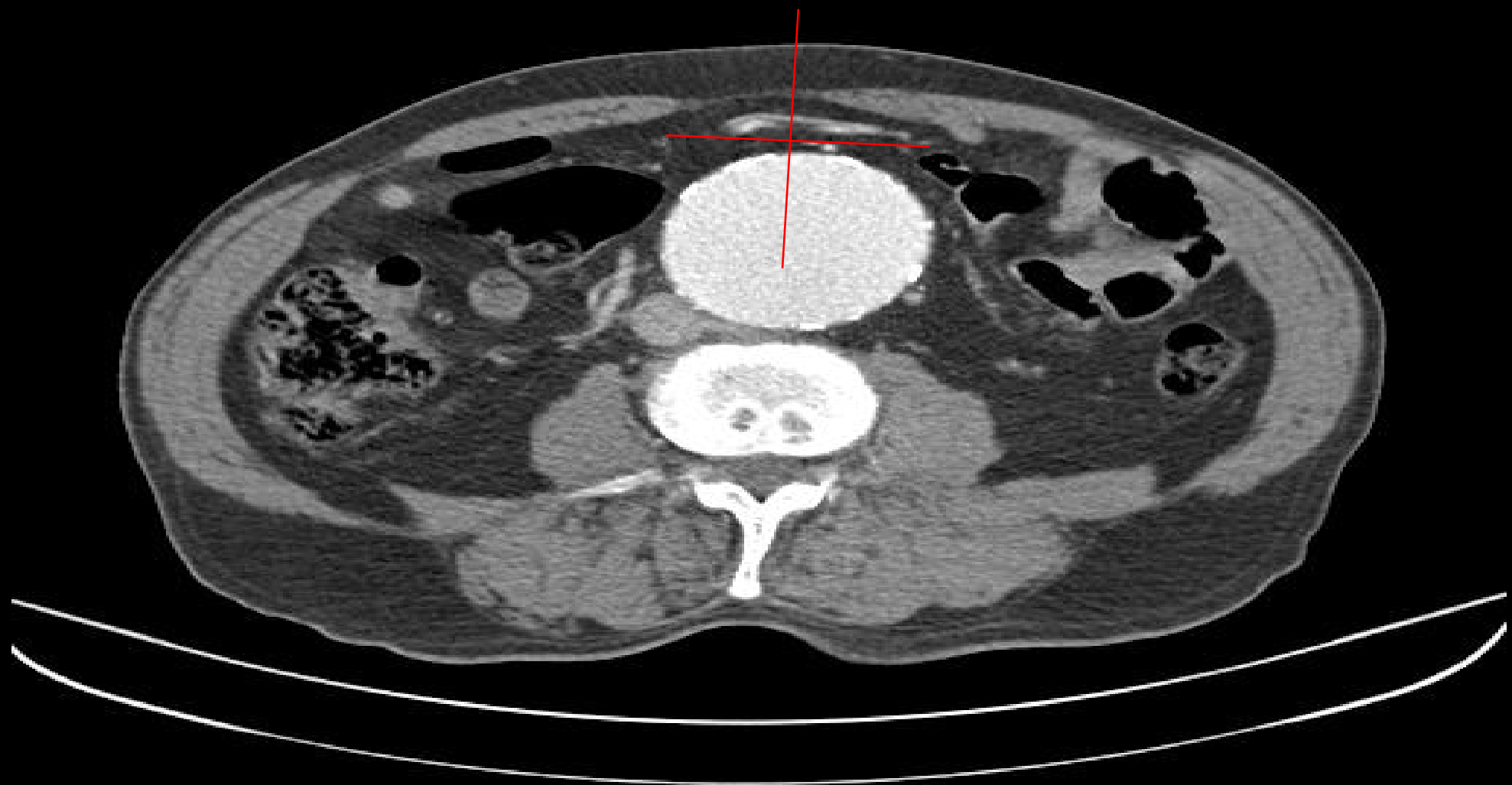
Multi Slice

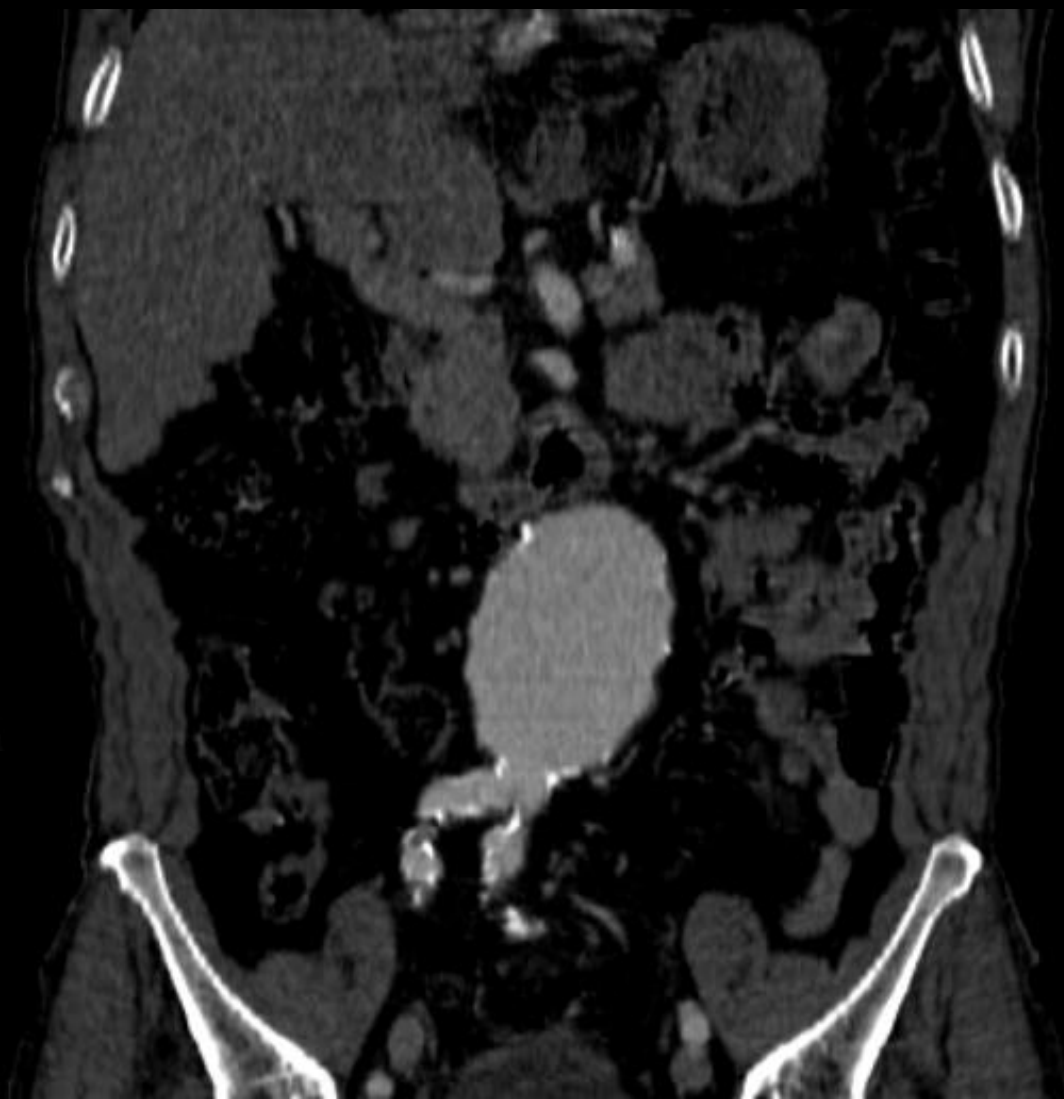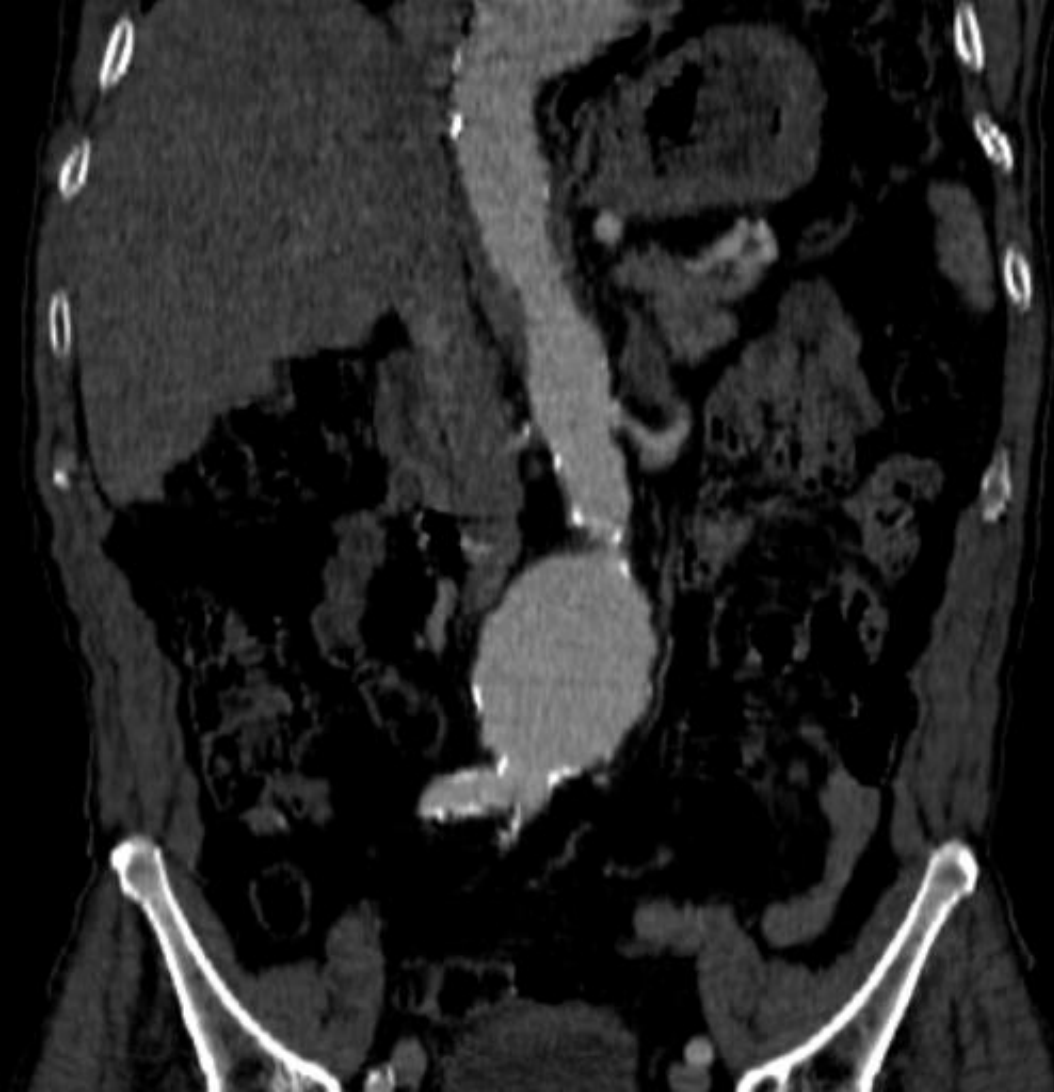- Múltiplas fileiras de receptores

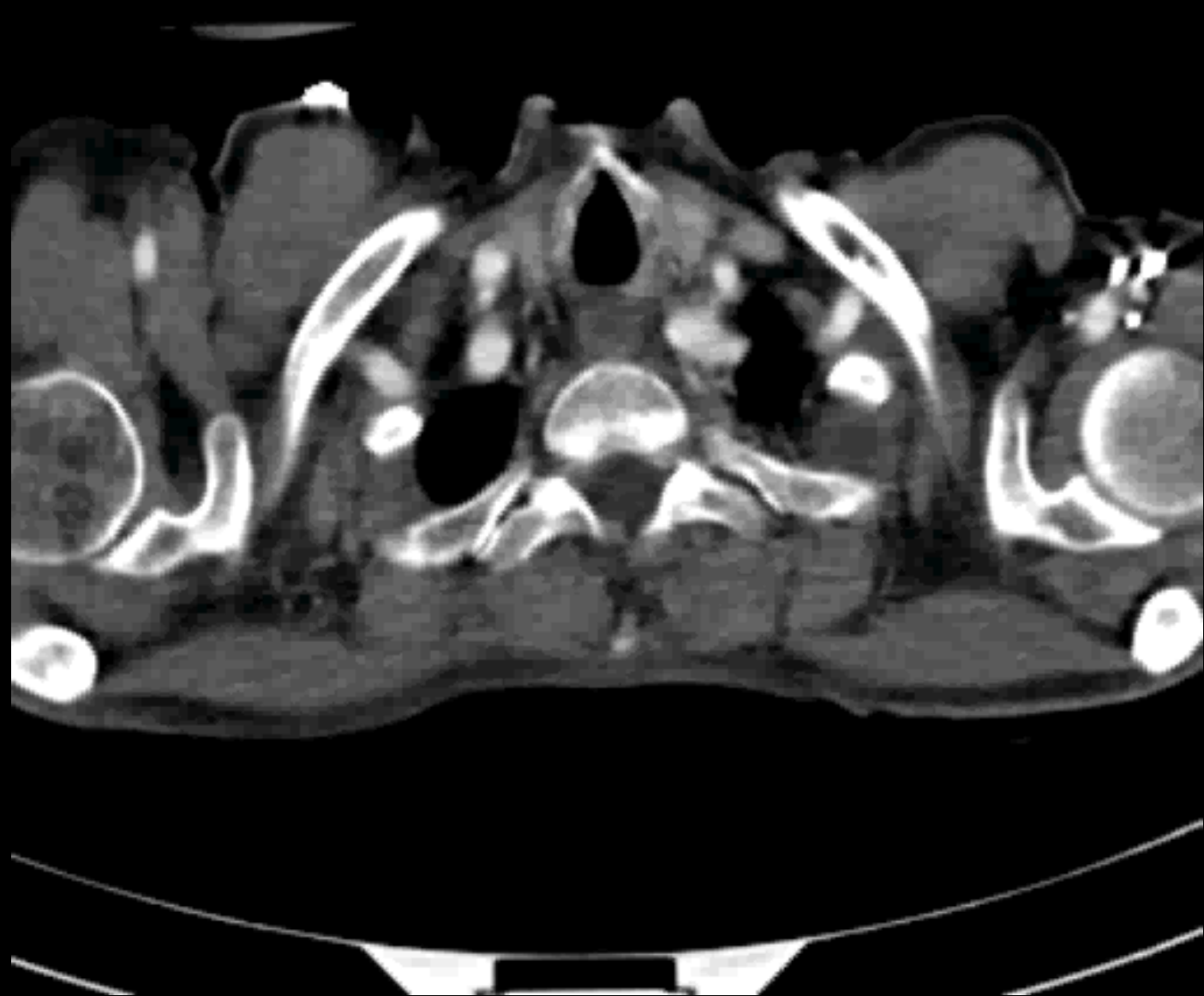
MDCT











3D

LUIZ GALHARDI

Volume Rendering No cut

Ex: Jul 08 2009

Non GE image
DFOV 26,0 cm
B20s

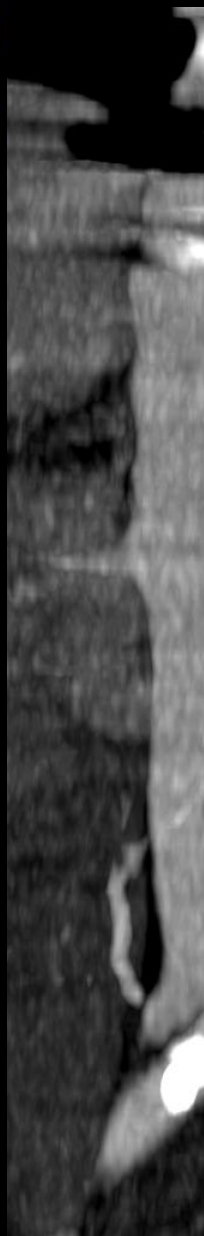
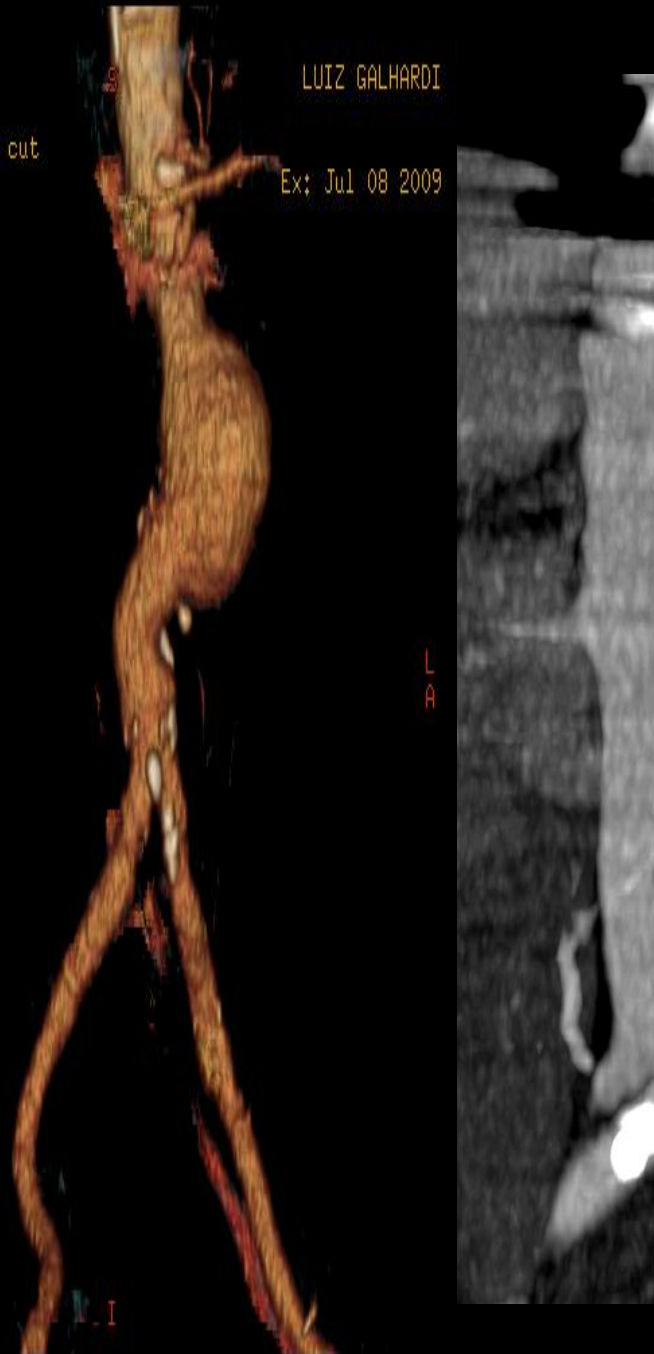R
P

L
A

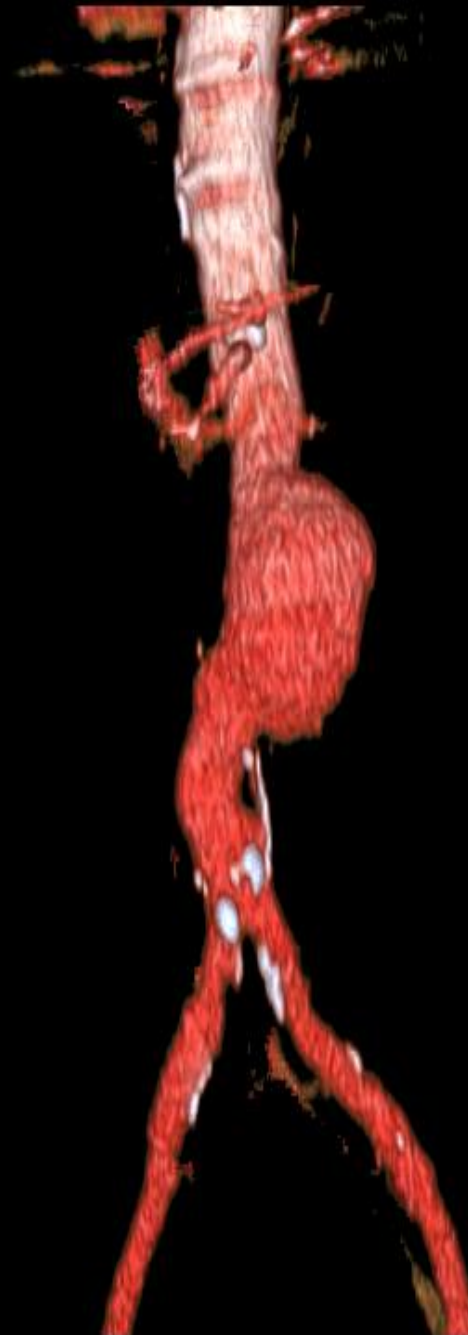
No VOI

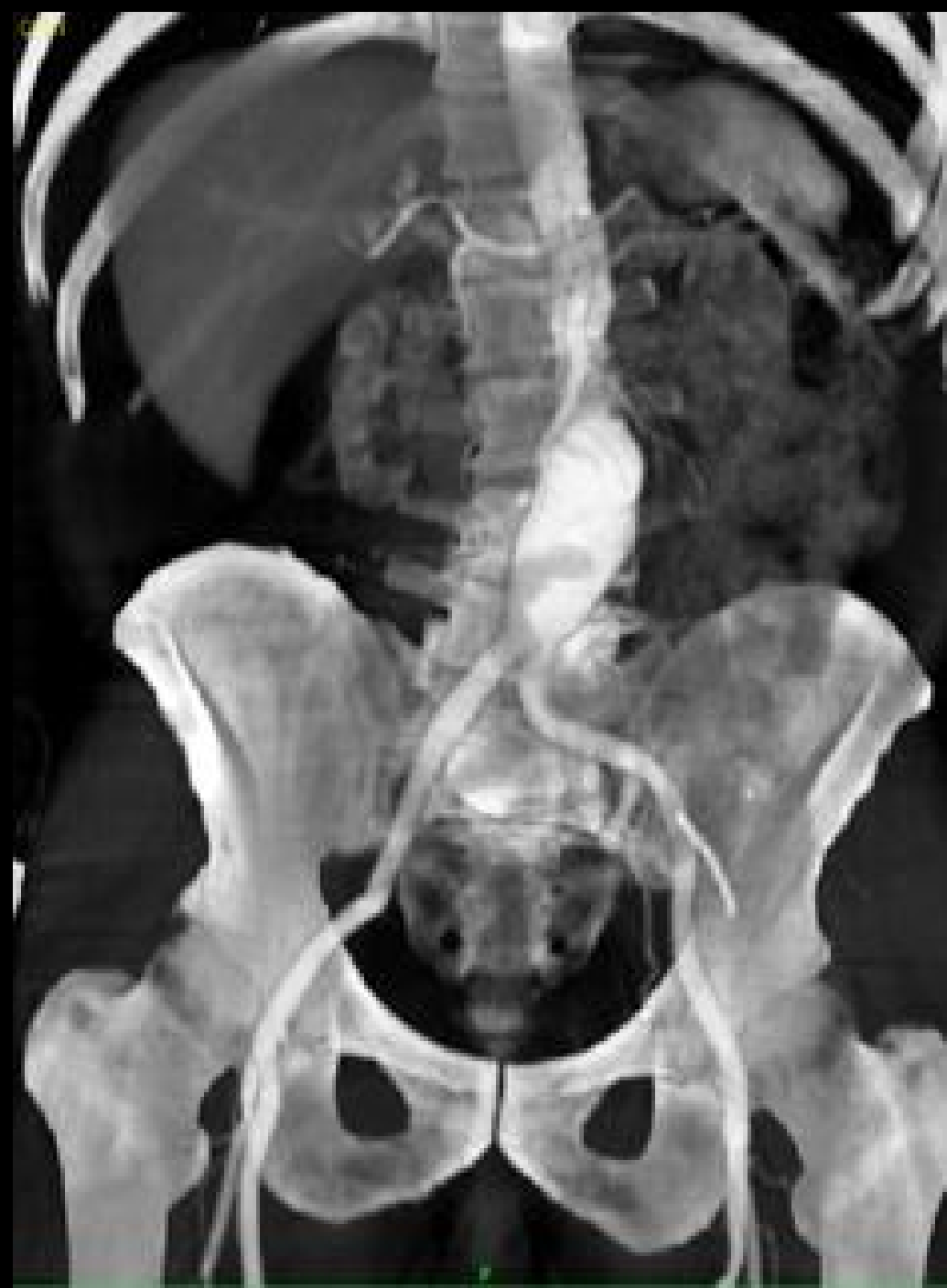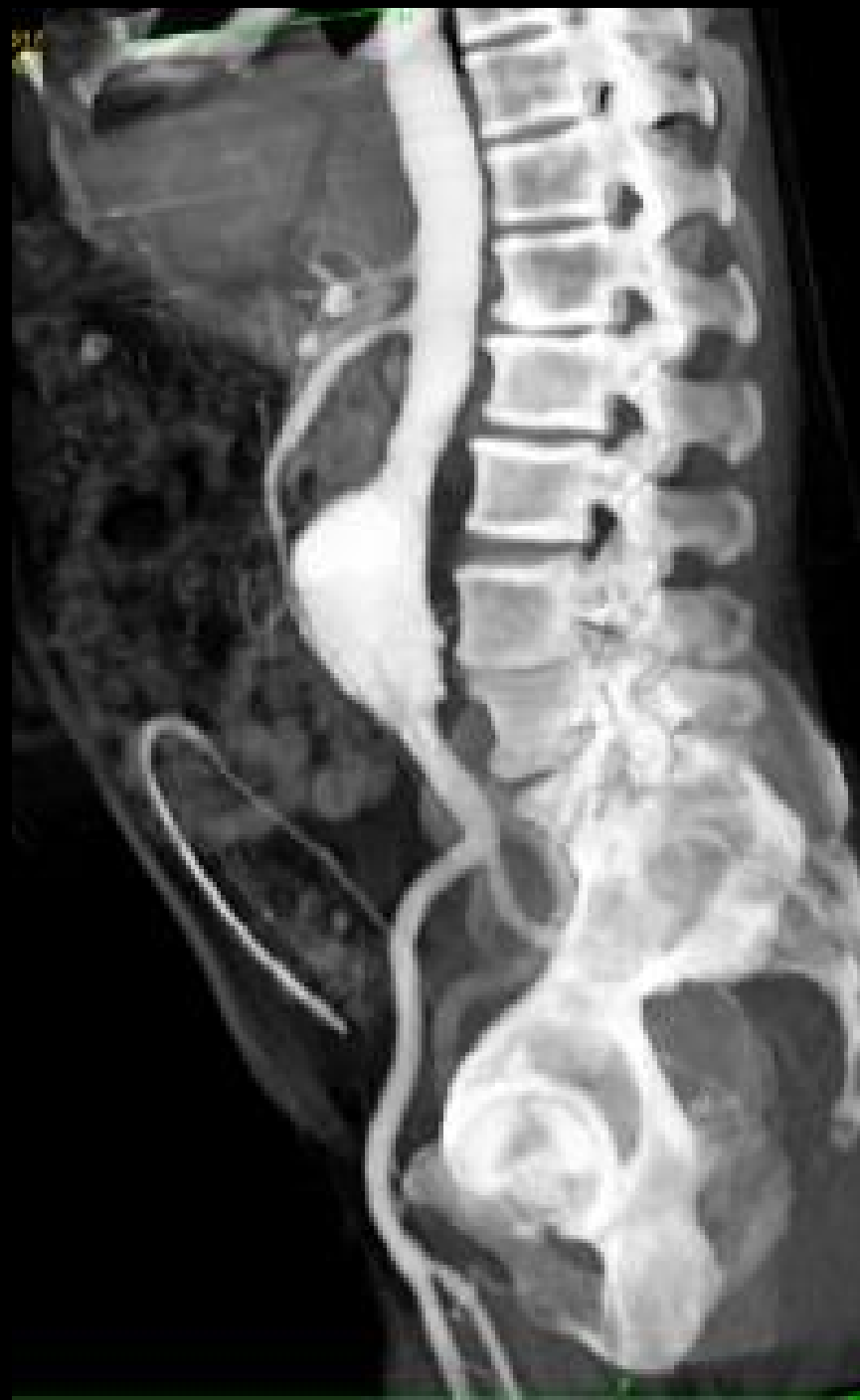3,0mm /1,5sp

W = 396 L = 396

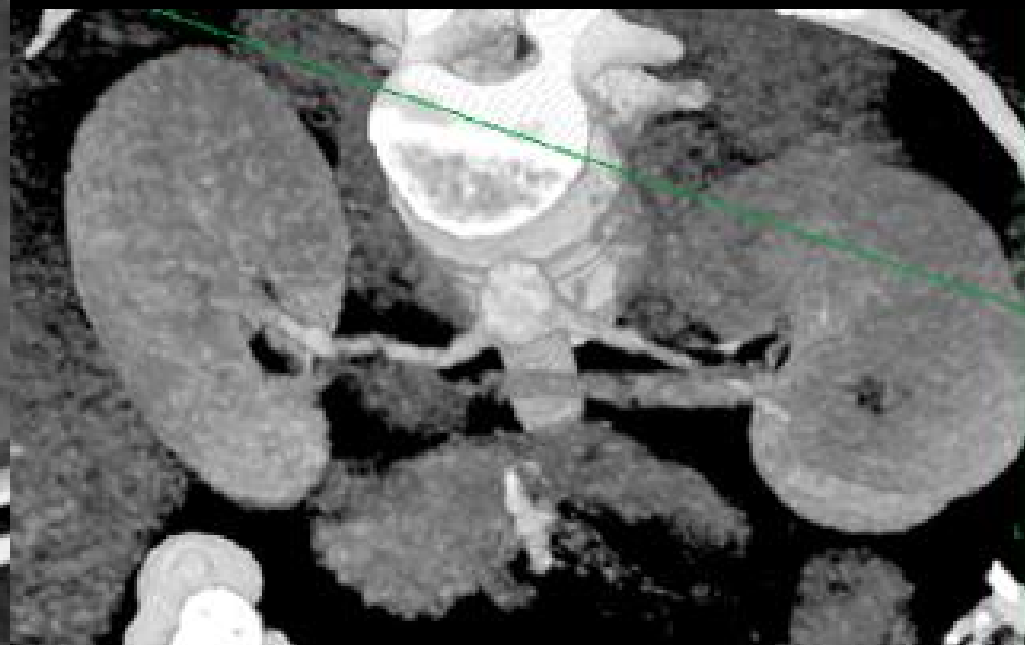
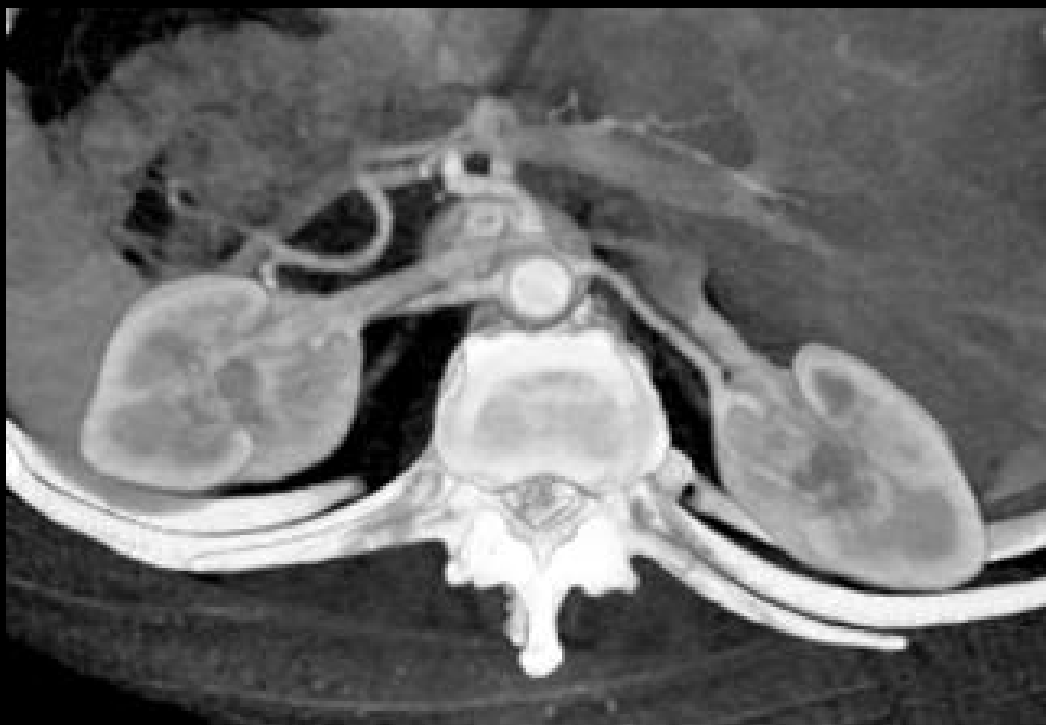
Non GE image

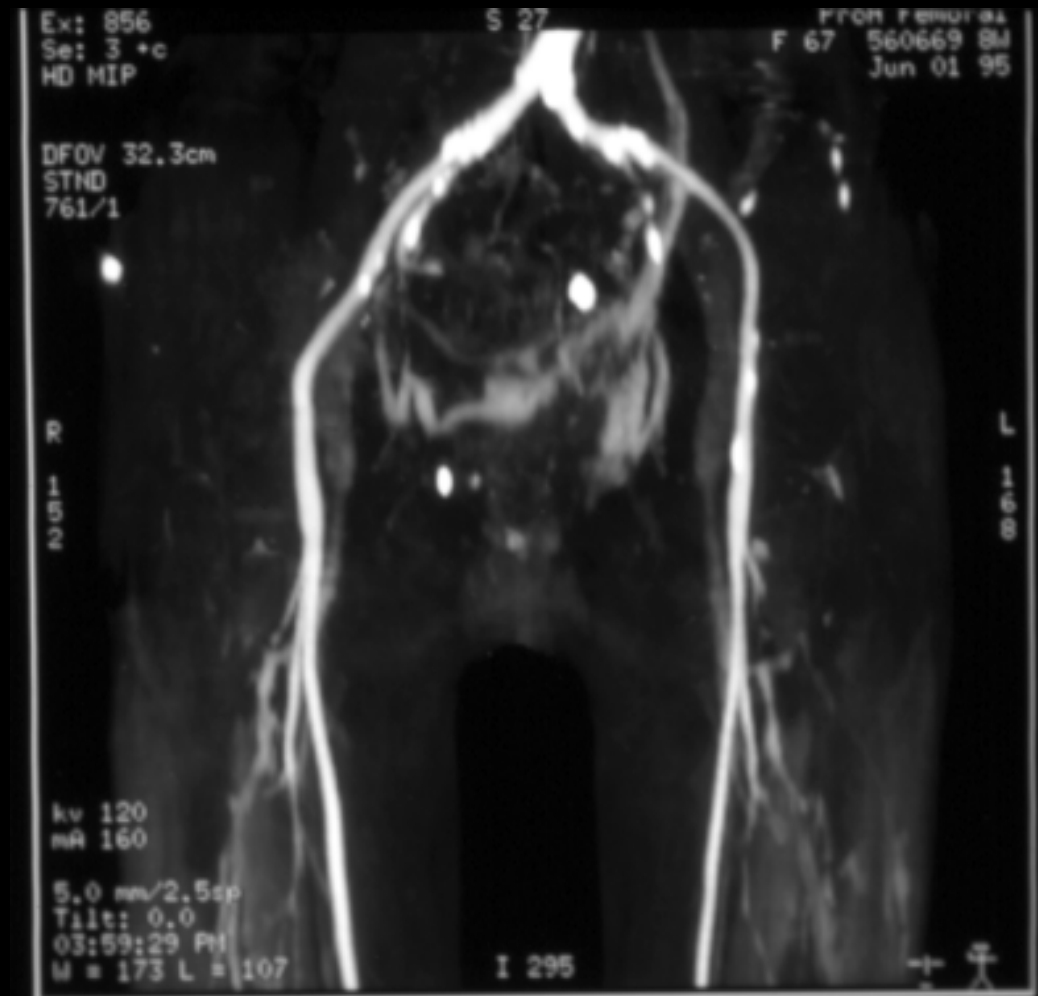
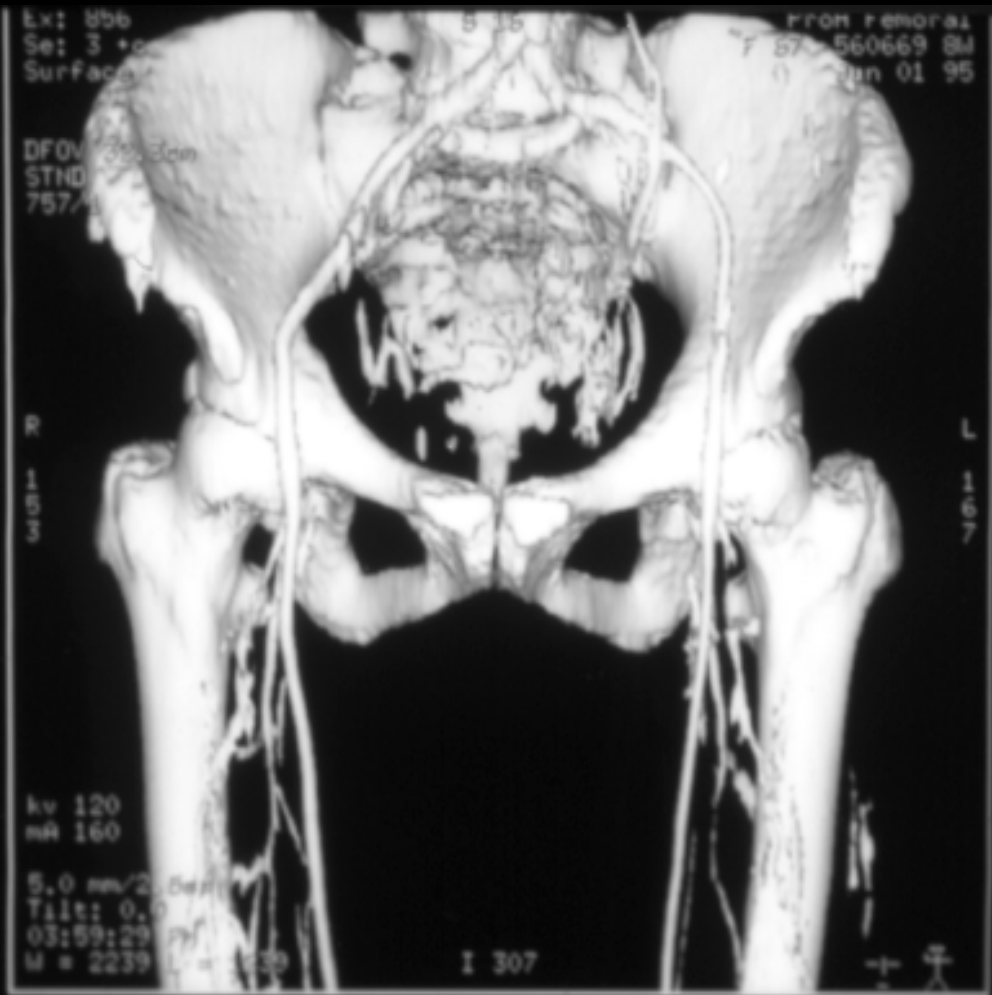



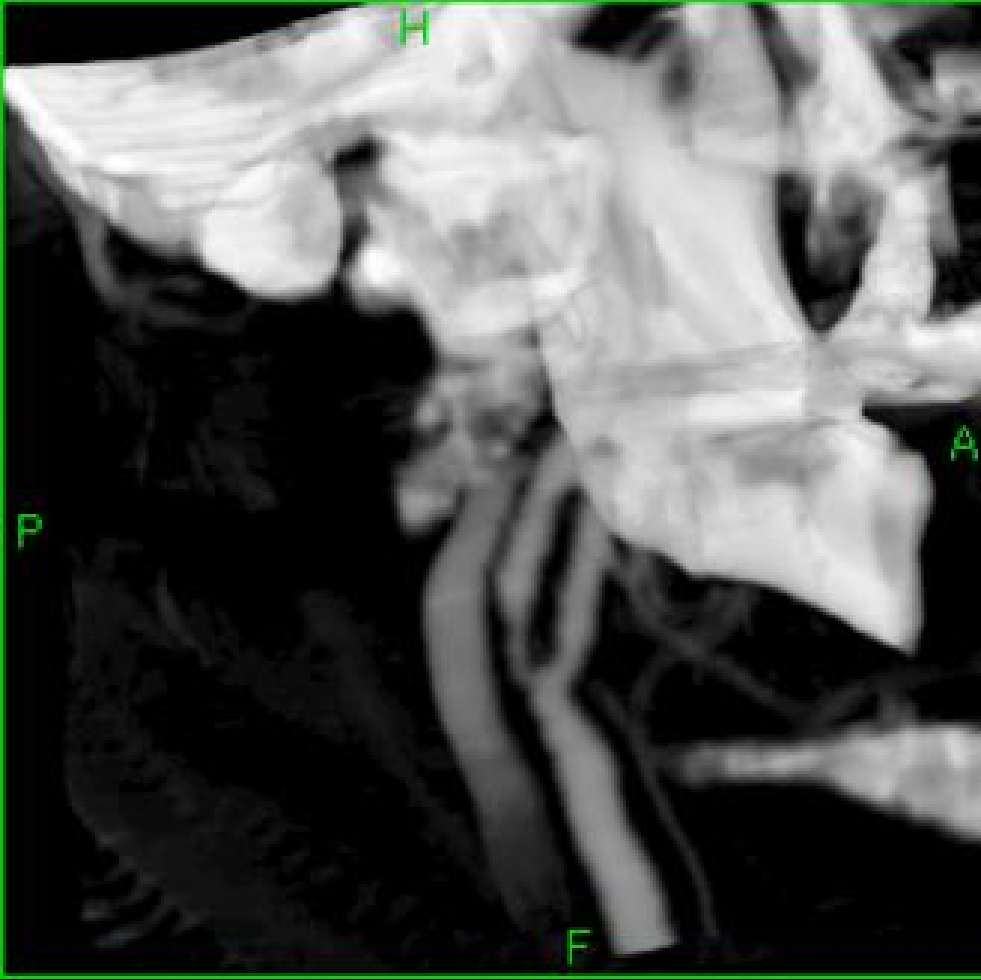
Artérias Renais



Membros Inferiores



Carótidas





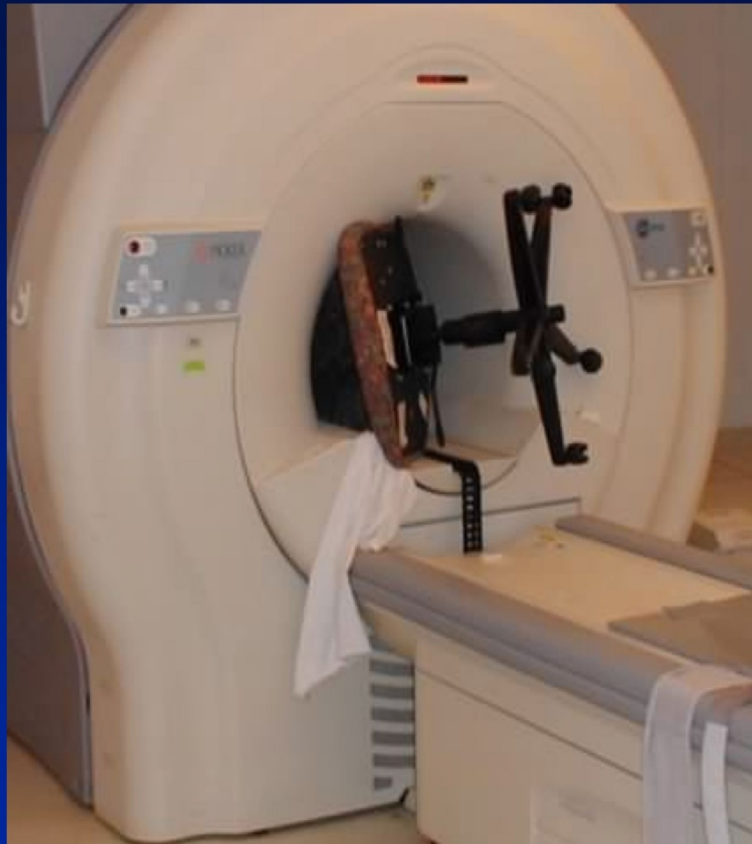Diagnóstico por imagem no sistema vascular

1. **Angiografia por Subtração Digital**
2. **Angiografia por Tomografia Computadorizada**
3. **Angiografia por Ressonância Magnética**

Angiografia por RM (angio-RM)

- Não necessita cateterismo arterial
- Não usa contraste iodado e radiação (RX)
- Menor resolução que ADS
- O sinal é proveniente dos prótons de H⁺, previamente excitados por pulsos de radiofrequência
- Não permite medir densidade
- Não mostra a parede do vaso, somente fluxo
- Não mostra calcificações ou estrutura óssea

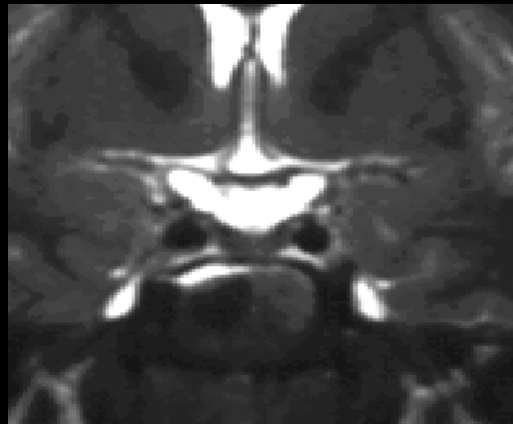Ressonância Magnética



1,5 Teslas = 30.000 x campo magnético da Terra!

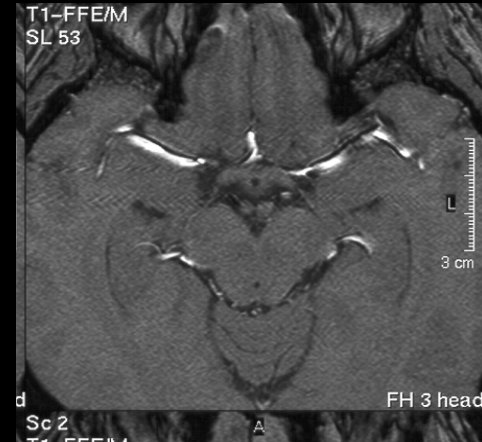
Angiografia por RM (angio-RM)

Fluxo sanguíneo



Spin eco

VASOS ESCUROS (FLOW-VOID)

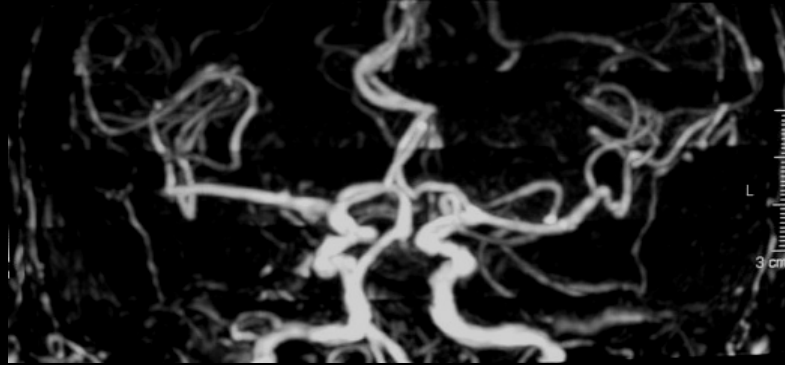


Gradiente eco

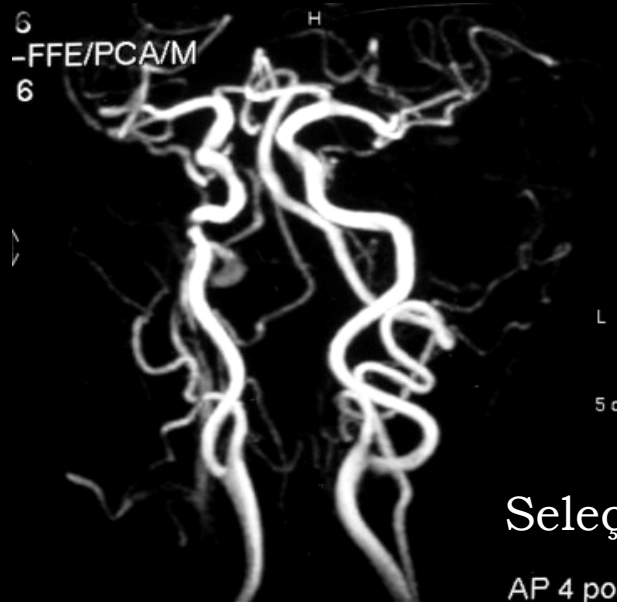VASOS BRILHANTES (GRE)

Angiografia por RM (angio-RM)

- **TOF**- TIME OF FLIGHT (TEMPO DE VÔO)



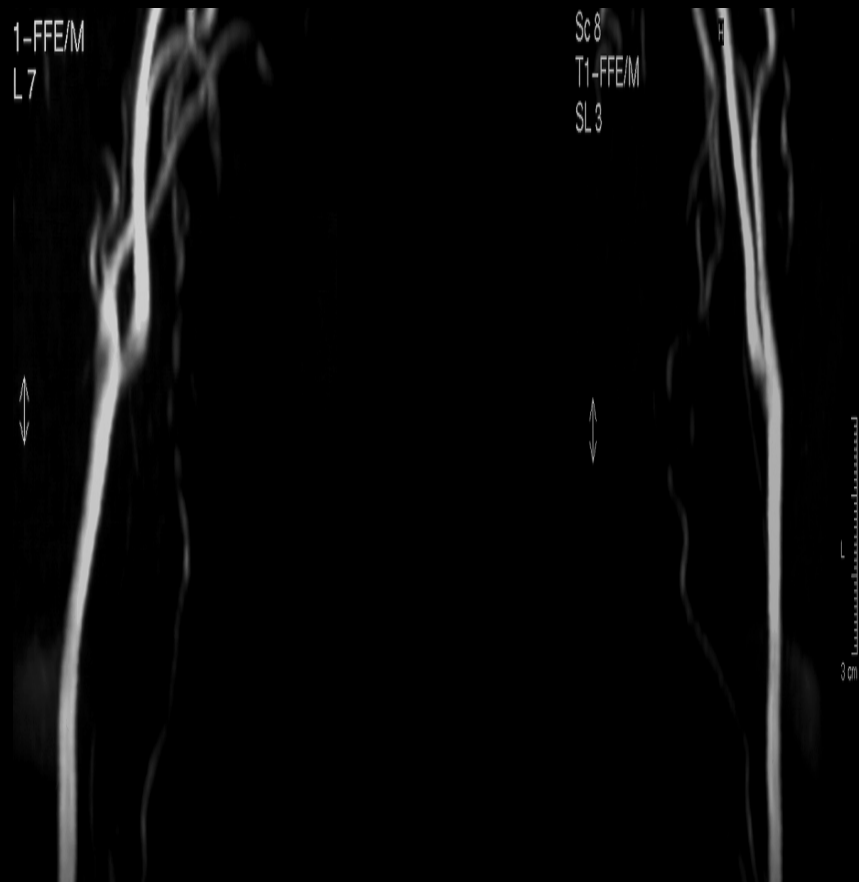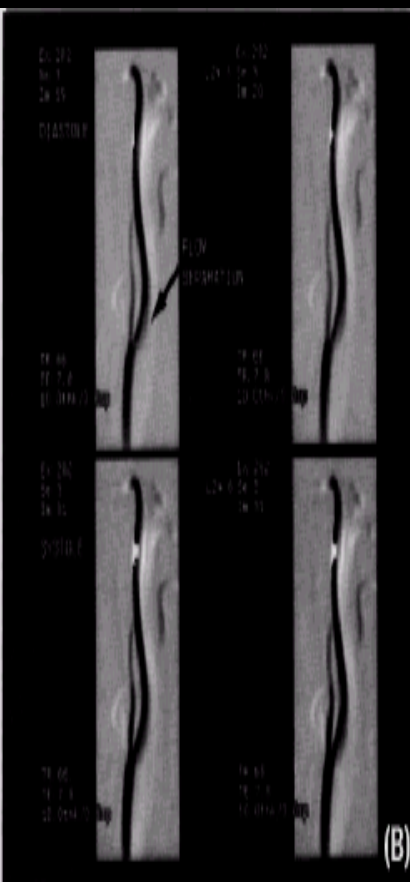
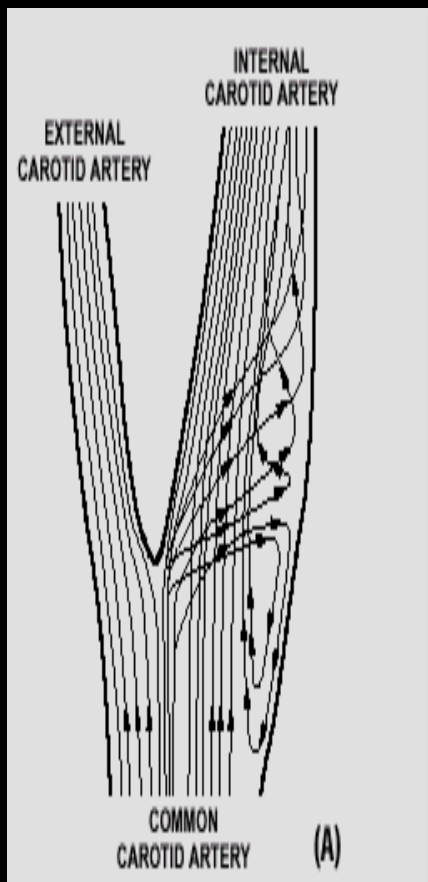
- **PC** - PHASE CONTRAST (CONTRASTE DE FASE)



Seleção do fluxo (arterial ou venoso)

Efeitos de Fluxo

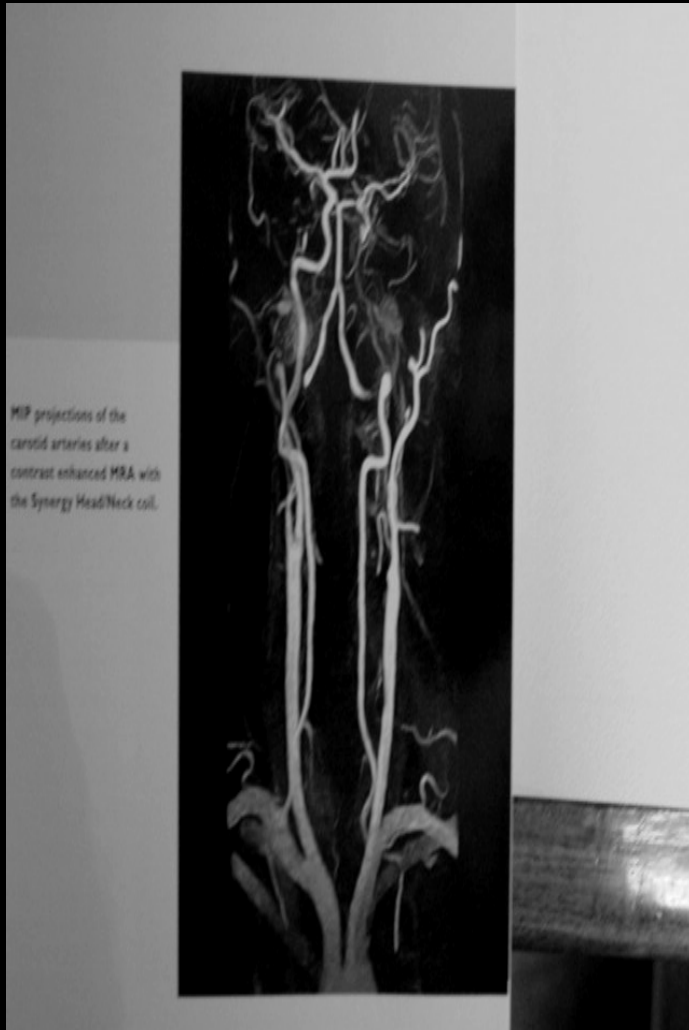
Fluxo Turbulento ► Bifurcação dos vasos



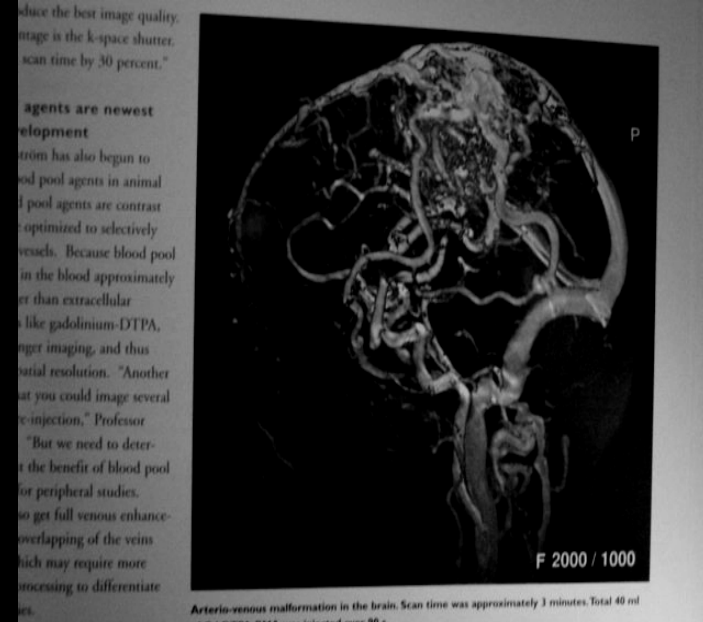
TOF

TOF

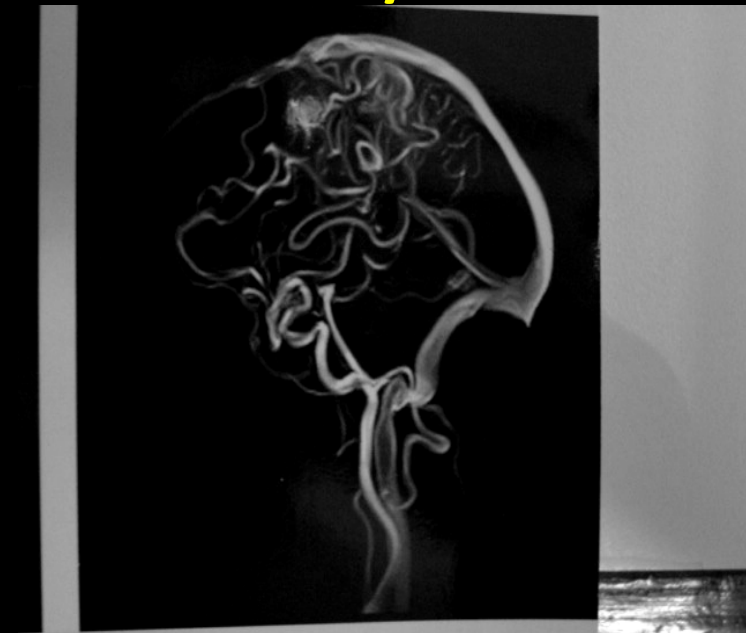Contraste de fase (PC) Mapa da velocidade de fase



Arterial: 70 cm/s



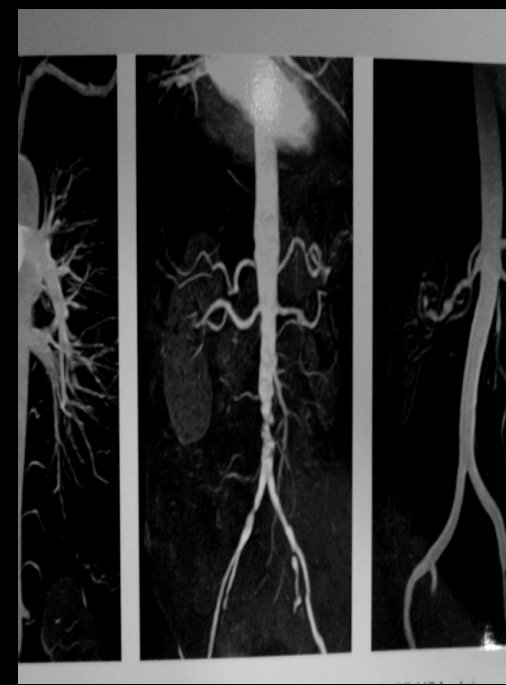
MAV: 30 cm/s



Venoso: 15 cm/s

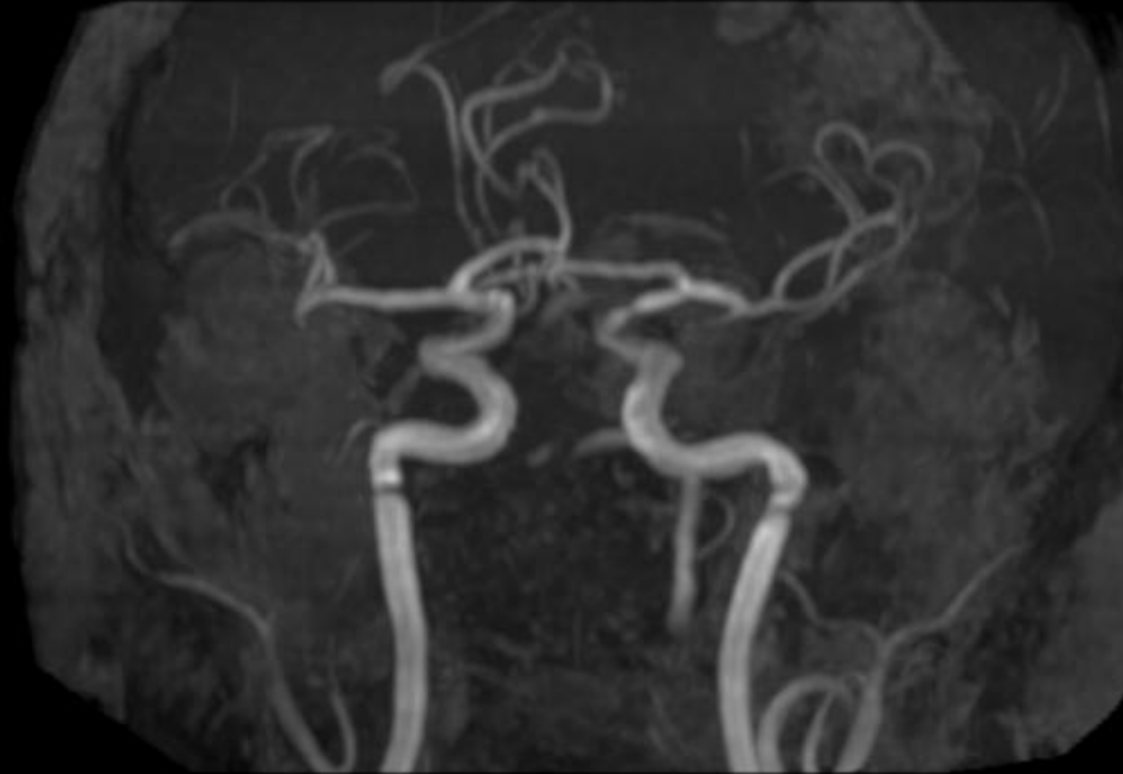ANGIOGRAFIA POR RM COM GADOLÍNIO

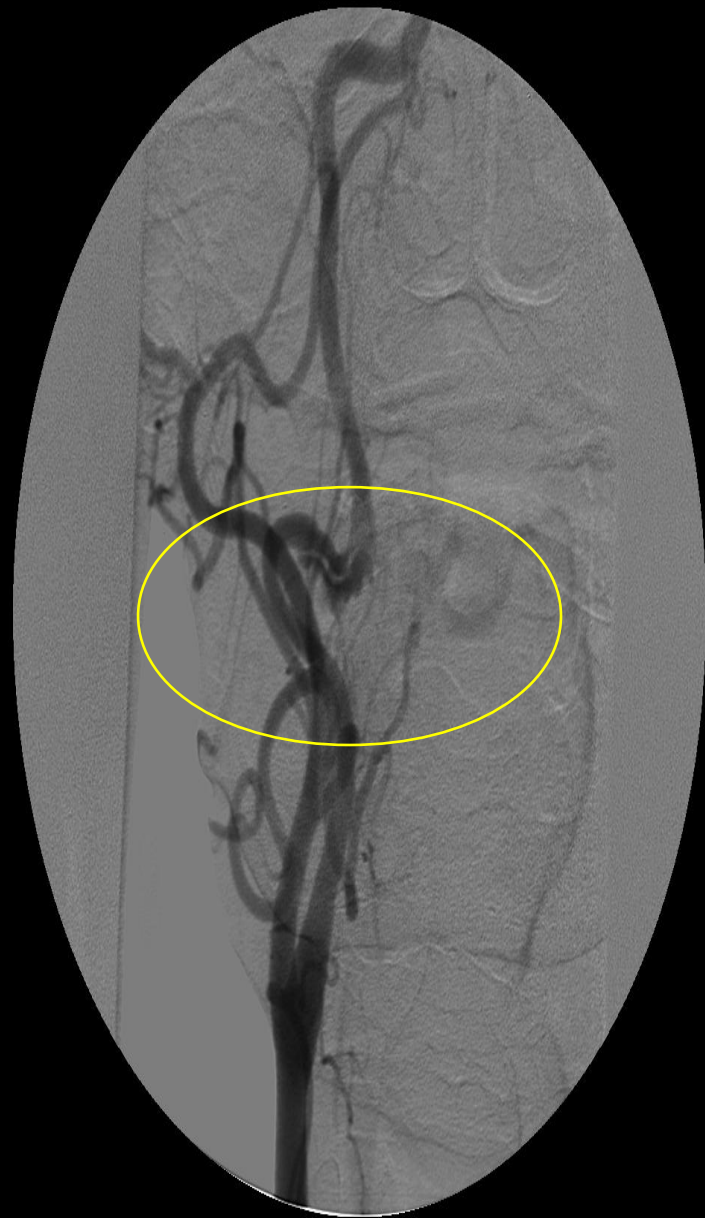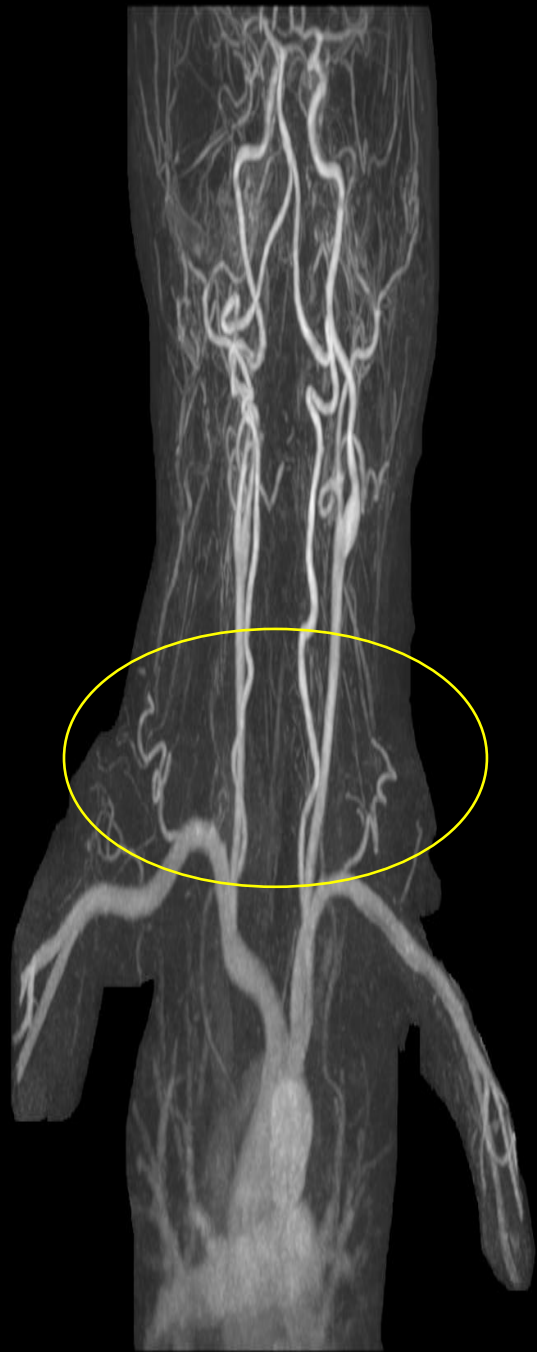- Aumento do sinal no vaso, devido ao agente paramagnético.
- Menor influência dos efeitos de fluxo.
- Avaliação mais fiel do grau de estenose.

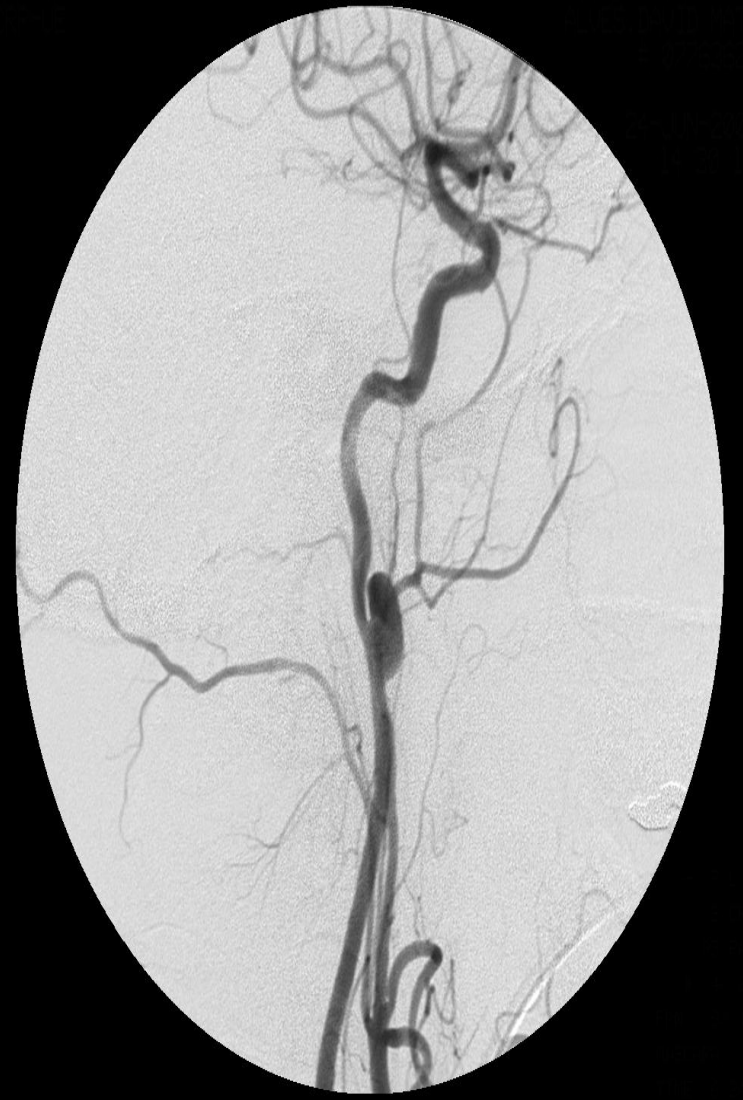
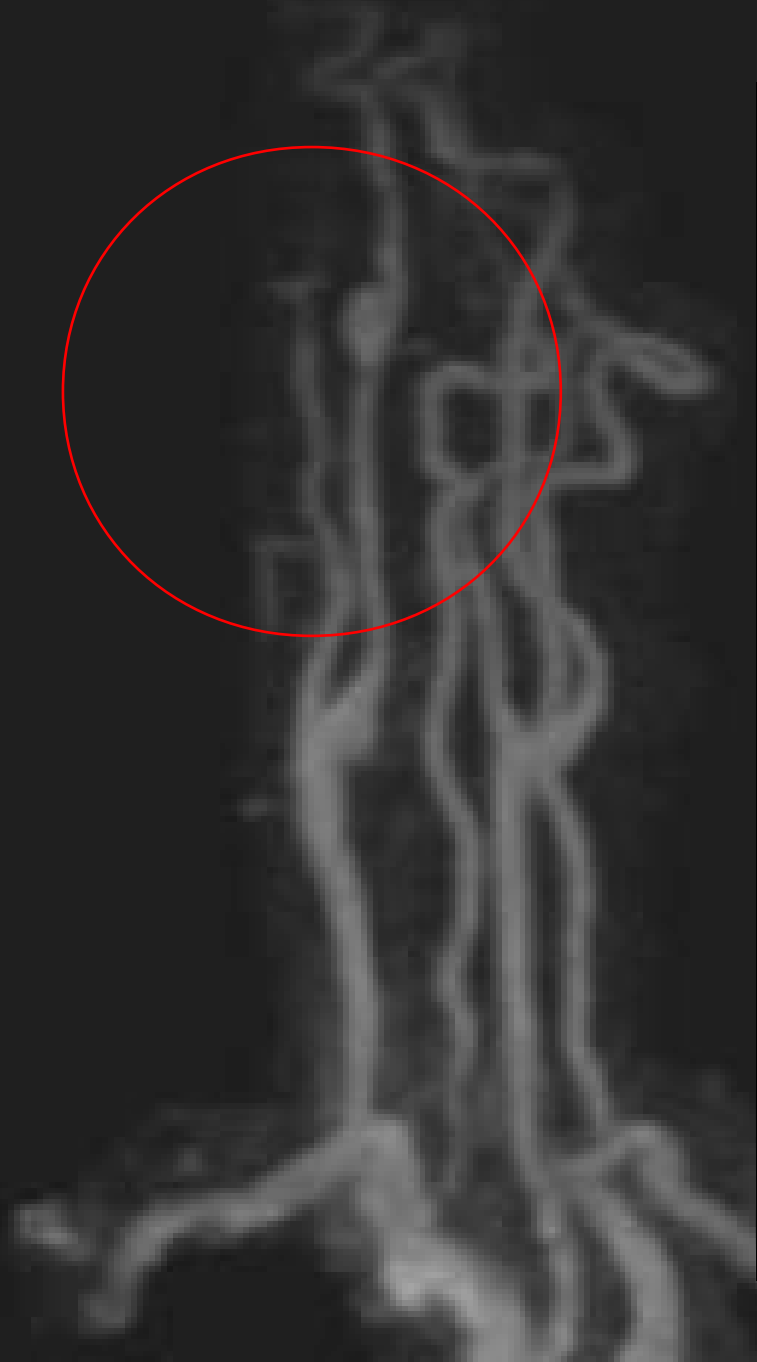
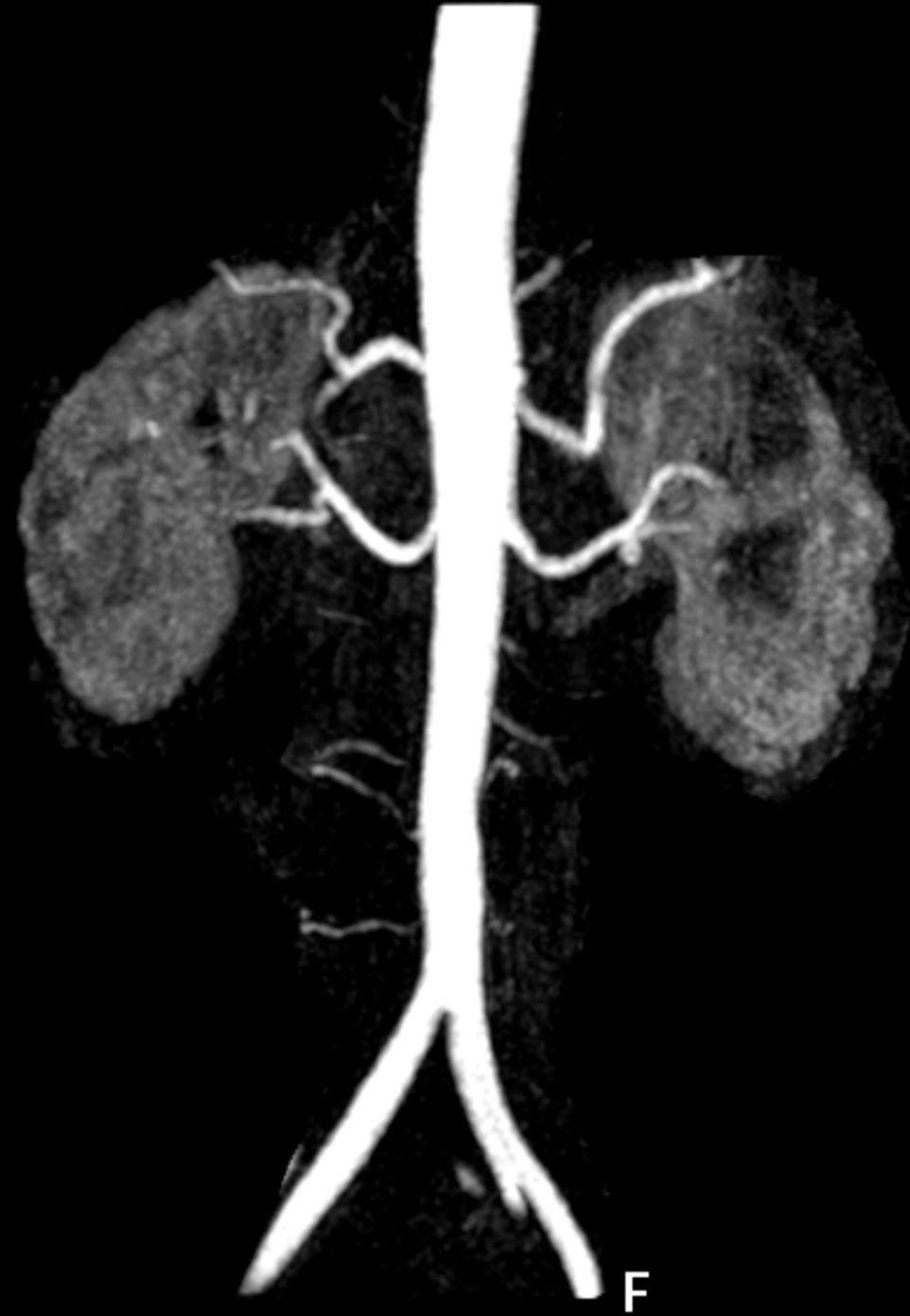SEM CONTRASTE

LOSSY



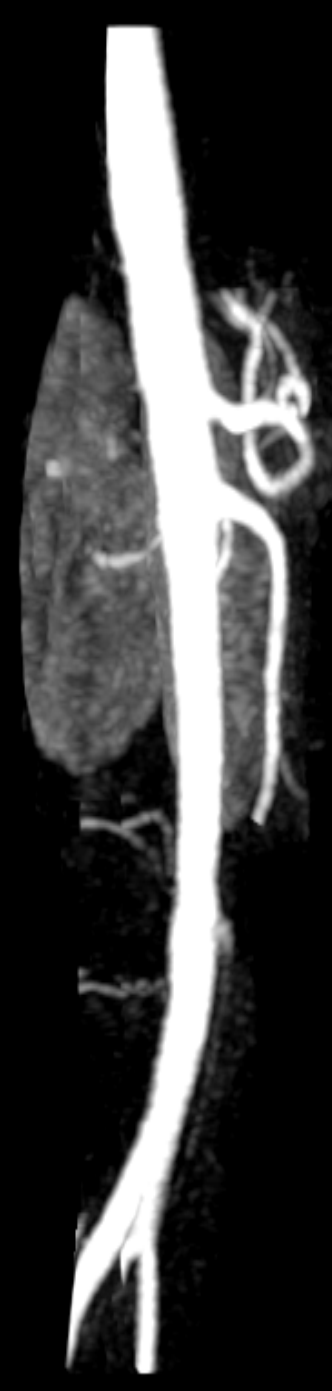





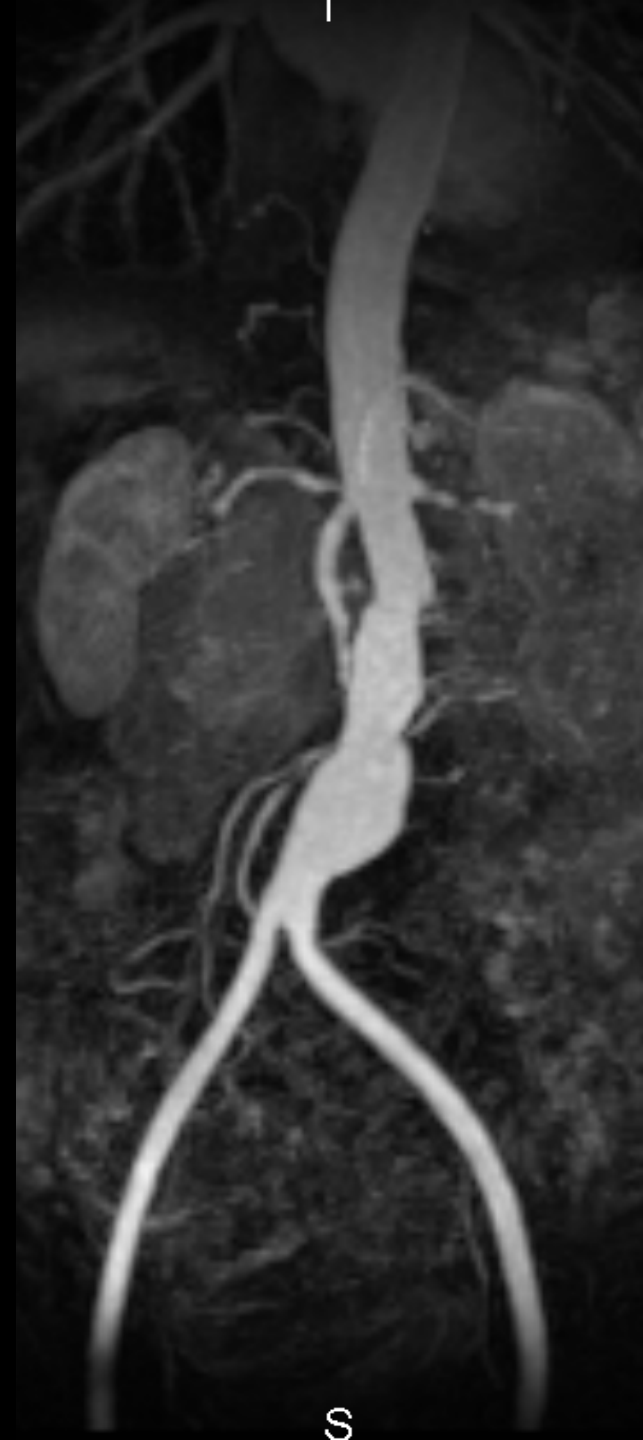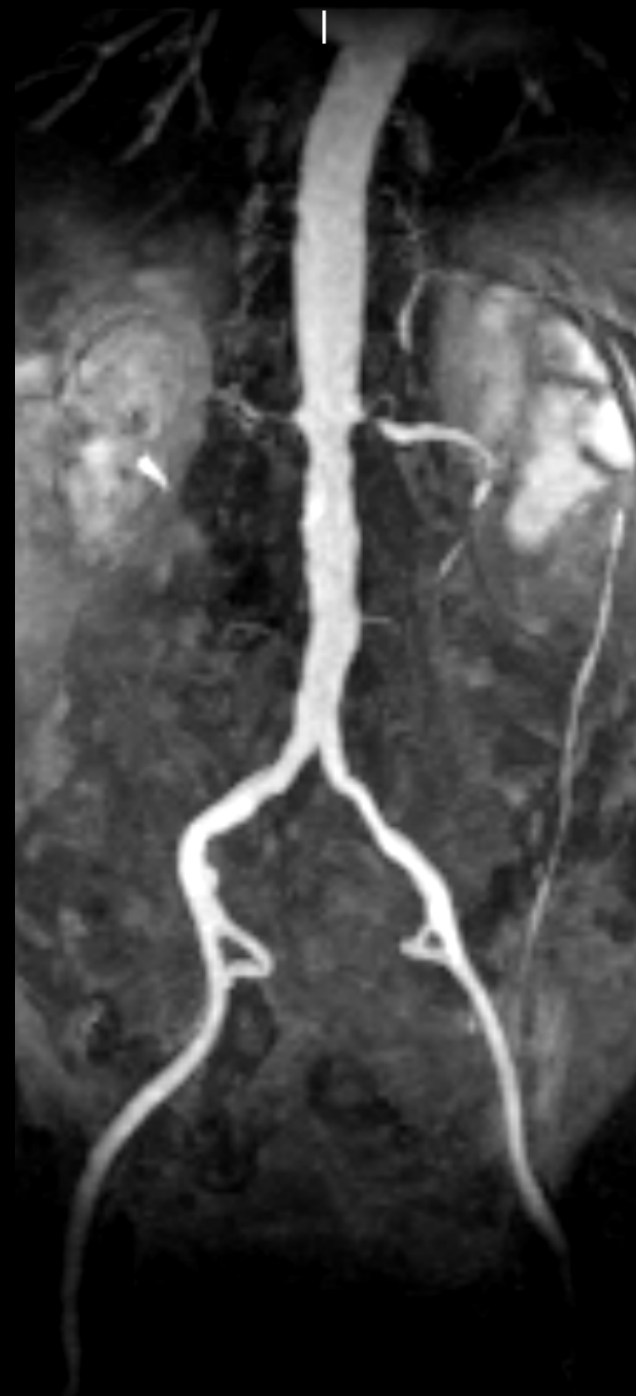
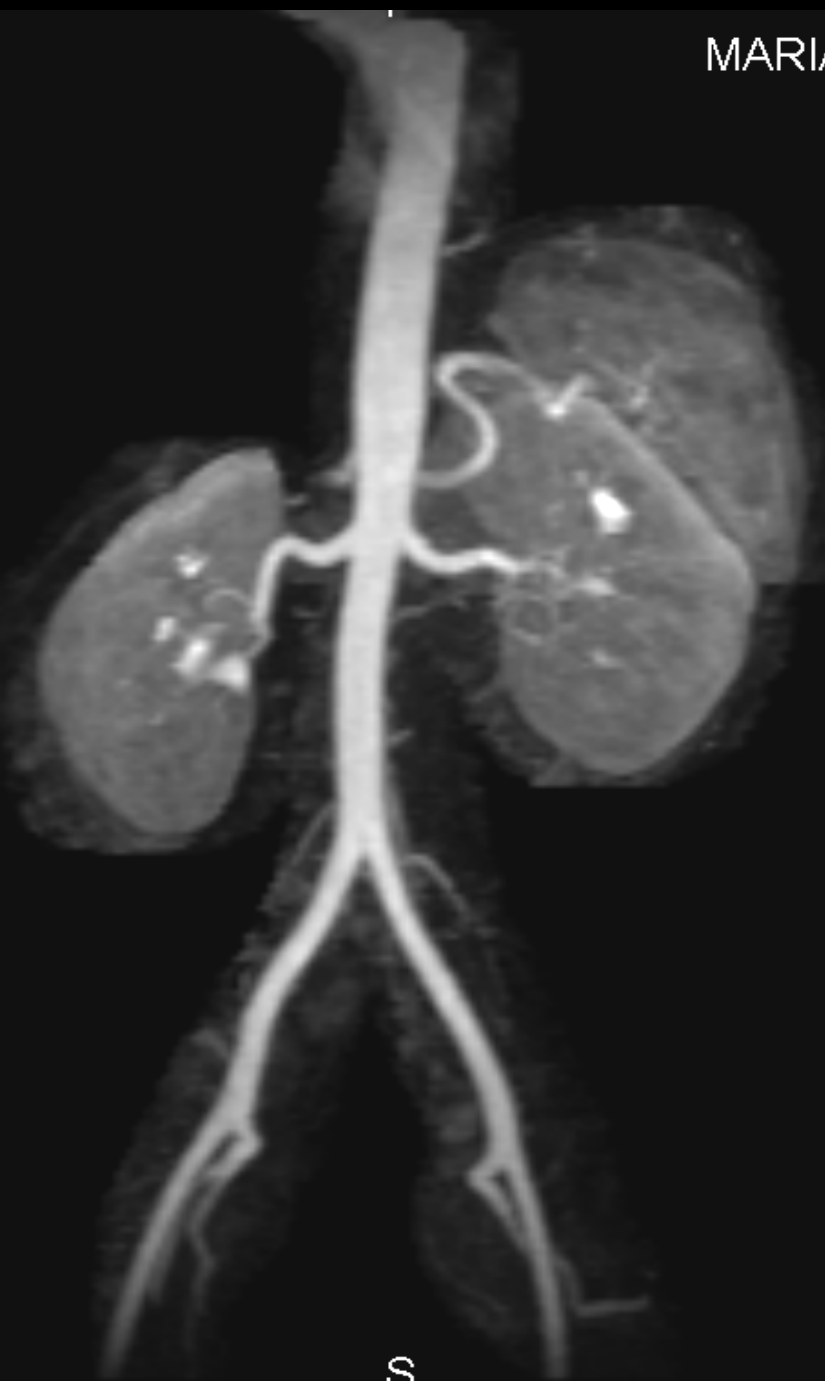
L

F

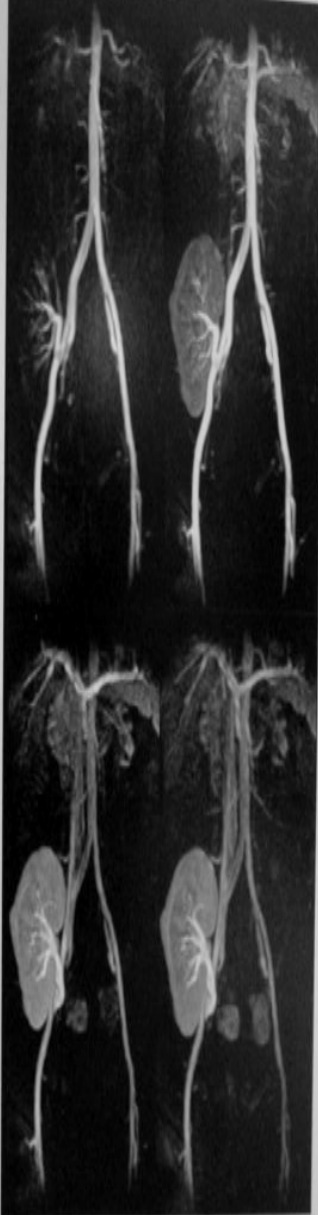


A

F



Transplante Renal



The image displays four MR angiography (MRA) scans of the renal vasculature, arranged in a 2x2 grid. The top two scans show the renal arteries originating from the aorta, while the bottom two scans show the renal veins originating from the inferior vena cava. The kidneys are visible as bright, bean-shaped structures. The text on the right side of the image provides information about the SyncraScan packaging and its applications.

The SyncraScan packaging. It uses signal from substantially shorten scan and increases spatial resolution combined with a large number of

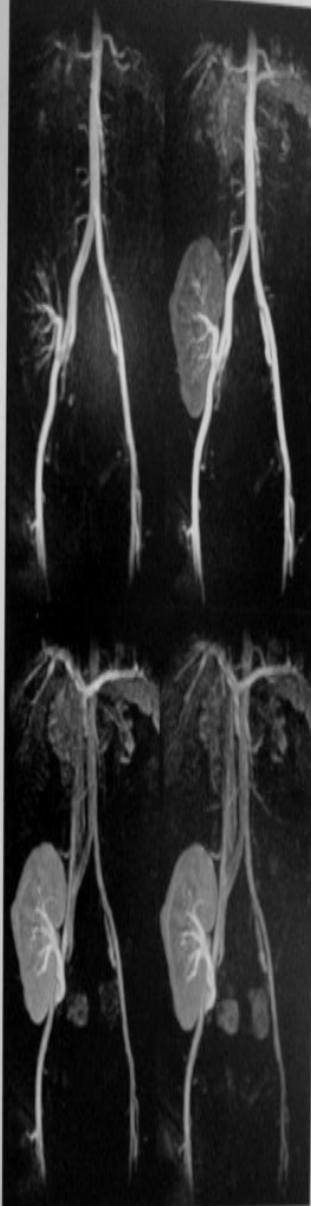
Applications

- Abdominal, thoracic, carotid and intracerebral MRA.
- High-resolution neuro imaging, diffusion and Brain perfusion.
- Breathhold, respiratory triggered free breathing abdominal imaging.
- Cardiac imaging, cardiac perfusion.

Features

- Scan time reduction up to 100%

Transplante Renal



The image displays four MR angiography (MRA) scans of the renal vasculature, arranged in a 2x2 grid. The top row shows two views of the renal arteries, and the bottom row shows two views of the renal veins. The vessels are highlighted in white against a dark background, demonstrating the high contrast and resolution of the imaging technique.

*The SyncraScan packa
ning. It uses signal from
stantially shorten scan
and increases spatial re
bined with a large num*

Applications

- Abdominal, thoracic, carotid and intracerebral MRA.
- High-resolution neuro imaging, diffusion and Brain perfusion.
- Breathhold, respiratory triggered, free breathing abdominal MRA.
- Cardiac imaging, cardiac perfusion.

Features

- Scan time reduction up to 50%.

Angio RM Aorta tóraco-abdominal e MMII

