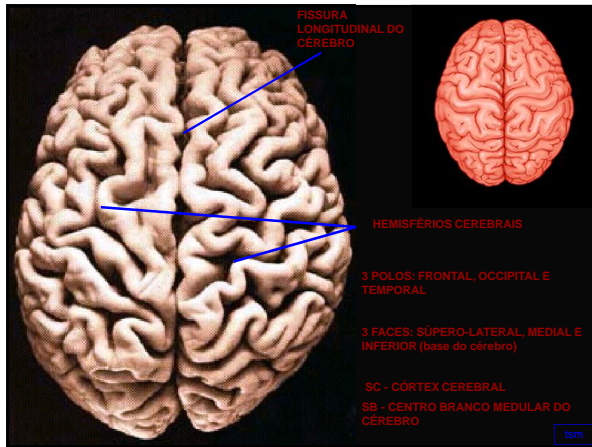
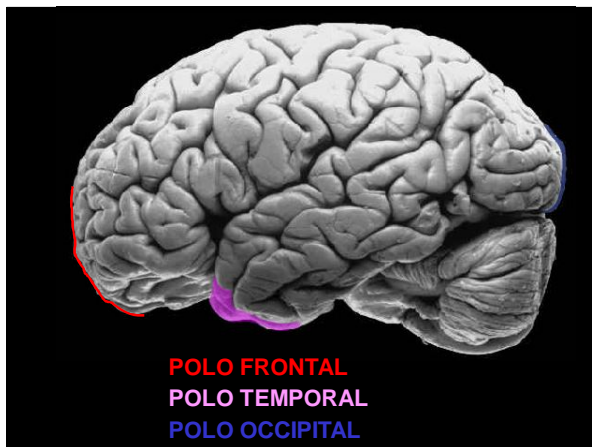


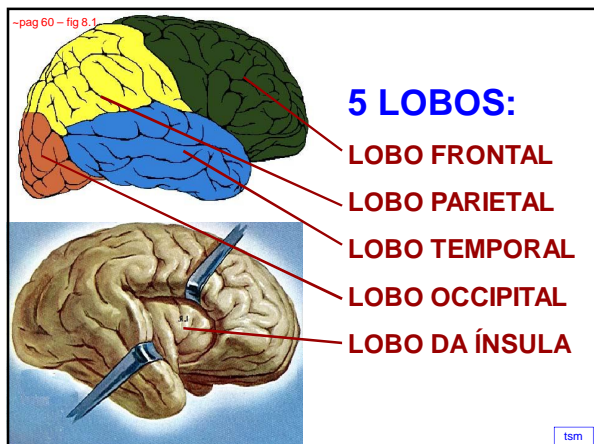
ANATOMIA MACROSCÓPICA DO TELENCEFALO

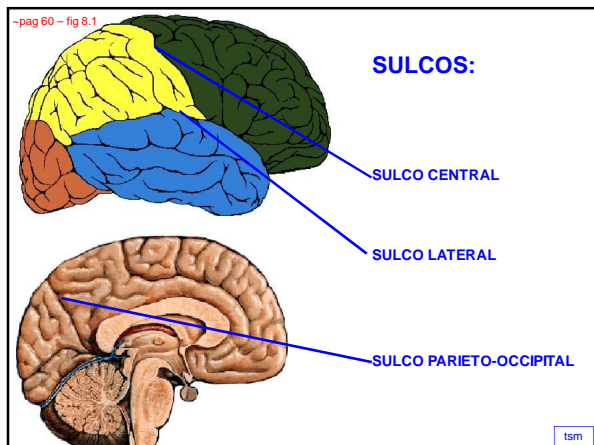
capítulo 8

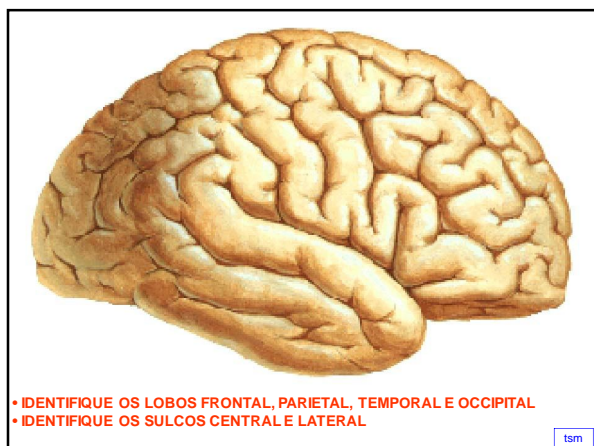
tsm

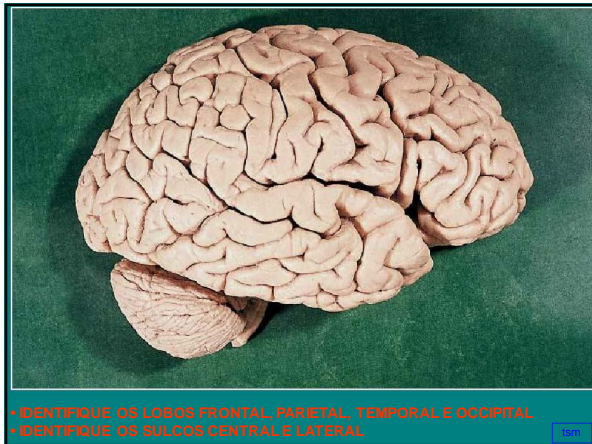


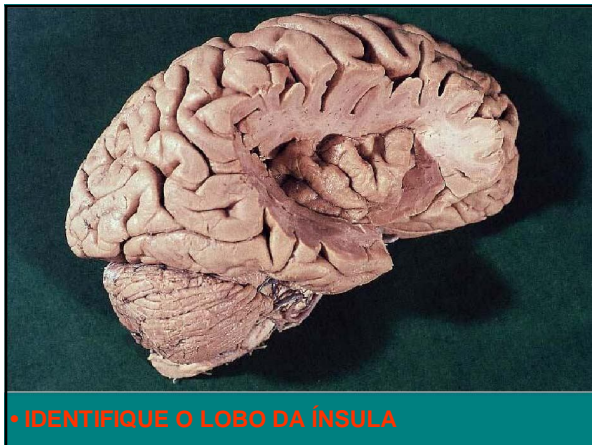


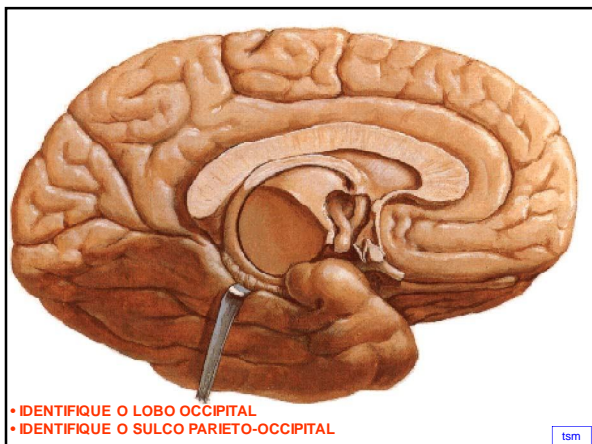






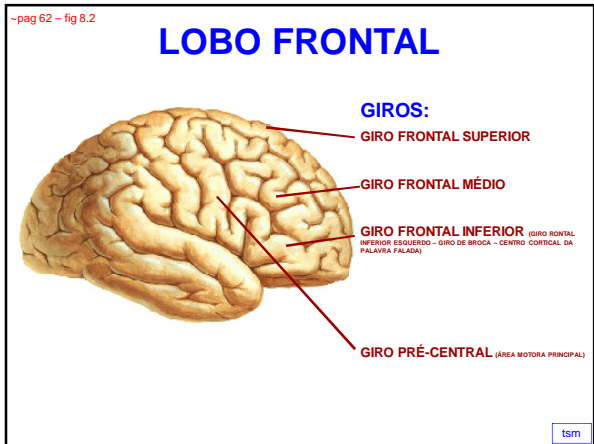


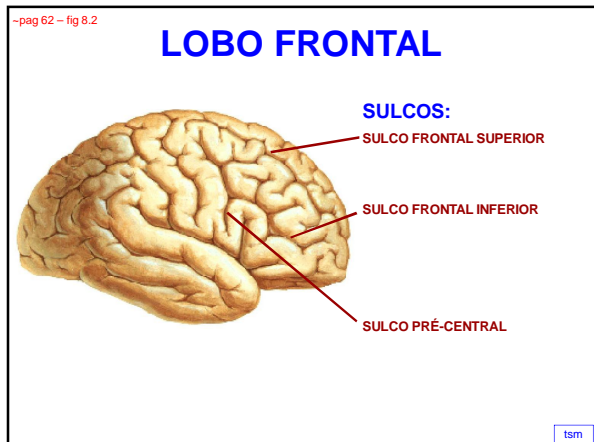


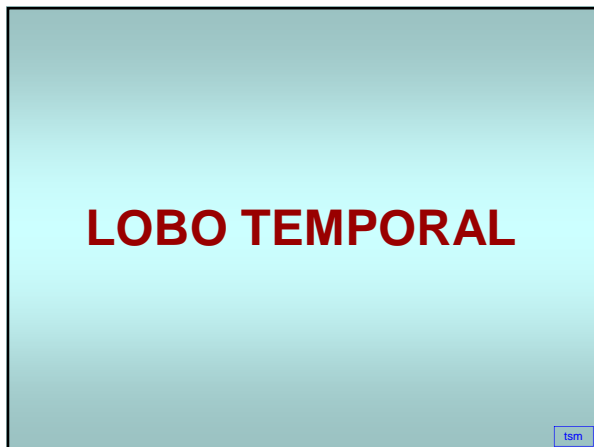

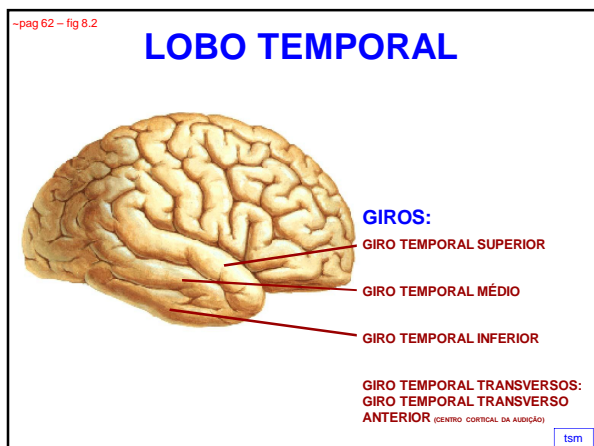
FACE SÚPERO-LATERAL DO TELENCEFALO

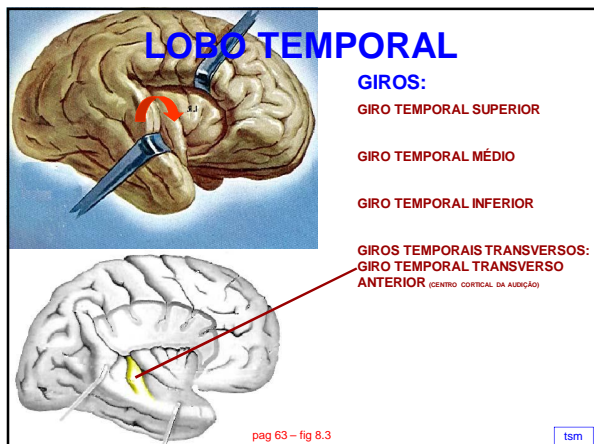
LOBO FRONTAL

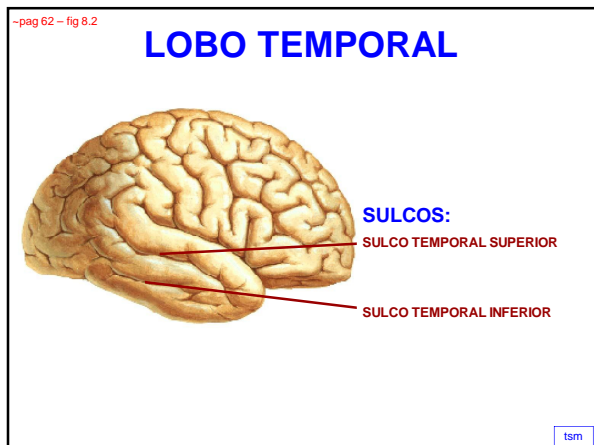


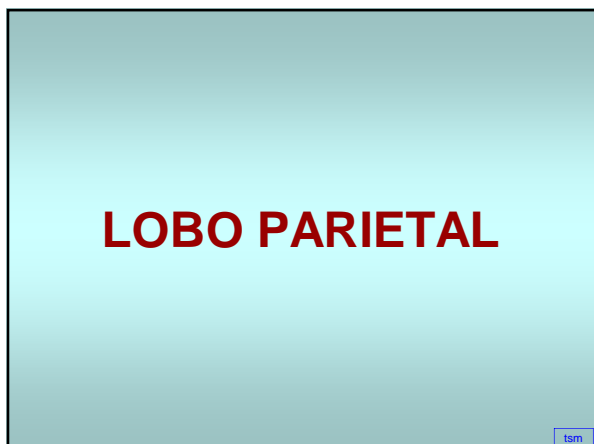

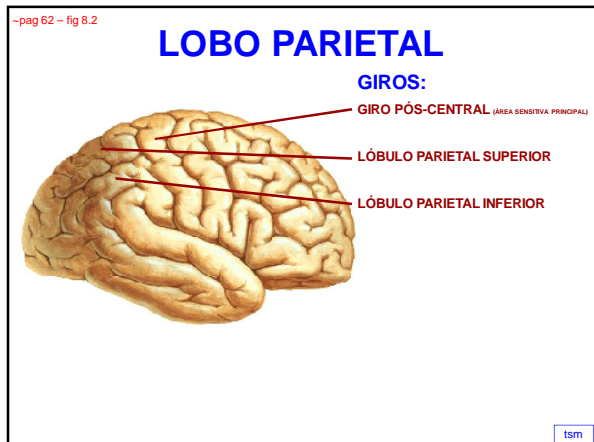


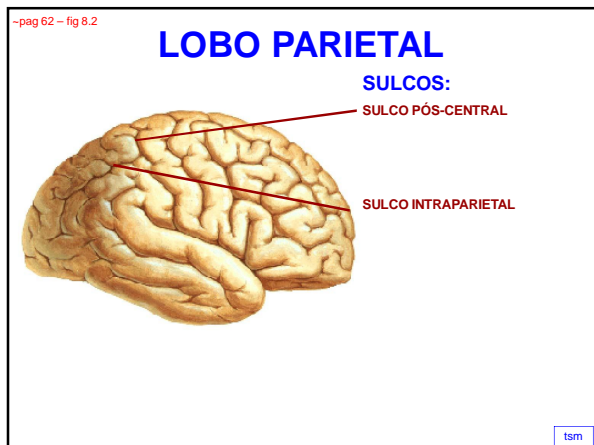



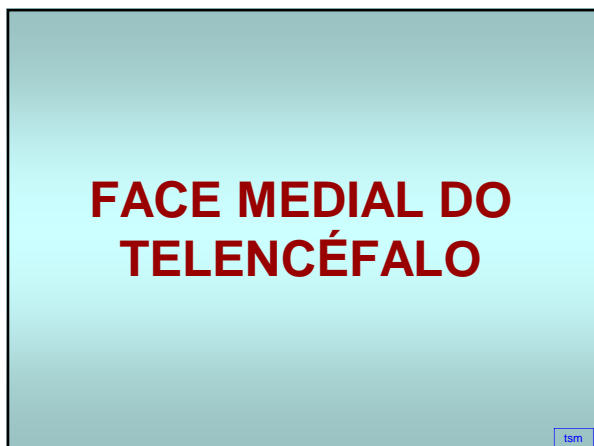


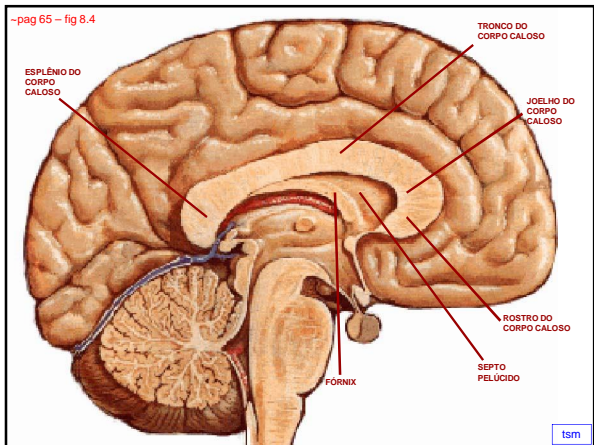




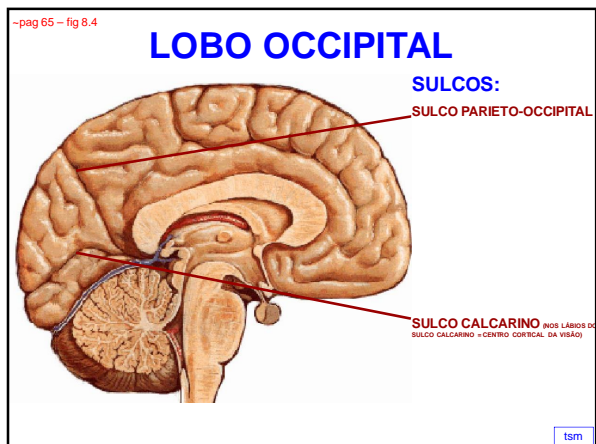


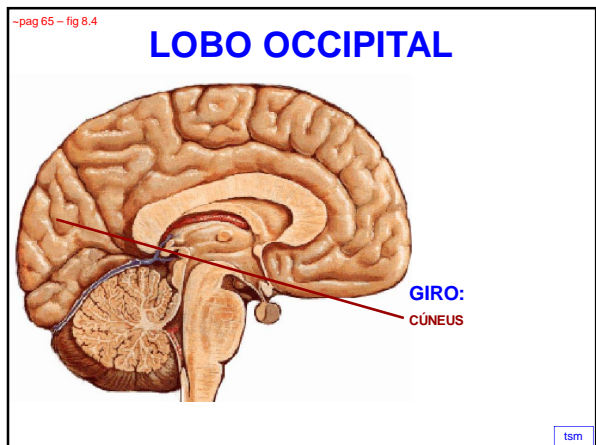


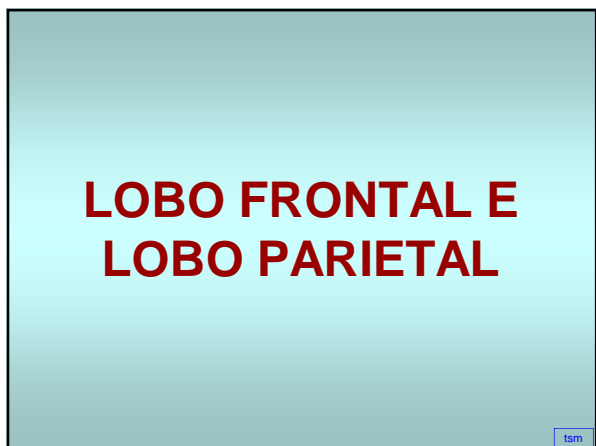
- **CORPO CALOSO**
 - **esplênio do corpo caloso**
 - **tronco do corpo caloso**
 - **joelho do corpo caloso**
 - **rosto do corpo caloso**
- **FÓRNIX**
- **SEPTO PELÚCIDO**

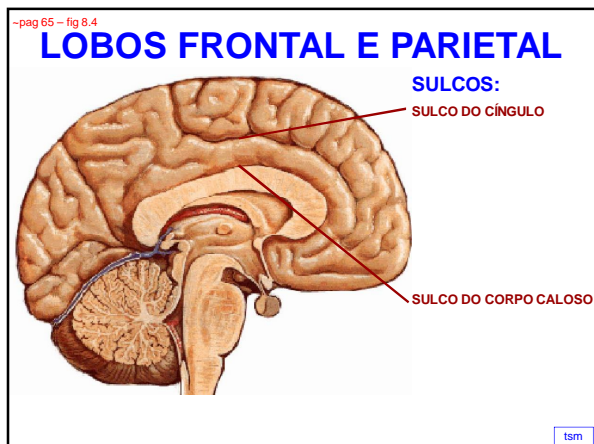


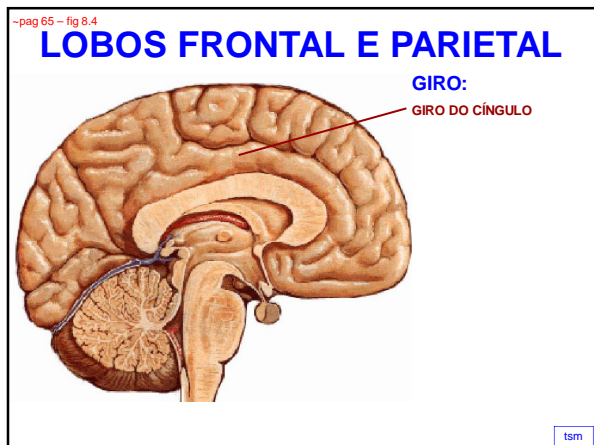
LOBO OCCIPITAL

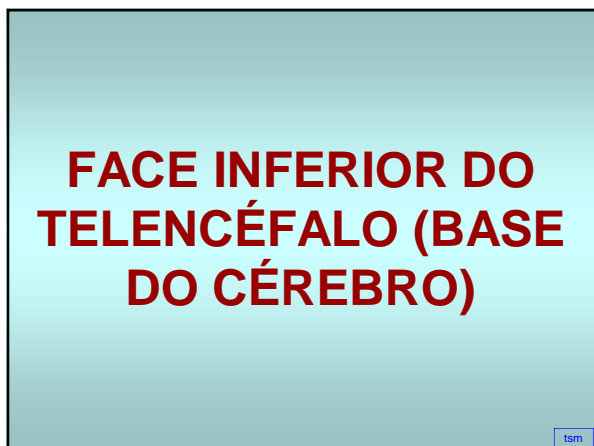


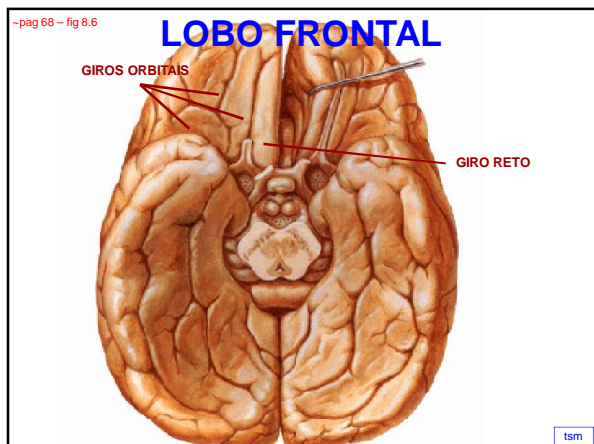


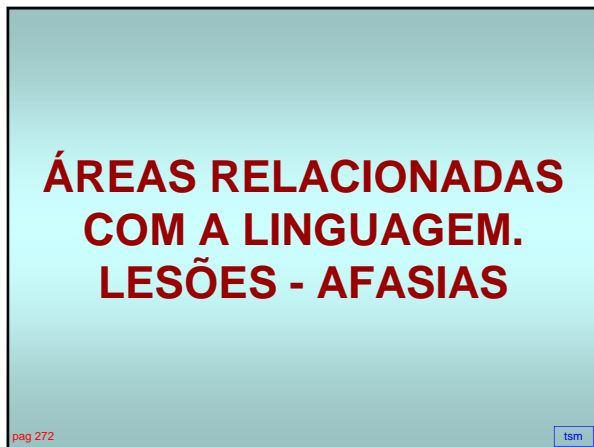


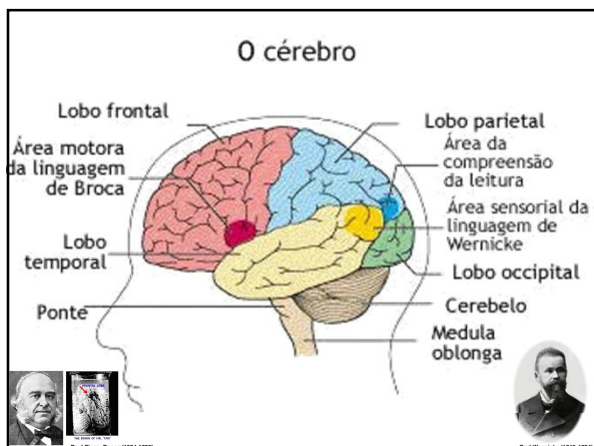


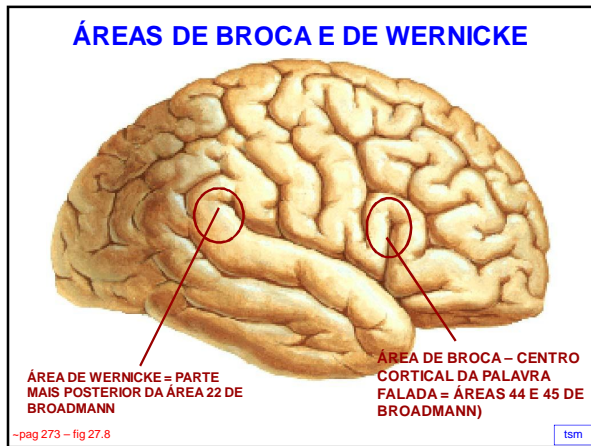


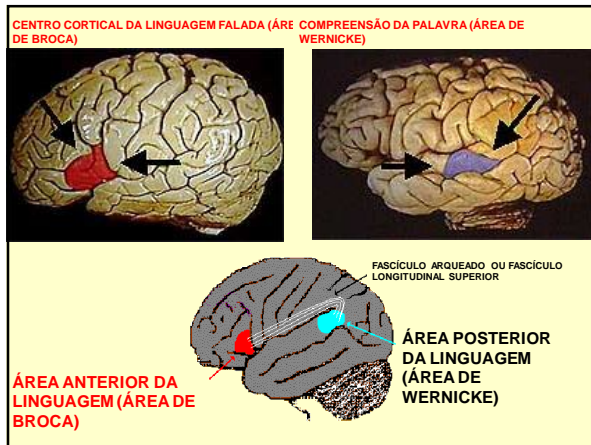


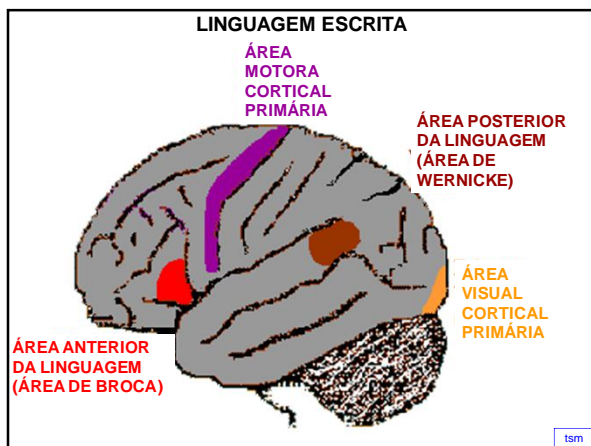


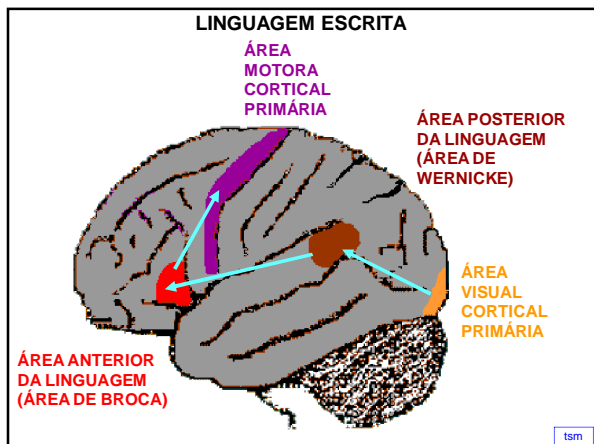


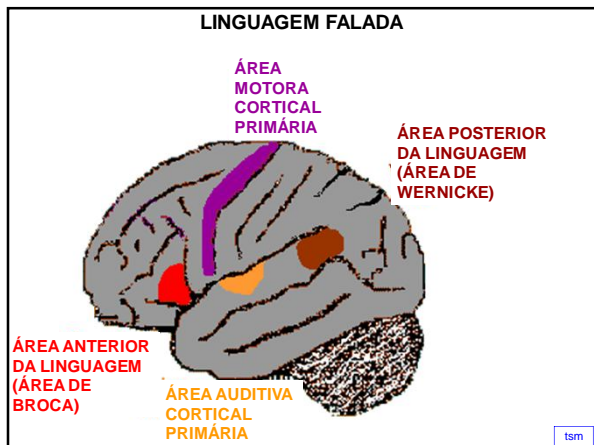


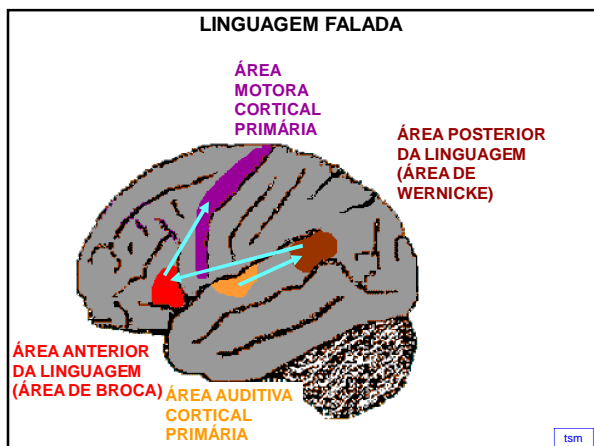


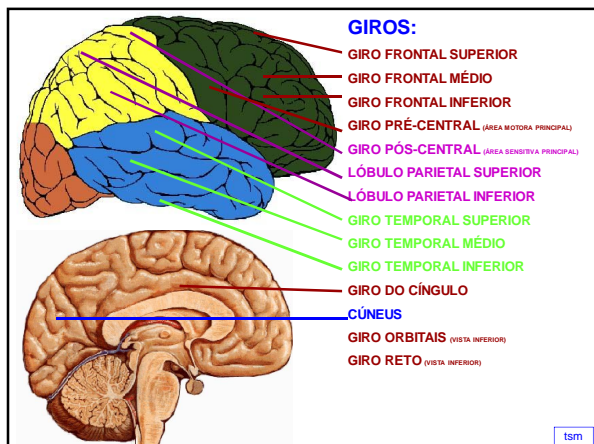


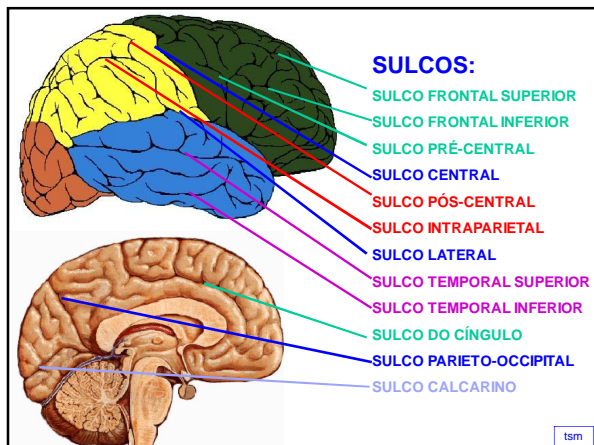


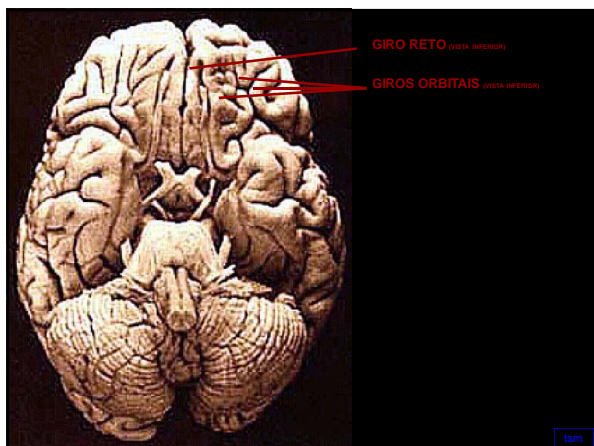


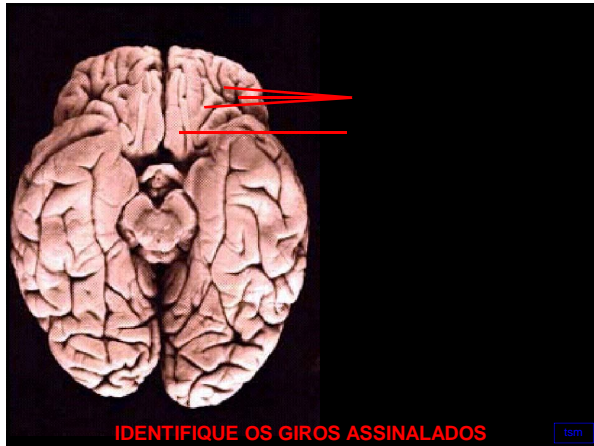


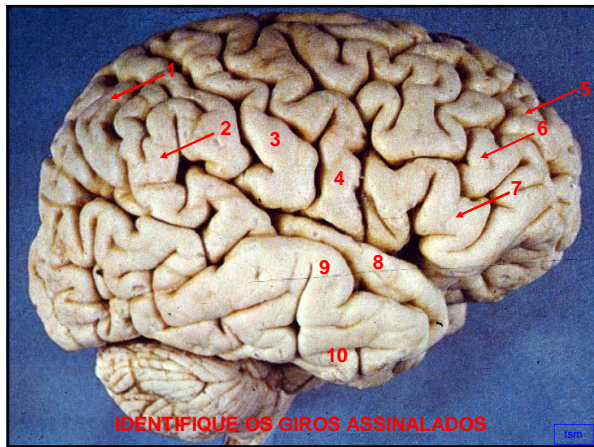


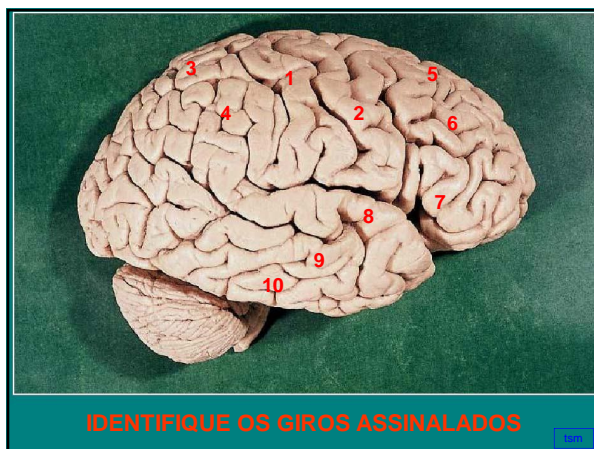


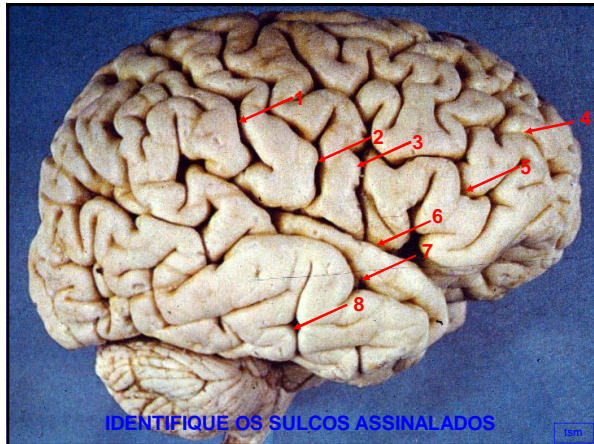


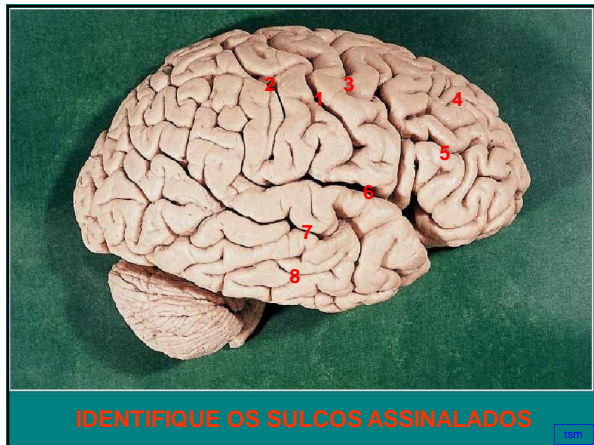


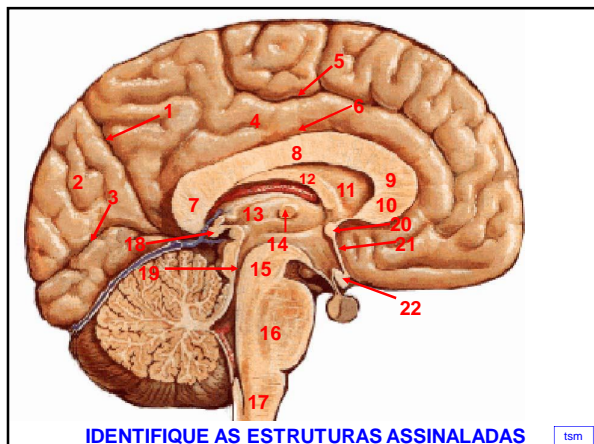


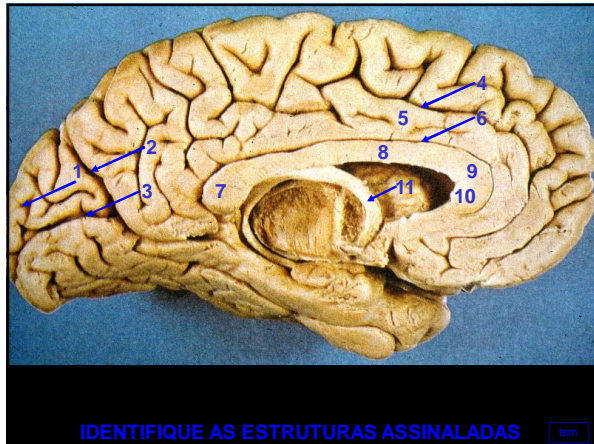


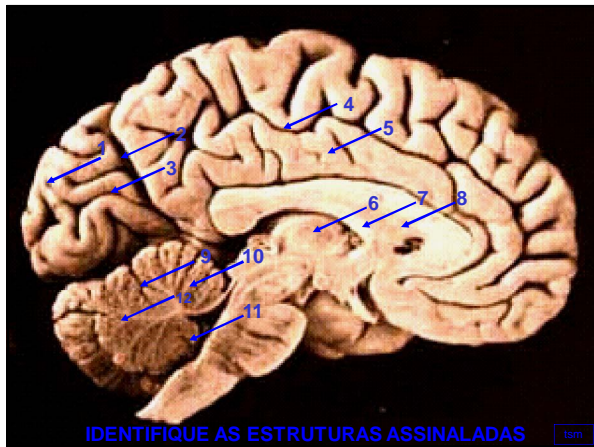


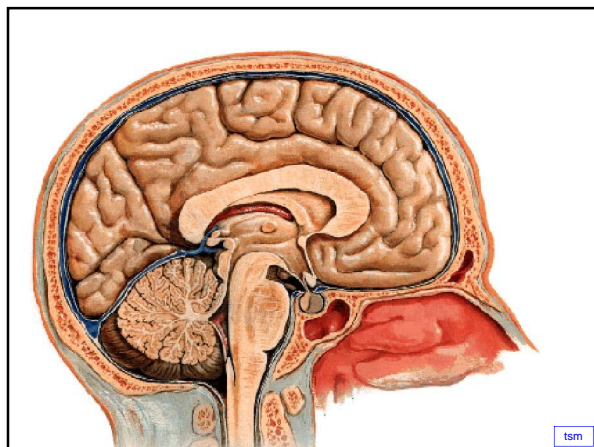


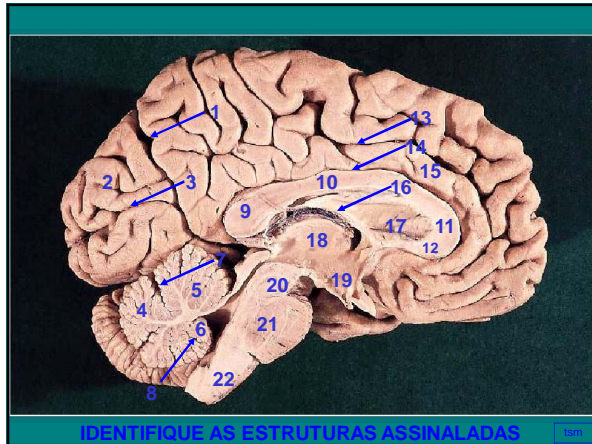






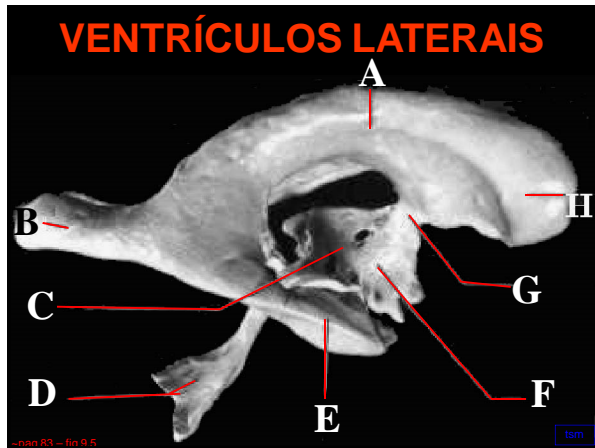


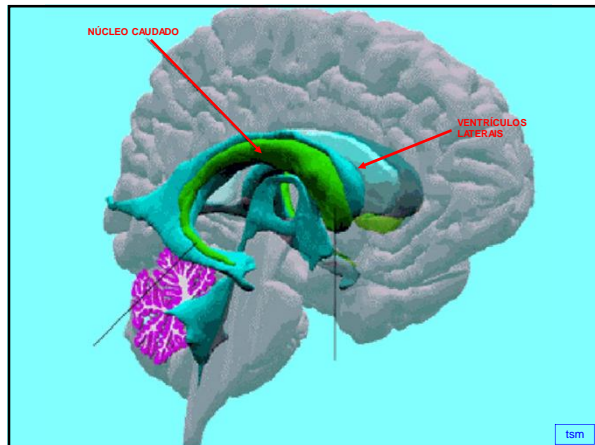


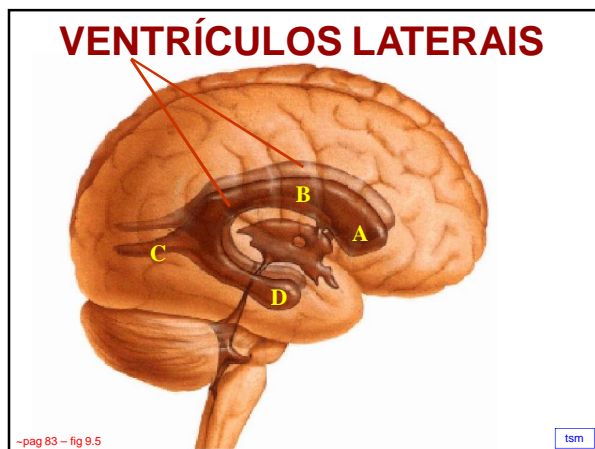


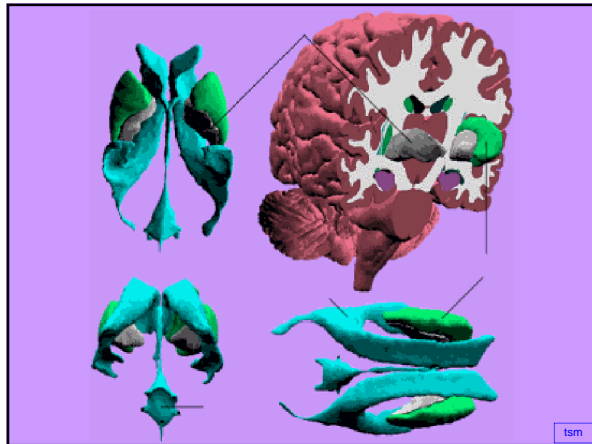
VENTRÍCULOS LATERAIS

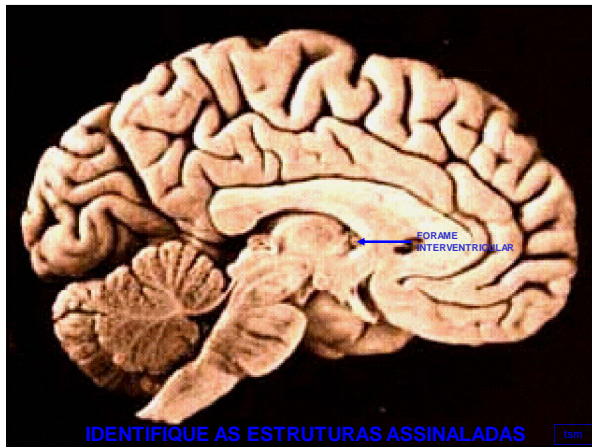
- **VENTRÍCULOS LATERAIS**
 - **parte central** (ASSOALHO – PLEXO CORIÓIDE)
 - **3 cornos** - **cornio anterior**
 - **cornio posterior**
 - **cornio inferior**

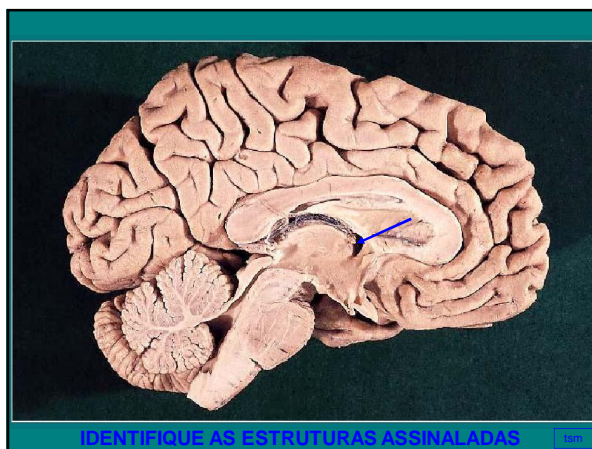








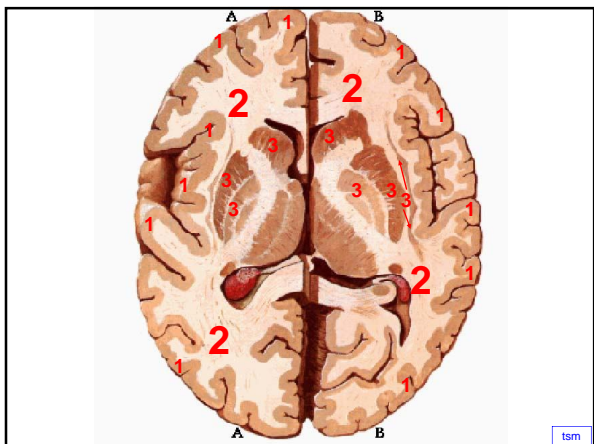




ORGANIZAÇÃO INTERNA DOS HEMISFÉRIOS CEREBRAIS

- **SUBSTÂNCIA CINZENTA (CÓRTEX CEREBRAL)**
 - **SUBSTÂNCIA BRANCA - centro branco medular do cérebro**
 - cápsula interna
 - cápsula externa
 - cápsula extrema
 - **NÚCLEOS DA BASE (substância cinzenta dentro do centro branco medular do cérebro):**
 - núcleo caudado
 - núcleo lentiforme (putâmen + globo pálido)
 - claustrum
 - corpo amigdalóide
 - núcleo accumbens
 - núcleo basal de Meynert
- obs: putâmen + núcleo caudado = estriado

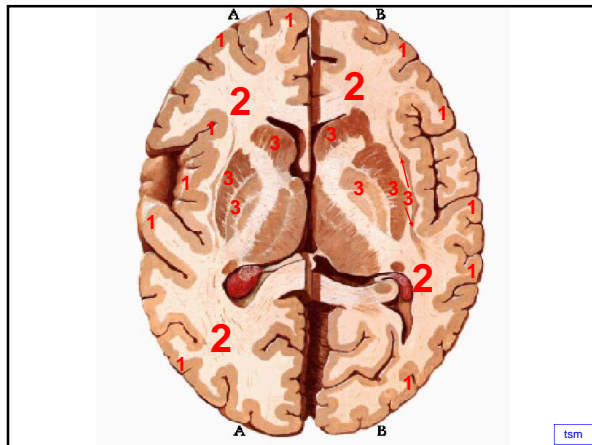




• **SUBSTÂNCIA CINZENTA (CÓRTEX CEREBRAL)**



tsm



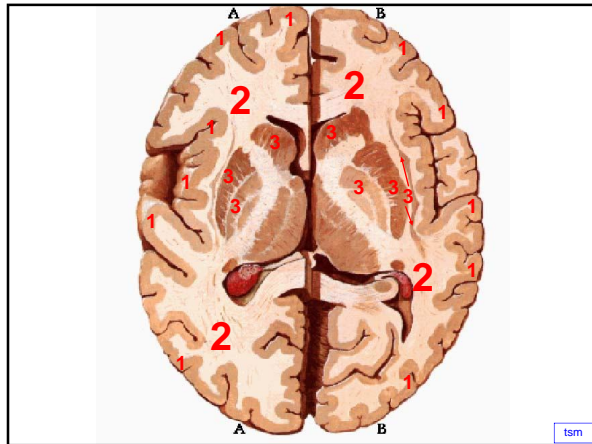
tsm

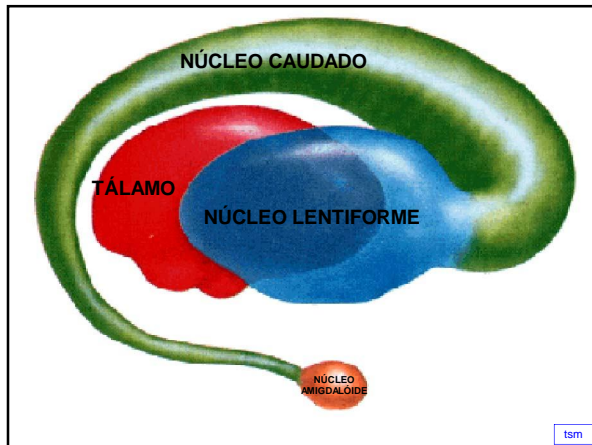
• **NÚCLEOS DA BASE (substância cinzenta dentro do centro branco medular do cérebro):**

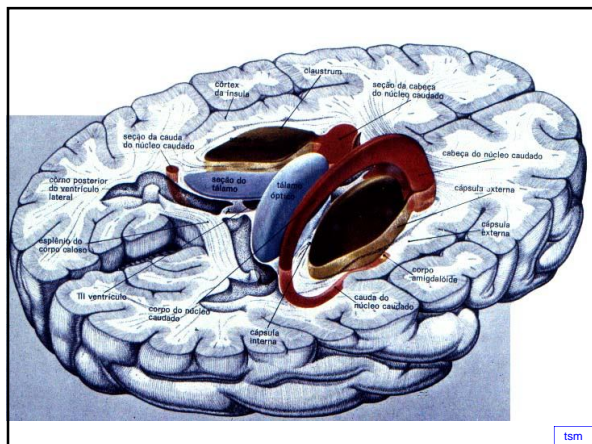
- núcleo caudado
 - núcleo lentiforme (putâmen + globo pálido)
 - claustrum
 - corpo amigdalóide
 - núcleo accumbens
 - núcleo basal de Meynert
- obs: putâmen + núcleo caudado = estriado

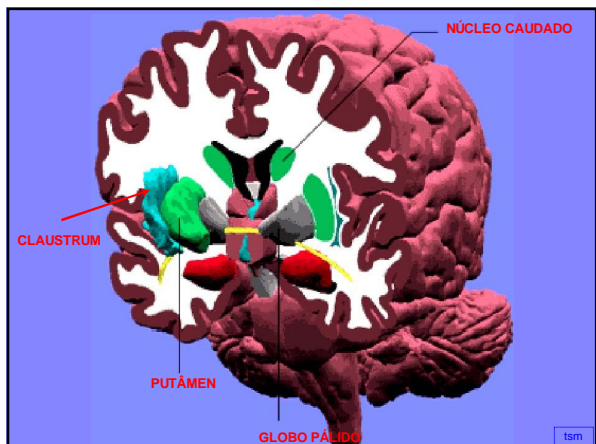


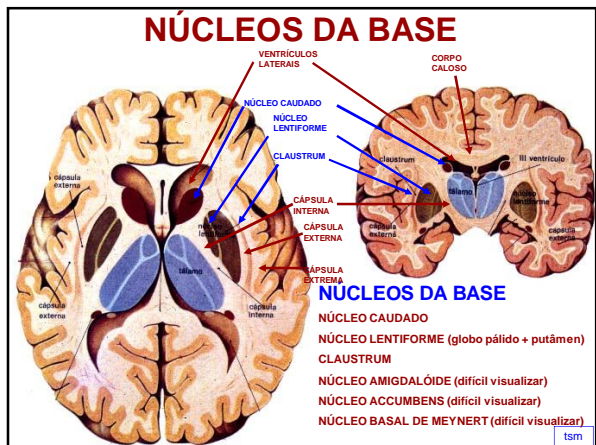
tsm








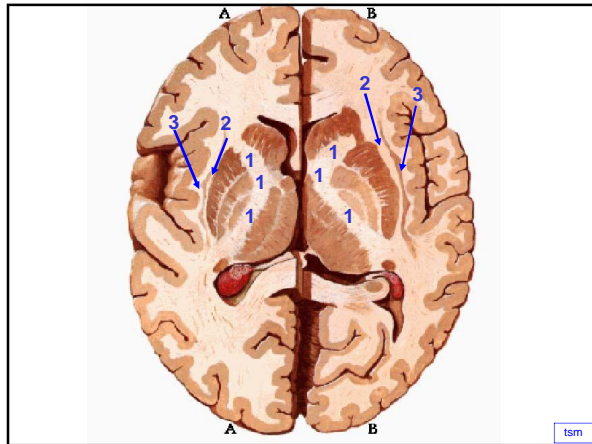


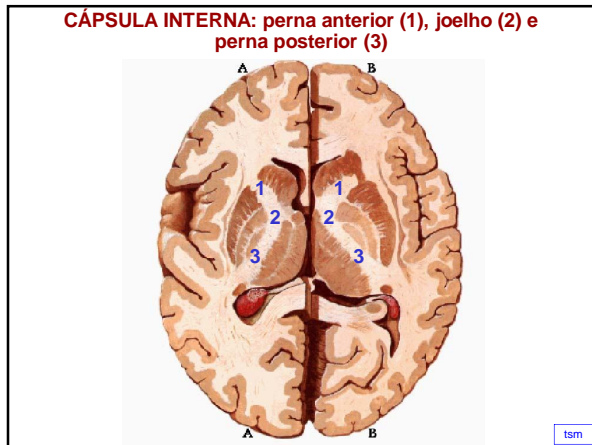


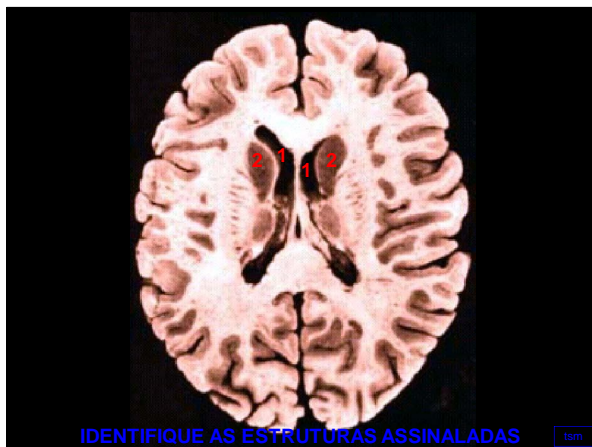
• **SUBSTÂNCIA BRANCA -**
centro branco medular do
cérebro

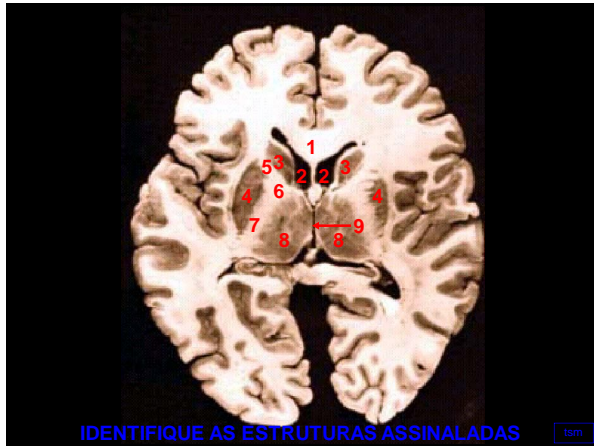
- cápsula interna
- cápsula externa
- cápsula extrema





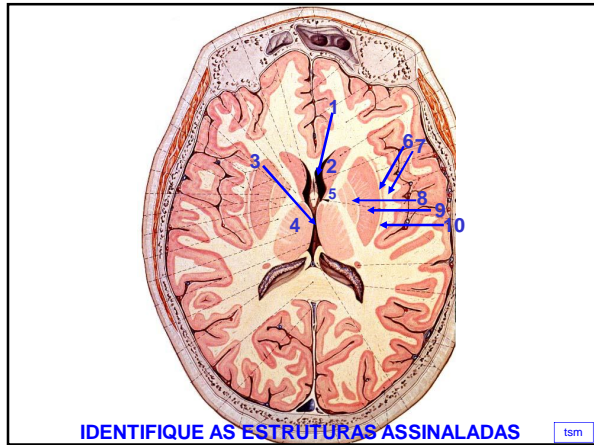






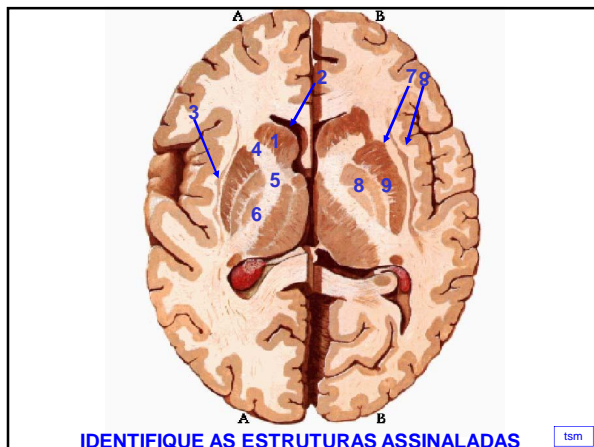
IDENTIFIQUE AS ESTRUTURAS ASSINALADAS

tsm



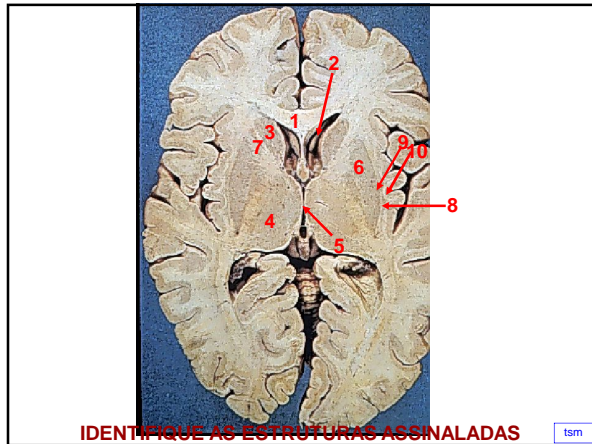
IDENTIFIQUE AS ESTRUTURAS ASSINALADAS

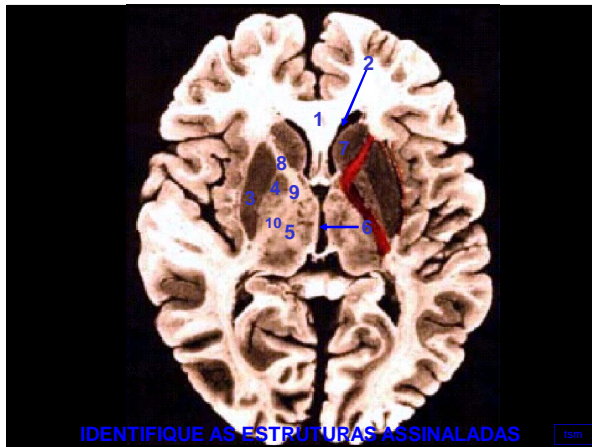
tsm

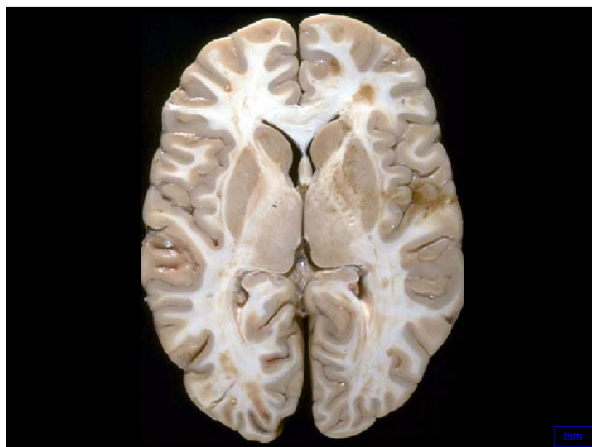


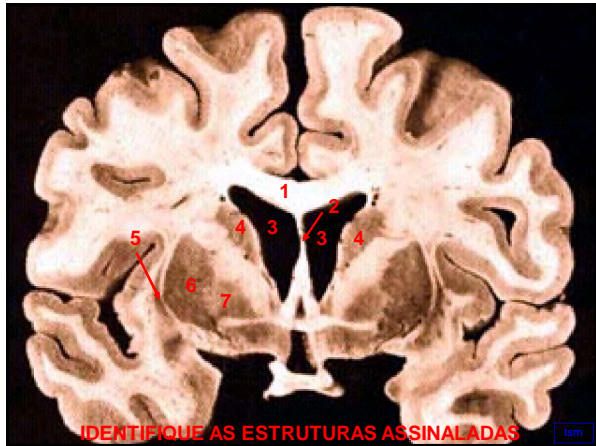
IDENTIFIQUE AS ESTRUTURAS ASSINALADAS

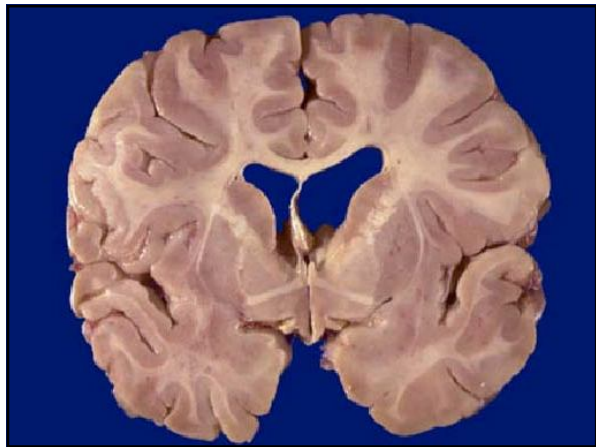
tsm

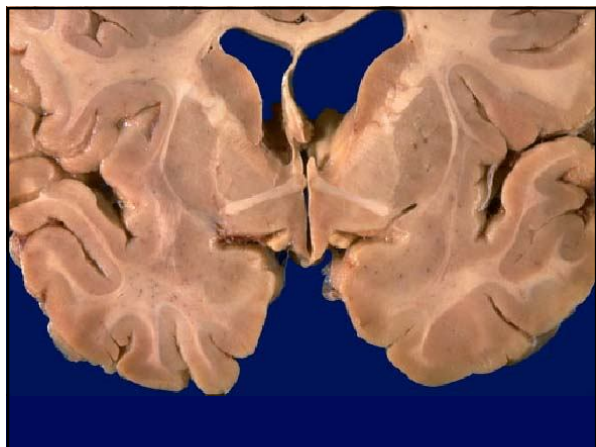


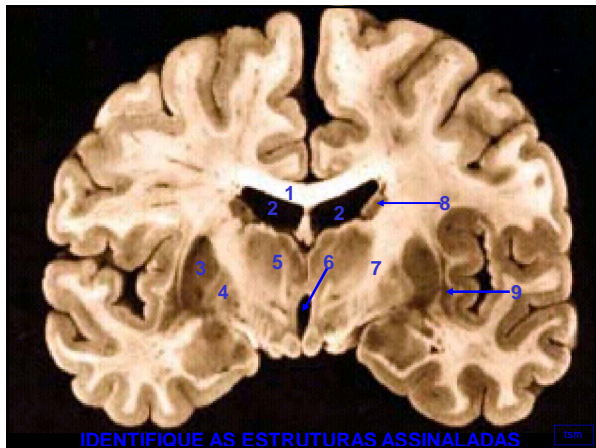




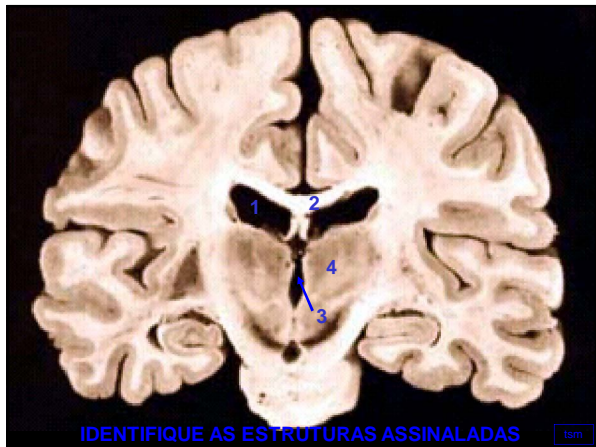








IDENTIFIQUE AS ESTRUTURAS ASSINALADAS



IDENTIFIQUE AS ESTRUTURAS ASSINALADAS

